

Case report

Neurological toxicity due to antimonial treatment for refractory visceral leishmaniasis



Marta Maristany Bosch ^a, Guillermo Cuervo ^{b,e,*}, Elisabeth Matas Martín ^{d,e}, Misericordia Veciana de las Heras ^c, Jordi Pedro Pérez ^c, Sergio Martínez Yélamos ^d, Nuria Sabé Fernández ^b

^a Department of Internal Medicine, Hospital Universitari de Bellvitge, Barcelona, Spain

^b Department of Infectious Diseases, Hospital Universitari de Bellvitge, Barcelona, Spain

^c Department of Neurophysiology, Hospital Universitari de Bellvitge, Barcelona, Spain

^d Department of Neurology, Hospital Universitari de Bellvitge, Barcelona, Spain

^e Institut d'Investigació Biomèdica de Bellvitge (IDIBELL), Barcelona, Spain

ARTICLE INFO

Article history:

Received 2 December 2020

Received in revised form 26 February 2021

Accepted 28 March 2021

Available online 25 April 2021

Keywords:

Antimonials

Neurotoxicity

Sodium stibogluconate

Meglumine antimoniate

Myoclonus

Beta activity

ABSTRACT

Introduction: Although pentavalent antimonials are no longer considered the first-line therapy for visceral leishmaniasis in the developed world, they are still used in certain geographical areas and in refractory cases. These drugs have a great number of adverse effects; however, neurological toxicity has been rarely reported.

Case report: We present a 56-year-old woman who required long-term treatment with antimonial drugs due to refractory visceral leishmaniasis and presented clinically with tremor of extremities, myoclonus, gait disturbances and epileptic seizures. The EEG showed increased beta rhythms and generalized epileptogenic activity. She had a slow but favorable response after the withdrawal of antimonials and the initiation of anticonvulsant therapy.

Conclusion: Severe but reversible neurological toxicity is a rare adverse effect of prolonged antimonial treatment. More EEG record data are needed to support the suspicion of a possible increase of beta rhythms in this situation.

© 2021 International Federation of Clinical Neurophysiology. Published by Elsevier B.V. This is an open access article under the CC BY-NC-ND license (<http://creativecommons.org/licenses/by-nc-nd/4.0/>).

1. Case report

We report the case of a 56-year-old woman diagnosed with visceral leishmaniasis for which she had received two amphotericin-B cycles. Due to persisting symptomatology and positive *Leishmania* spp. PCR in bone marrow aspirate, the disease was categorized as refractory and thus meglumine antimoniate associated with itraconazol and miltefosine for 15 days was indicated. She then received sodium stibogluconate for additional 14 days. It was decided to continue secondary prophylaxis with meglumine antimoniate. During this period she began to feel fine self-limiting distal hands tremor after receiving the medication.

New positive blood PCR for *Leishmania* was detected during prophylaxis. She then received successive regimens of liposomal amphotericin B, miltefosine, adjuvant Interferon gamma, paromomycin and two extra cycles of stibogluconate (total cumulative

dose of 69000 mg). Along this time course, the tremor progressed hindering basic activities and limiting gait, and a generalized tonic-clonic seizure during a febrile episode occurred. Neurological exam showed distal intention tremor of extremities and tongue, polytopic myoclonus and exalted osteoarticular reflexes. A brain RMN showed non-specific meningeal FLAIR hyperintensity (Fig. 1A-B). Cerebrospinal fluid was normal. An electroencephalogram (EEG) displayed increased in beta rhythms and generalized epileptogenic activity (Fig. 2A). Antimonite urine levels were 12305.3 mcg/g Cr (upper limit: 35).

Due to suspected neurological toxicity, stibogluconate was stopped. Valproate was initiated with slow improvement of symptomatology. A control EEG two weeks later showed persistence of beta alternating with physiological Alpha rhythms but no epileptogenic activity (Fig. 2B). One year later under valproate treatment she only presented minimal intention tremor. Control EEG and RMN were normal (Fig. 2C and Fig. 1C-D, respectively). Blood PCR was still negative for *Leishmania*.

Visceral leishmaniasis has long been treated with pentavalent antimonial monotherapy. Due to appearance of resistance and side effects, these drugs were replaced for other such as amphotericin B,

* Corresponding author at: Department of Infectious Diseases, Bellvitge University Hospital, Feixa llarga s/n 08907, L'Hospitalet de Llobregat, Barcelona, Spain.

E-mail address: guillermo.cuervo@bellvitgehospital.cat (G. Cuervo).

¹ ORCID 0000-0002-7075-943X.

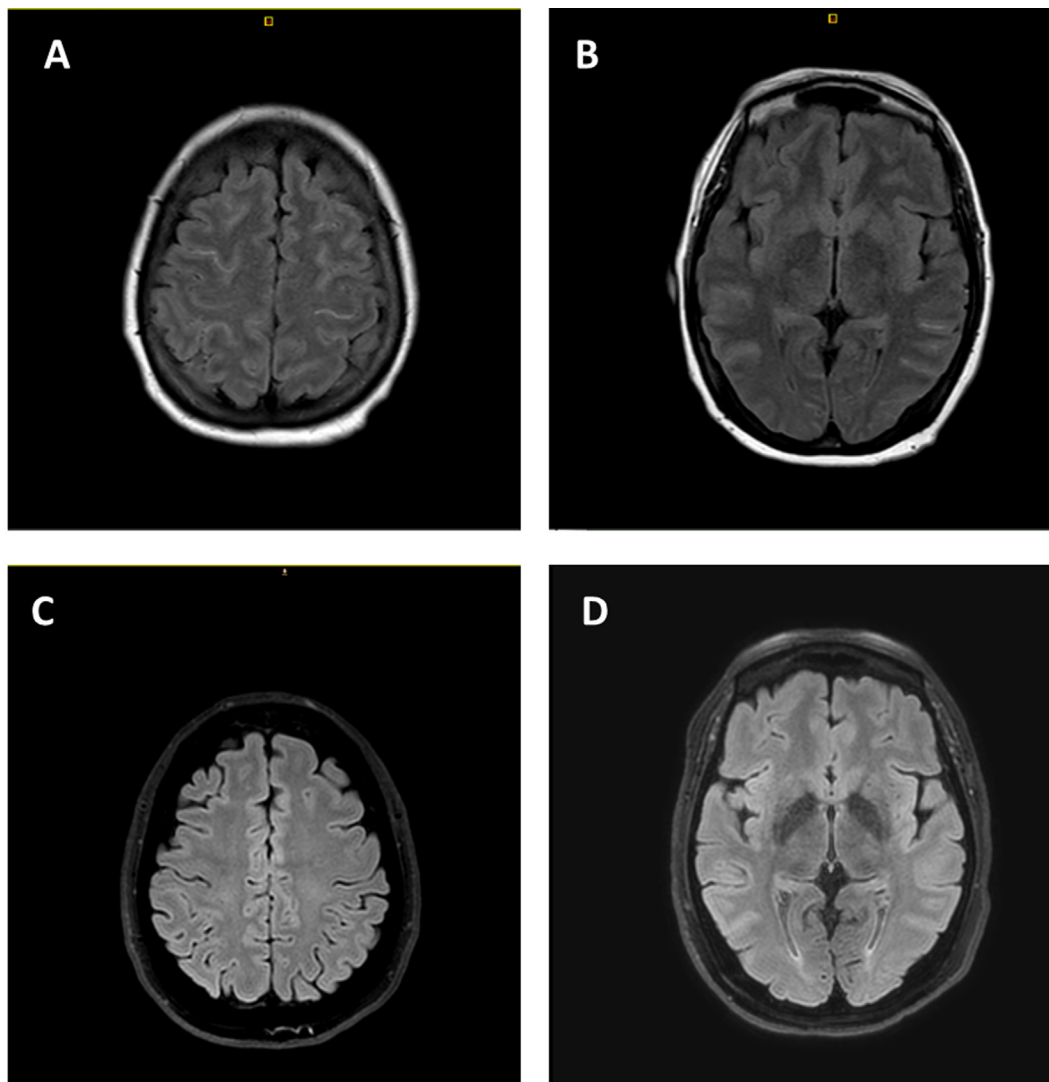


Fig. 1. A-B. MRI during the acute phase of the intoxication, showing non-specific meningeal FLAIR hyperintensity. C-D. Normal control MRI one year later.

paramomycin and miltefosine. Currently, their indication as first line therapy remains for visceral leishmaniasis in east Africa [Burza et al., 2018].

Adverse effects due to antimonials typically include arthromyalgia, abdominal pain and elevation of hepatocellular enzymes. Severe side effects consist in acute pancreatitis and cardiotoxicity, especially in immunosuppressed patients. Neurological manifestations due to antimonials have been rarely described, accounting for only two case reports in the literature. The first one describes two patients from Sudan. One of them developed acute generalized intention tremors, unstable gait and exaggerated reflexes under stibogluconate treatment (20 mg/kg/day for 20 days). The EEG showed generalized epileptiform spikes. The patient experienced a quick improvement four weeks after drug withdrawal. The second patient received sodium stibogluconate (no dose specified) and developed limbs and head myoclonus, dysmetria and wide-based gait. The EEG showed epileptogenic generalized spikes. The symptomatology improved when stibogluconate was retired [Khalil et al., 2006].

The second article describes a refractory visceral leishmaniasis treated with high cumulative doses of stibogluconate and meglumine antimoniate during a 4-years period. He presented distal tremor and oral dyskinesias among other extrapyramidal

symptoms. The RMN showed no significant findings. Neither EEG nor urinary levels were performed [Laguna del Estal et al., 1994].

We found similar clinical manifestations to those described, however, there is not a specific neurological syndrome neither a clear pattern in terms of dose or time of exposure required. In our case as well as in the second article, long term antimonial treatment and longer recovery period were observed in comparison to the cases from Sudan. An important limitation of those reports is the variability of diagnostic tests used, making difficult comparisons.

The generalized spike and wave EEG activity we found in the acute neurotoxicity phase was in agreement with that described in Sudanese patients. Interestingly, increased beta activity lasting weeks arises the suspicion of it being related with antimonial urine levels. This activity is usually found in patients treated with benzodiazepines, barbiturates or other drugs and also in some epileptic syndromes and encephalitis [Jaffe and Jacobs, 1972; Veciana et al., 2015]. In our case no other drugs were found to whom this finding could be attributed and, moreover, in the first EEG without antiepileptic treatment this increased beta activity was present, and one year later, in the follow-up EEG under valproate treatment this increased beta activity was not observed.

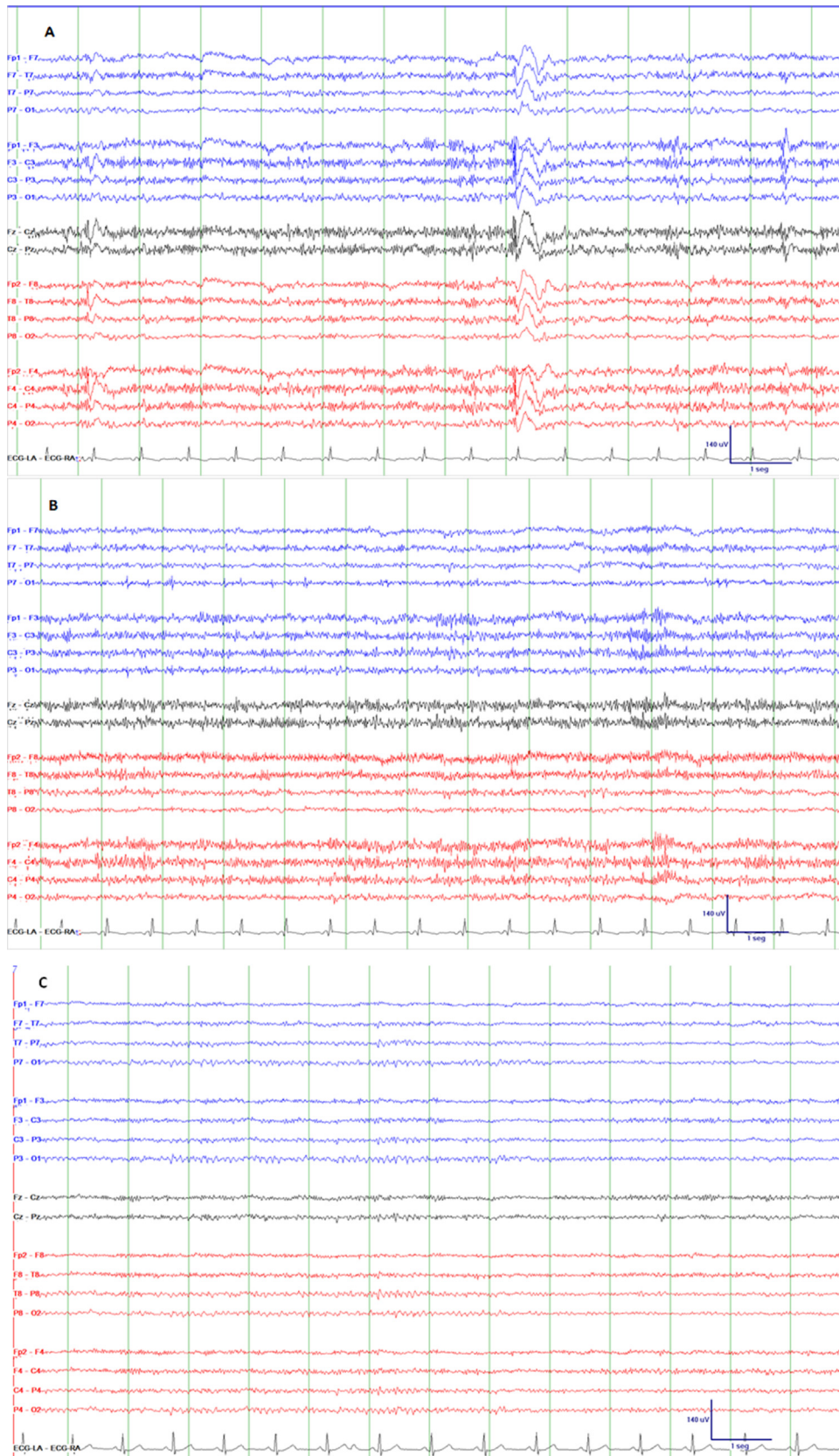


Fig. 2. A. EEG showing excessive beta activity and generalized spike and wave discharges, sometimes with left-sided parasagittal predominance, and others with right-sided parasagittal predominance. This EEG was recorded before antiepileptic treatment was started. B. EEG 4 days after initiating valproate showing excessive beta activity and no spike and wave discharges. C. Normal EEG one year later, under treatment with valproate, showing no beta activity. High pass filter 0.5 Hz, low pass filter 70 Hz.

In conclusion, reversible neurological toxicity due to antimonial treatment is a rarely described adverse effect, but it should be taken into account by clinicians prescribing these drugs. Moreover, EEG record data in patients with toxic antimonial levels are needed to support the suspicion of a possible increase of beta rhythms in this situation.

Funding

No specific funding was obtained for this report.

We thank the CERCA Programme/Generalitat de Catalunya for institutional support.

Author contributions

All authors have significantly contributed to this manuscript and approved the final draft.

Declaration of Competing Interest

The authors declare that they have no known competing financial interests or personal relationships that could have appeared to influence the work reported in this paper.

References

- Khalil, E.A.G., Ahmed, A.E., Musa, A.M., Hussein, M.H., 2006. Antimony-induced cerebellar ataxia. *Saudi Med. J.* 27, 90–92.
- Jaffe, R., Jacobs, L., The beta focus: its nature and significance. *Acta Neurol. Scand.* 1972; 48:191-203.
- Laguna del Estal, P., Calabrese, S., Zabala, J.A., Martín, T., 1994. Neurological toxicity from pentavalent antimonials during the treatment of visceral leishmaniasis. [Article in Spanish]. *Med Clin (Barc)* 102, 276–277.
- Burza, S., Croft, S.L., Boelaert M. Leishmaniasis. *Lancet.* 2018; 392: 951–70.
- Veciana, M., Becerra, J.L., Fossas, P., Muriana, D., Sansa, G., Santamarina, E., Gaig, C., Carreño, M., Molins, A., Escofet, C., Ley, M., Vivanco, R., Pedro, J., Miró, J., Falip, M., 2015. EEG extreme delta brush: An ictal pattern in patients with anti-NMDA receptor encephalitis. *Epilepsy Behav.* 49, 280–285.