Antibodies to Glutamate Kainate receptors GluK2 in Autoimmune Encephalitis and Cerebellitis

Landa J[1]*, Guasp M,[1,2]*, Míguez-Cabello F,[1,3] Guimaraes J, Mishima T, IIzuka T, Zipp F, Krajinovic, Fuhr P, Maudes E, [1] Garcia A,[1] Honnorat J, Titulaer M, Simabukuro M, Planaguma J,[1] Ruiz-Garcia R,[2] Martinez-Hernandez E, [1,2] Armangue T,[1,2] Saiz A,[1,2] Gasull X,[1,3] Soto D,[1,3] Graus F, [1] Sabater L,[1]** Dalmau J[X-Z]**

[1]Institut d'Investigacions Biomèdiques August Pi i Sunyer (IDIBAPS), Hospital Clínic, Universitat de Barcelona, Barcelona, Spain;

[2]Neurology Department, Institute of Neuroscience, Hospital Clínic, Barcelona, Spain;

[3]Neurophysiology Laboratory, Department of Biomedicine, Faculty of Medicine, Neuroscience Institute, University of Barcelona, Barcelona, 08036 Spain

Co-authors: Please add affiliations

[X]Centro de Investigación Biomédica en Red, Enfermedades Raras (CIBERER), Spain;

[Y]Department of Neurology, Perelman School of Medicine, University of Pennsylvania, Philadelphia, PA, USA;

[Z]Catalan Institute for Research and Advanced Studies (ICREA), Barcelona, Spain

*These authors have contributed equally

**The authors have contributed equally as senior investigators

Abstract word count, 249; **Text** word count, 4498; **References,** 42; Tables 2; Figures 6.

Key search terms: autoimmune, encephalitis, cerebellitis, kainate, receptors, glutamate

Correspondence: Lidia Sabater PhD (lisabate@clinic.cat) and Josep Dalmau MD, PhD (jdalmau@clinic.cat), IDIBAPS-Hospital Clínic, University of Barcelona, Casanova, 143; Floor 3ª, Barcelona 08036 (Spain)

Abstract

Objective: To report the identification of antibodies against the glutamate kainate receptor subunit 2 (GluK2) in patients with autoimmune encephalitis, and describe the clinical features, IgG subclass, subunit targets, and antibody pathogenicity.

Methods: Sera and CSF from 2 patients with similar brain immunostaining were used to precipitate the antigen from cultures of rat cerebellar neurons. A cell-based assay (CBA) with GluK2-expressing HEK293 cells was used to test 127 patients with unclassified neuropil antibodies, 477 with different neurological disorders, and 23 normal subjects. The IgG subclass was characterized by CBA. The effects of antibodies were determined by confocal microscopy in cultured neurons, and by electrophysiology in GluK2-expressing HEK293 cells.

Results: Patients' antibodies precipitated GluK2. CBA identified 8 patients with GluK2-only antibodies, all IgG1. Six presented with acute encephalitis and clinical or MRI features of predominant cerebellar involvement and 2 developed other syndromes (1 with cerebellar involvement). Overall, 4/8 patients developed cerebellitis (2 with severe edema, compression of the 4th ventricle, and hydrocephalus). In 6 additional patients, GluK2 antibodies coexisted with AMPA (5) or NMDAR (1) antibodies and the syndrome was driven by the concurrent antibodies. GluK2 antibodies internalized GluK2 receptors in rat hippocampal neurons, and these effects were reversible. A significant reduction of GluK2-mediated currents was observed in cells treated with patients' serum following the time frame of antibody-mediated GluK2 internatization.

Interpretation: GluK2 antibodies associate with an encephalitis with prominent clinical and radiological cerebellar involvement. The antibody-mediated structural and

electrophysiological effects are predominantly caused by internalization of Gluk2-containing kainate receptors.

Introduction

Human autoantibodies can impair central nervous system (CNS) excitatory synaptic transmission causing different syndromes with a range of manifestations that vary according to the target antigen.[1] In the CNS, excitatory synaptic transmission is largely mediated by three types of ionotropic glutamate receptors: the N-methyl-D-aspartate receptors (NMDAR), the alpha-amino-3-hydroxy-5-methyl-4-isoxazolepropionic acid receptors (AMPAR), and the kainate receptors. Each of these receptors is composed of four subunits that form a central ion channel with a subunit composition that varies according to the type of receptor.[2, 3]

In 2007, a linkage of clinical-immunological findings in patients with similar neurologic symptoms of unknown etiology and neuronal antibodies that produced an identical pattern of brain immunostaining led to initially recognize anti-NMDAR encephalitis[4] and two years later, anti-AMPAR encephalitis.[5] Whereas in anti-NMDAR encephalitis the clinical features outlined a novel syndrome with a characteristic multistage neuropsychiatric presentation,[6] in anti-AMPAR encephalitis the clinical and MRI findings were frequently similar to limbic encephalitis.[7, 8] Common immunological characteristics of these two diseases are that the IgG antibodies are subclass IgG1, recognize extracellular epitopes, and cause internalization of the corresponding receptors.[9, 10]

Here we describe the clinical features, IgG subclass, subunit targets, and antibody effects in a group of patients with antibodies against the glutamate kainate receptor (GluK) subunit 2 (GluK2). In addition we provide a clinical-immunological spectrum that varies according the protein sequence homology of AMPAR and kainate receptors.

Methods

Patients and samples

From January 2013 until December 2019 we identified 127 patients whose serum and CSF were investigated at Hospital Clínic-IDIBAPS for suspected autoimmune CNS disorders and had antibodies that showed intense reactivity with the neuropil of rat brain and primary cultures of rat hippocampal neurons. Of these 127 patients, we selected serum and CSF samples from 8 patients that showed the same pattern of brain immunostaining, but different from those associated with anti-AMPAR, NMDAR, or any other known autoimmune encephalitis. As controls, we included the serum of 23 healthy blood donors and serum or CSF of 596 patients with the following diagnosis: 73 multiple system atrophy with predominant cerebellar phenotype, 73 anti-NMDAR encephalitis, 71 anti-AMPAR encephalitis, 48 cerebellitis of unknown etiology, 40 multiple sclerosis, 37 paraneoplastic cerebellar degeneration, 30 opsoclonus-myoclonus, 29 non-hereditary degenerative ataxia, 23 neuromyelitis optica spectrum disorder, 20 encephalitis with neuronal surface antibodies other than NMDAR or AMPAR, 20 progressive supranuclear palsy, 13 Creutzfeldt-Jakob disease, and 119 cases with encephalitis of unclear etiology and atypical neuronal antibodies.

Immunohistochemistry with brain tissue and immunofluorescence with cultured neurons

Rat brain immunostaining was performed with patients serum (diluted 1:200) and CSF (1:2) using a standard immunoperoxidase technique. Immunofluorescence with primary cultures of rat hippocampal neurons was performed with serum (1:200) and CSF (1:5). Both techniques have been previously reported.[5, 11]

Immunoprecipitation

Cultures of rat cerebellar granule neurons and the technique of immunoprecipitation were performed using identical methods as those previously reported.[12] In other experiments, HEK293 cells expressing the identified antigen (GluK2) were incubated with patients' or control serum, and subsequently lysed and precipitated as above. The precipitate was then run in a gel, transferred to nitrocellulose, incubated with a polyclonal GluK2 antibody made in rabbit (diluted 1:500, HPA014623, Atlas antibodies, Sweden), and the reactivity developed with chemiluminiscence, as reported.[12]

Cell-based assays (CBA)

To determine the repertoire of patients' antibodies against each of the human subunits of kainate receptors (GluK1,GluK2, GluK3,GluK4, GluK5), HEK293 cells were transfected with plasmids containing each of the human subunit sequences tagged with MYC-DDK, including: *GRIK1* (RC222898, Origene, Rockville, Maryland, USA), *GRIK2* (RC222369, Origene), or *GRIK3* (RC223571) which are able to form functional kainate-gated homomeric receptors. For *GRIK4* (RC214488, Origene) and *GRIK5* (RC224695, Origene) which only form functional receptors when co-expressed with *GRIK1, GRIK2 or GRIK3*, we used co-transfections with *GRIK3/GRIK4 or GRIK3/GRIK5,* as well as each subunit separately. The techniques of transfection and incubation of HEK293 cells with patients' samples (CBA) are identical as those previously reported for other synaptic proteins.[5, 13] Briefly, live transfected HEK293 cells were incubated with serum (1:50) or CSF (1:5) for 1 hour at 37ºC. After fixation with 4% paraformaldehyde (PFA) and permeabilization with 0.3% Triton X-100, the cells were incubated with a mouse MYC-tag antibody (2276S; diluted 1:2500, from Cell Signaling Technology, Danvers, MA) for 1 hour at room

temperature (RT) followed by fluorescent secondary antibodies Alexa Fluor 488 goat anti-human (1:1000, 109-545-088, Jackson ImmunoResearch, Newmarket, UK) and AlexaFluor 594 goat anti-mouse (1:1000, A-11005, Thermo-Fisher Scientific, Waltham, MA, USA).

The presence of AMPAR or NMDAR antibodies was examined with CBA expressing GluA1/GluA2 subunits of AMPARs or GluN1/GluN2B subunits of NMDARs.[5, 13] The serum and CSF dilutions and duration of incubations were as above.

To determine whether patients' antibodies were able to internalize GluK2 in HEK293 cells, live cells were treated for 30 minutes to 5 hours with patient's serum (diluted 1:100 in the media). After washing, live cells were incubated for 1 hour with excess of Alexa Fluor 488 goat anti-human IgG (diluted 1:20; Jackson ImmunoResearch) to block all cell-surface human IgG, and then washed, permeabilized, and the internalized IgG was demonstrated with a differently labeled secondary anti-human antibody (Alexa Fluor 594 goat anti-human IgG, diluted 1:1000; 109-585-088, Jackson ImmunoResearch). All CBA immunofluorescence studies were examined with a Zeiss AxioImager M2 fluorescent microscope with Apotome system (Carl Zeiss, Jena, Germany).

IgG subclass

The IgG subclass of the antibodies was assessed using CBA with HEK293 cells expressing GluK2 and secondary anti-human antibodies specific for IgG1, IgG2, IgG3 and IgG4, as reported.[14]

Immunoabsorption studies

Sera with reactivity restricted to GluK2 (i.e., absent reactivity with other GluK subunits) or sera with GluK1/2/3 reactivity were serially incubated with 8 P60 plates containing live HEK293 cells expressing GluK2 or mock-transfected cells. Each of the 8 sequential incubations was for 1 hour at RT. The immunoabsorbed sera were then examined with rat brain immunohistochemistry, live hippocampal neurons, and CBA, as reported.[15]

Quantitative analysis of GluK2 clusters in cultured neurons using confocal microscopy

Rat hippocampal neurons were treated at 14DIV with CSF from Patient 1 (containing exclusively GluK2-ab) or control CSF (both 1:20 diluted) for 24h or 72h. After removing the antibodies by changing the media, neurons were allowed to recover for 4 days. At the indicated time points (24h, 72h, and post 4-day recovery), neurons that had been exposed to patient's or control CSF were extensively washed and incubated with human IgG isolated from serum with GluK2 antibodies (1:200, used here as primary antibody) for 1h at 37ºC. All GluK2 cell-surface receptors labeled with human IgG were then demonstrated with an Alexa Fluor 488 goat anti-human IgG (1:1000, 109-545-088, Jackson Immuno Research) for 1 hour at RT. Cells were then fixed with 4% PFA for 5 minutes, permeabilized with 0.3% Triton X-100 for 5 minutes and incubated with rabbit polyclonal anti-PSD95 antibody (1:200, ab18258, Abcam, Cambridge, UK) for 1 hour, followed by the corresponding secondary antibody Alexa Fluor 594 goat anti-rabbit IgG (1:1000, A-11012, Thermo Fisher Scientific) for 1 hour at RT. Total and synaptic clusters of GluK2 were visualized by confocal imaging (LSM710, Carl Zeiss, Jena, Germany). Images were deconvolved using Huygens Professional version 17.04 (Scientific Volume Imaging, The Netherlands) and quantified using Imaris 8.1 software (Bitplane AG, Zürich, Switzerland), as reported.[16, 17]

Electrophysiology in GluK2 transfected HEK293 cells

HEK293T cells were transiently transfected with 1 µg total DNA from constructs codifying for GluK2(Q) and eGFP in a 9:1 (GluK2(Q):GFP) ratio by using polyethylenimine (PEI) transfection method (3µg of PEI per 1 µg DNA) in free-serum media. After 3-hour transfection, cells were split and yielded in glass coverslips treated with poly-L-lysine at low density. Twenty-four hours after transfection, coverslips were treated with patient' or control's serum (diluted 1/100 in the media) for 30 minutes or 5 hours, at 37°C and 5% CO_2.

Electrophysiological recordings were obtained within less than 1 hour after serum was removed and cells were placed in the recording chamber. Untagged non-edited GluK2(Q) subunit expression was determined by patching GFP positive cells. Transfected cells were visualized with an inverted epifluorescence microscope (Axio-Vert.A1; Zeiss). Cells were continuously perfused at RT with extracellular physiological solution (in mM): 145 NaCl, 2.5 KCl, 1 $CaCl_2$, 1 $MgCl_2$, 10 HEPES, and 10 glucose, adjusted to pH 7.4 with NaOH. Whole-cell recordings were made from isolated cells using electrodes with open-tip resistances of 5–9 MΩ (7.6 ± 0.2 MΩ) made from borosilicate glass (1.5 mm o.d., 0.86 mm i.d., Harvard Apparatus), pulled with a P-97 vertical puller (Narishige) and, giving a final series resistance of typically 10-25 MΩ (17.4 ± 0.6 MΩ). Glutamate 10 mM (Sigma-Aldrich) was applied to cells by piezoelectric translation (P-601.30; Physik Instrumente) of a theta-barrel application tool made from borosilicate glass (1.5 mm o.d.; Sutter Instruments) at a holding potential of –60 mV. Glutamate pulses were applied during 2s every 20s to allow GluK2 homomeric receptors to recover from desensitization. At the end

of each recording, the adequacy of the solution exchange was tested by destroying the seal and measuring the liquid-junction current at the open pipette (10-90% rise time normally 600-800 μs). Currents were acquired at 5 kHz and low-pass filtered at 2 kHz with an Axopatch 200B amplifier, Digidata 1440A interface and pClamp10 software (Molecular Devices Corporation). Intracellular pipette solution contained (in mM): 145 CsCl, 2.5 NaCl, 10 HEPES, 1 Cs-EGTA and 4 MgATP, adjusted to pH 7.2 with CsOH. Recordings were analysed using IGOR Pro (Wavemetrics Inc.) with NeuroMatic (Jason Rothman, UCL).

Statistical analyses

In confocal microscopy studies, data are presented as box plots showing the median, and 25th and 75th percentile; whiskers indicate the minimum and maximum values. The effect of patients' serum compared with control serum, on the number of neuronal clusters of GluK2 and PSD95 was analyzed with one-way ANOVA with Bonferroni's multiple comparison test. In electrophysiological studies, data are presented in the figures as bar plots of the mean with error bars denoting the S.E.M. Comparisons between groups were performed using the non-parametric Kruskall-Wallis with Dunn's multiple comparisons test. Differences were considered significant at $p<0.05$. Statistical analysis was performed using GraphPad Prism version 5.0d for Mac OS X (GraphPad Software, San Diego California USA, www.graphpad.com).

Results

Serum and CSF of the two patients indicated below were used for antigen characterization. In both cases the samples immunoreacted with an antigen expressed on the cell-surface of neurons and produced an identical pattern of brain immunostaining (Figure 1).

Patient #1: A 24 year-old man was brought to the emergency room for acute onset headache, nausea and vomiting. Eight years earlier he was treated for Hodgkin's lymphoma and since he had no evidence of disease. Preceding the current symptoms the patient described several weeks of dizziness and photophobia. At exam, the memory, cognition, and cranial nerve function were intact, and no focal motor or sensory deficits were detected. The CSF showed 52 white blood cells/mm^3 and increased protein concentration (1.18 g/L). Because of the suspicion of herpes simplex encephalitis, he was started on acyclovir until the PCR results came back negative. On day 3 after admission, the headache worsened and he developed clinical and MRI features of cerebellitis with edema and mass effect causing obstructive hydrocephalus (Figure 2, top row). Treatment with intravenous steroids and mannitol resulted in neurologic improvement. A body fluorodeoxyglucose (FDG)-PET scan showed a hypermetabolic supraclavicular adenopathy with biopsy findings consistent with Hodgkin's lymphoma. He received chemotherapy and radiotherapy resulting in progressive improvement. At the last follow-up, 2 years after symptom onset, he was fully recovered.

Patient #2: A previously healthy 15 year-old woman developed fever, headache, vomiting, and decreased level of consciousness. At hospital admission, she was diagnosed with acute hydrocephalus due to cerebellitis. The brain MRI revealed increased T2/FLAIR and DWI signal abnormalities involving the cerebellum, hippocampus and frontal lobes (Figure 2, middle row). She was treated with methylprednisolone and an external ventricular drainage. CSF studies showed 105 white blood cells/mm^3, and a protein of 0.22g/L. After her level of

consciousness improved, the neurological examination showed memory deficits and cerebellar symptoms including dysarthria, limb ataxia, and impaired balance. The EEG demonstrated slow background and epileptiform activity without clinical correlate. The patient was treated for 10 days with high dose steroids without further immunomodulation. At the last follow-up visit, 3 years after disease onset, she was stable but with residual gait ataxia and mild learning difficulties.

Identification of GluK2 as the main target antigen

Live neuron immunoprecipitation with patients' serum revealed 21 and 25 unique peptides respectively, covering the 26% and the 33% of the rat GluK2 protein sequence (NP_062182.1). Peptides from other GluK subunits were also immunoprecipitated but with lower score: GluK1 (2 unique peptides), GluK3 (2 unique peptides), GluK4 (3 unique peptides), GluK5 (5 unique peptides). The most abundant peptide was precipitated with both serum samples (peptide: MESPIDSADDLAK) and corresponds to an identical sequence shared by GluK1 (NCBI accession number: NP_001104584; 664-676 aminoacids), GluK2 (NP_062182.1; 664-676 aminoacids) and GluK3 (NP_001106187.1; 666-678 aminoacids) located in the extracellular S2 segment of the ligand binding domain of the protein.

GluK2 CBA test and IgG1 antibody subclass

All 8 patients initially selected for their similar pattern of brain immunostaining showed robust reactivity with HEK293 cells transfected with GluK2, providing a cell-based assay (CBA-GluK2) (Figure 3A-F). In all cases, the specificity of GluK2 reactivity in CBA was confirmed by immunoprecipitation (Figure 3G). Moreover, CBA-GluK2 using secondary

antibodies against the four IgG subclasses, demonstrated that in all 8 patients the antibodies were IgG1 (data not shown).

GluK epitope-sharing, and GluK2 antibodies in other anti-glutamate receptor encephalitis

Considering that the amino acid sequence of GluK2 is ~80% identical to GluK1 and GluK3, and ~40% identical to GluK4 and GluK5,[18] we examined the samples of all 8 patients for additional reactivity with GluK1 and GluK3, and available samples from 7 patients for GluK4 and GluK5 reactivity. Patient 5 (Table 1) had additional antibody reactivity with GluK1, and patients 2 and 3 with GluK1 and GluK3 (data not shown). Immunoabsorption studies showed that samples pre-absorbed with HEK293-GluK2 cells no longer reacted with GluK1 or GluK3, demonstrating that the reactivity was due to epitope sharing (Figure 4).

None of the 8 patients had concurrent antibodies against the other two glutamate receptors (NMDAR, AMPAR), although 4 showed atypical CSF AMPAR reactivity in a commercial CBA along with brain immunostaining different from AMPAR. This unusual finding and the ~40% amino acid identity between GluK2 and GluA1/GluA2 subunits of the AMPAR (which are the antigens in anti-AMPAR encephalitis), and ~25% amino acid identity with subunits of the NMDARs, led us to investigate 71 randomly selected patients with anti-AMPAR encephalitis and 73 with anti-NMDAR encephalitis for GluK2 antibodies. Among these 144 cases, GluK2 antibodies were found in 5/71 with anti-AMPAR encephalitis and 1/73 with anti-NMDAR encephalitis. A summary of the clinical information, antibody associations, and co-morbidities is provided in the last section of results. GluK2 antibodies were not found in the serum or CSF of the remaining 458 patients

with autoimmune or neurodegenerative disorders or in the serum of 23 healthy blood donors.

Patients' antibodies cause a decrease of GluK2 clusters in live rat hippocampal neurons

To examine the structural and functional effects of patients' antibodies on neuronal GluK2 receptors we selected 2 CSF samples that only contained GluK antibodies. Neurons treated with patient's CSF compared with those treated with control CSF, showed a significant reduction of cell-surface clusters of GluK2 (Figure 5). Longer treatment with patient's CSF (e.g., 72 vs 24 hours) caused more robust effects (Figure 5A,B). The effects were less prominent for GluK2 located at synapses, which were significantly reduced after 72 hour treatment with patient's CSF antibodies (Figure 5A,D). In contrast, the clusters of PSD95 were unaffected (Figure 5A,C). After changing the media to remove the antibodies, and allowing the neurons to recover for 4 days, the levels of GluK2 clusters returned to values similar to those of controls (Figure 5 A,B,D). Similar findings were obtained with the CSF sample of the second patient (data not shown).

Patients' antibodies impair GluK2-mediated currents

Electrophysiological studies were performed with HEK293 cells expressing GluK2 receptors (Figure 6A,B). Compared with non-treated cells or cells treated with serum of a healthy subject, the cells treated with 2 patients' sera showed a significant decrease of GluK2-mediated currents (Figure 6A,B). The impairment of GluK2-mediated currents occurred only in cells that had been exposed for several hours (~5 hours) to patients serum but not in cells that had very short incubations (e.g., 30 minutes). Parallel studies with HEK293 cells expressing GluK2 showed that long treatment (~5 hours) with patients'

serum caused internalization of receptors, whereas receptor internalization was not visible with 30 minute incubations (Figure 6C). Overall, these findings suggest that patients' antibodies impair GluK2-mediated currents and that this effects is likely due to receptor internalization rather than a direct antagonist effect of the antibodies in which case an impairment of receptor function would be visible after 30 minute incubations.

Clinical and immunological spectrum of GluK2 autoantibodies

A summary of the 8 patients that originated this study is shown in Table 1 (Cases #1-8). The median age at disease onset of these 8 patients was 28 years (range: 14-75 years), 5 were male. In all but one patient (who had concurrent HIV-related symptoms) the new onset of neurological symptoms progressed rapidly, in less than 6 weeks, until reaching the peak of the disease. Four patients, median age 19 years (range 14-33) presented with prominent clinical manifestations, including opsoclonus in one, compatible with cerebellitis. Two of them developed obstructive hydrocephalus, requiring ventricular drainage in one; the other was controlled with mannitol. Three patients (23, 67 and 75 years old) developed a more diffuse encephalitis with prodromal flu-like symptoms followed by limb or gait ataxia (2 cases) and confusion, disorientation, irritability, delusional thoughts, psychomotor agitation, myoclonus, or seizures. Another patient was a 73 year-old man, HIV positive, with a 2 year history of progressive gait instability and cognitive decline preceding a recent (~3 months) clinical deterioration. At neurological examination, he had saccadic intrusions in smooth ocular pursuits, lower-limb hyperreflexia, bilateral upgoing toes, and marked broad-based and spastic gait, requiring support to walk. No limb dysmetria was observed. MRI studies were available in 7 patients and in 5 showed

multifocal T2-FLAIR abnormalities in the cerebellum with or without cerebral involvement (Figure 2). In one of these patients (case # 5) the extensive MRI cerebellar abnormalities had limited correlation with clinical symptoms, which were mild (Figure 2 lower row). In the remaining 2 patients with assessable MRI, brain and cerebellar atrophy were identified. Seven of the 8 patients had CSF pleocytosis. Except for the index case with relapsing Hodgkin's lymphoma none of the patients had an active tumor; one had a retroperitoneal teratoma removed 1 year before onset of the neurological syndrome, without current evidence of disease. All 8 patients were treated with steroids and only 2 received immunomodulation (patient 6: 1 IVIg; and patient 4: IVIg, plasma exchange, rituximab, cyclophosphamide). Three patients had partial or full recovery, 2 died in the acute phase of the disease (1 multiple systemic complications, 1 sepsis), 1 with chronic progressive HIV-related symptoms died 27 months after disease onset of unclear cause, and 1 was lost to follow-up. From the remaining patient (case 3) information beyond symptom presentation was not available; however, she was a 14 year-old girl who developed cerebellitis with acute cerebellar ataxia.

Separate from the 8 patients with GluK2-only or predominant antibodies, there were 5 patients with anti-AMPAR and 1with anti-NMDAR encephalitis that had concurrent GluK2 antibodies (Table 2). Four of the 5 cases with AMPAR antibodies had tumors (3 thymomas, 1 SCLC). The 3 cases with thymoma had several additional antibodies (2 CRMP5; 1 AChR, CASPR2, and GABAbR) and all showed a pattern of brain immunostaining composed of the expected mix of reactivities. However, in one of the cases with concurrent AMPAR antibodies and in the case with NMDAR antibodies, the brain immunostaining did not show the GluK2 reactivity. None of the 6 patients with concurrent antibodies developed

clinical or MRI features of cerebellar dysfunction, and in all the clinical syndrome was driven by the concurrent antibodies.

Discussion

We found that the glutamate kainate receptors containing GluK2 (previously known as GluR6) are the target of autoantibodies in some patients with encephalitis or cerebellitis of unclear etiology, and that these antibodies are likely pathogenic. This is supported by several findings: 1) the antibodies react with extracellular GluK2 epitopes in cultures of live rat hippocampal cultures and GluK2-expressing HEK293 cells; 2) they are IgG1 and internalize GluK2 receptors; 3) this receptor internalization led to a significant, but reversible, decrease of synaptic and extrasynaptic clusters of GluK2; 4) Patients serum antibodies, but not control serum, significantly reduced GluK2-mediated currents in HEK293 cells expressing these receptors, and 5) some patients responded to empiric steroids or first line immunotherapy.

The kainate receptors are tetrameric ionotropic glutamate receptors that may include GluK1, GluK2, GluK3, GluK4 or GluK5, previously known as GluR5, GluR6, GluR7, KA1 and KA2.[3] GluK1, GluK2 and GluK3 form functional homo- and heterotetrameric receptors, whereas GluK4 and GluK5 form functional receptors only when co-expressed with GluK1 to GluK3.[3] As in the case of the GluA2 subunit of the AMPARs, GluK1 and GluK2 present Q/R editing at the second transmembrane domain (TM2). This Q-to-R substitution abolishes Ca2+ permeability while increases Cl^- permeation of the channel.[19, 20] In addition, Q residues accounts for larger conductance and inward rectification, while R residues display smaller conductance and linear or mildly outward rectification.[21] In the

current study Q/R editing did not modify the antibody reactivity with GluK2 (data not shown).

The kainate receptors are unconventional members of the glutamate receptor family in that, different from NMDAR or AMPAR, they are not predominantly found in excitatory postsynaptic complexes. In addition to function as inotropic receptors, kainate receptors act as modulators for synaptic transmission and neuronal excitability interacting with metabotropic signaling pathways.[3] They play a crucial role as presynaptic regulators of neurotransmitter release at both excitatory and inhibitory synapses by mechanisms not completely understood,[22, 23] are able to facilitate short-term and long-term plasticity[24, 25] and can act as modulators of GABAergic transmission.[26]

Our initial goal to characterize the autoantigen of a group of patients with antibodies that showed a similar pattern of brain immunostaining was expanded after finding that the antigen was GluK2, which has a protein sequence highly similar to other glutamate receptor subunits (~80% identity with GluK1, GluK3; ~ 40% with GluK4, GluK5 and GluA1, GluA2 of AMPAR; and ~25% with NMDAR subunits).[18] Thus, it was not surprising that the antibodies of some patients cross-reacted with epitopes shared with GluK1/GluK3, as demonstrated with immunoabsorption studies. However, investigations with patients that had otherwise classical anti-AMPAR or NMDAR receptor encephalitis resulted in the identification of a group of 6 patients, mostly with AMPAR antibodies, who had concurrent GluK2 antibodies. Compared with patients with GluK-only or predominant antibodies, those with AMPAR or NMDAR antibodies were more likely to have tumors (mainly thymoma), multiple autoantibodies, and the pattern of brain immunostaining was composed of the expected mix of immunoreactivities or in 2 cases it was exclusively AMPAR or NMDAR. Overall, in the group of patients with concurrent antibodies, the syndrome and

outcome were driven by the accompanying antibodies and tumors.[7] These findings suggest that the GluK2 epitopes in both groups of patients may differ and are probably less clinically relevant in the second group. Future studies with immunocompetition between samples representative of both groups of patients may clarify this hypothesis, but the currently available small amounts of serum/CSF precluded to perform this experiment.

We found that a prolonged treatment (>5 hours) of GluK2-expressing HEK293 cells with patients' samples induced a robust reduction of GluK2-mediated currents that was not observed after a short treatment (~30 minutes), suggesting that the impairment of GluK2-currents was secondary to the reduced cell-surface receptors (remaining fraction, not internalized) rather than an antagonistic effect of the antibody on receptor function. This paradigm is similar to the pathogenic mechanisms described in other anti-glutamate receptor encephalitis (NMDAR[9, 27] or AMPAR[10, 28]) that are largely mediated by internalization of receptors, whereas for GlyR antibodies a robust antagonistic effect (along with mild-moderate internalization), have been demonstrated.[29, 30]

Although several types of autoimmune encephalitis can manifest with cerebellar symptoms, they almost never present as acute cerebellitis.[1] The fact that 4 of 8 patients with GluK2-only or predominant antibodies developed early and prominent clinical or MRI findings of cerebellar-brainstem dysfunction or cerebellitis (causing obstructive hydrocephalus in two) is notable and provide a clue to suspect this disorder. In general, most reported patients with acute cerebellitis are children or young adults and they usually respond to steroids.[31, 32] GluK2 antibodies represent the first relevant antibody found in patients with this syndrome. In 5 Japanese children with acute cerebellitis, IgM or IgG antibodies against the glutamate receptor delta 2 were identified.[33-35] Unlike the GluK2 antibodies reported here, the clinical or pathogenic significance of glutamate receptor delta

2 antibodies is unclear as they have been also described in children with multiple different disorders such as dystonia, encephalitis, opsoclonus-myoclonus, or neuroblastoma without neurological symptoms.[36-38]

In contrast to the group of patients with GluK2-only or predominant antibodies, none of the 6 patients with GluK2 antibodies concurrent with anti-AMPAR encephalitis (with or without CRMP5 antibodies) or anti-NMDAR encephalitis, and none of the additional randomly selected 138 patients with anti-NMDAR or AMPAR encephalitis, had the clinical-radiological profile of acute cerebellitis, obstructive hydrocephalus, or opsoclonus-myoclonus (data not shown). However, some of these features, such as cerebellar dysfunction with AMPAR antibodies,[8] or opsoclonus with NMDAR antibodies,[39, 40] have been reported and it is currently unknown whether they had GluK2 antibodies.

Our study has limitations posed by the retrospective analysis and small number of cases that usually occurs in first descriptions of autoimmune encephalitis.[5, 13, 41, 42] It is currently unclear the long-term outcome of patients with GluK-only or predominant antibodies because only 2 patients received immunomodulation (the rest of assessable cases only received steroids), 2 died in the acute phase of systemic complications, and 1 died 27 months after an episode of rapid progression of symptoms superimposed to slow progression of HIV-related deficits. Yet, 3 patients showed substantial improvement, 1 of them with full recovery, suggesting that prompt diagnosis and an immunotherapy approach similar to that used in other autoimmune encephalitis (steroids, IVIG, plasma exchange, rituximab or cyclophosphamide) may be effective.

The current findings have important clinical implications. GluK2 antibody-associated encephalitis should be suspected in cases of rapid presentation of encephalitis of unknown cause with clinical-radiological cerebellar involvement, ranging from mild cerebellar

symptoms to severe cerebellitis which may be accompanied by extensive MRI T2-FLAIR abnormalities not restricted to cerebellum. Accompanying findings may include encephalopathy (confusion, memory deficit, behavioral change, rarely seizures), signs of corticospinal tract involvement (hyperreflexia, upgoing toes, ataxic-spastic gait), or opsoclonus-myoclonus. At symptom onset, patients should be monitored for potential life-threatening posterior fossa edema and obstructive hydrocephalus. If possible, antibodies should be examined in CSF and serum with CBA and brain immunostaining. The presence of concurrent AMPA or NMDAR antibodies, associates with syndromes and comorbidities driven by the coexisting antibodies. Future studies should focus on refining epitope-syndrome associations, assess the efficacy of immunotherapy, and develop animal models of the disease.

Acknowledgements

We thank Esther Aguilar and Mercedes Alba for their excellent technical support, and Ana Valero Paternain and Juan Lerma (Instituto de Neurociencias de Alicante) for providing the GluK2(Q) DNA construct.

Author disclosures:

Dr. Dalmau holds patents for the use of Ma2, NMDAR, GABAbR, GABAaR, DPPX and IgLON5 as autoantibody tests. Dr. Graus holds a patent for the use of IgLON5 as an autoantibody test. Dr. Dalmau receives royalties related to autoantibody tests from Athena Diagnostics and Euroimmun, Inc. Co-authors please indicate. The rest of the authors XXX have no conflicts of interest related to the submitted work.

Study funding: The proteomics analyses were performed in the CRG/UPF Proteomics Unit, which is part of the Spanish Infrastructure for Omics Technologies (ICTS OmicsTech) and member of the ProteoRed, PRB3, supported by grant PT17/0019 of the PE I+D+i 2013–2016 funded by ISCIII and ERDF. Fondo Europeo de Desarrollo Regional (FEDER) – Ministerio de Ciencia e Innovación (BFU2017-83317-P) to DS. Fondo Europeo de Desarrollo Regional (FEDER) -Instituto de Salud Carlos III (FIS PI17/00296 and RD16/0008/0014 to XG; FIS PI018/00067 to LS; FIS XXX Thais; FIS 17/00234 to JD and Proyecto Integrado de Excelencia 16/00014 to JD). Generalitat de Catalunya 2017SGR737 to XG. Ministerio de Ciencia e Innovación, Maria de Maeztu MDM-2017-0729 to DS and XG; ERA-NET NEURON (JD); "La Caixa" Foundation (JD); Safra Foundation (JD); Fundació Cellex (JD).

Table 1: Clinical features of patients with isolated GluK2 antibodies in serum and CSF*

Patient	Sex/ age	Main symptoms	Brain MRI	CSF	Outcome Follow-up months, outcome
1	M/24	Headache, nausea, vomiting, cerebellitis, obstructive hydrocephalus, decrease level of consciousness	Bilateral FLAIR/T2 hyperintense changes in cerebellum; hydrocephalus	WBC 52 Prot 118	24, full recovery
2	F/15	Headache, vomiting, fever, cerebellitis, hydrocephalus, increased reflexes, upgoing toes, decrease level of consciousness	Bilateral DWI/FLAIR increased signal in frontal, temporal, cerebellar regions; hydrocephalus.	WBC 105 Prot 22	36, partial recovery (mRS 2)
3	F/14	Acute cerebellitis with prominent cerebellar ataxia	n/a	n/a	n/a
4	F/33	Headache, nausea, vomiting, rapidly progressive cerebellitis, prominent ataxia, myoclonus and later opsoclonus	Mild cerebellar edema, increased FDG-PET activity in cerebellum	WBC 359 Prot 520	36, residual ataxia, mild opsoclonus, able to walk and perform activities of daily living
5	M/75	Fever, behavioral change, confusion, memory loss, dizziness, decrease level of consciousness, myoclonus, bradykinesia, Limb and gait ataxia	DWI/FLAIR increased signal in cerebellum and left temporal cortex. No reduction of ADC.	WBC 0 Prot 45 OCB+	6, partial recovery; died.
6	M/73	HIV+, alcohol abuse, chronic gait dysfunction (spastic-mild ataxia), and cognitive decline. Sudden rapid progression of unsteady gait, confusion, saccadic pursuit, spastic-ataxic gait, increased reflexes, upgoing toes.	Brain and cerebellar atrophy	WBC 20 Prot 40	27, died (cause unkown)
7	M/67	Nausea, vomiting, gait instability. Ataxia, myoclonus, choreoathetosis, weakness in arms and legs.	Mild general atrophy	WBC 240 Prot 72	5, died in the acute phase of the disease (sepsis)
8	M/23	Insomnia, delusional thoughs, agitation, seizures	Multifocal FLAIR/T2 hyperintense lesions in temporal lobes and subcortical white matter	WBC 6 Prot 86	n/a

Table 2: Clinical features of patients with GluK2 and concurrent antibodies

Patient	Sex/ age	Antigen	Main syndrome	Brain MRI	CSF	Tumor	Followp
9	M/67	AMPAR, GluK2, 1, 3	Limbic encephalitis*	FLAIR/T2 increased signal in medial temporal lobes.	WBC N Prot N	no	3 months, died in the acute phase of the disease (sepsis)
10	F/70	AMPAR, GluK2	Acute presentation of short-term memory loss, confused, disoriented.	normal	WBC N Prot 64	SCLC	Partial improvement, died of cancer 39 months after symptom onset
11	F/44	AMPAR, CRMP5, GluK2, 1	Limbic encephalitis*	n/a	WBC 15 Prot, N	thymoma	No improvement. Autopsy confirmed inflammatory infiltrates in both temporal lobes
12	F/51	AMPAR, CRMP5, GluK2, 1	Acute confusion, memory loss, asymmetric weakness in arms and legs.	n/a	WBC N Prot, N	thymoma	n/a
13	F/41	AMPAR, GABAbR, CASPR2, GluK2, 1, 3	Limbic encephalitis*	FLAIR/T2 increased signal in medial temporal lobes.	WBC 10 Prot, N	Metastatic thymoma	n/a
14	F/14	NMDAR, GluK2	Anti-NMDAR encephalitis*	Normal	WBC 63 Prot N	no	Substantial recovery; mild residual deficits in processing speed.

* Patients with typical clinical manifestations of limbic or anti-NMDAR encephalitis

Figure Legends

Figure 1: Brain immunostaining with CSF from a patient with GluK2 antibodies compared with that of patients with AMPAR or NMDAR antibodies

Panels A-C show a sagittal section of rat brain immunostained with the CSF from a patient with GluK2 antibodies; B and C show enlarged views of the hippocampus and cerebellum. Panels D-I show similar images corresponding to CSF from a patient with AMPAR antibodies (D-F), and CSF from a patient with NMDAR antibodies. Note that the patterns of hippocampal and cerebellar staining are different for each autoantibody. In hippocampus, features distinctive of GluK2 antibodies include the band-like of reinforced staining in the inner part of the molecular layer adjacent to the granular neurons of the dentate gyrus (arrows in B), and immunostaining of the hilum (arrowhead in B); in the cerebellum , Gluk2 antibodies show strong reactivity with the granular cells of cerebellum (arrow in C). Scale bars, G = 2mm; H = 250μm; I = 250μm.

Figure 2: Brain MRIs in 3 patients with GluK2 antibody associated cerebellitis

Panels A-E (patient 1) correspond to fluid-attenuated inversion recovery (FLAIR)-T2 MRI sequences of selected axial and sagittal sections obtained at symptom onset (A,B), two weeks later (C,D), and at the last follow-up (E). Note the presence of bilateral cerebellar abnormalities with edema and compression of the 4th ventricle at onset, with partial improvement two weeks later, and normal features at the last follow-up.

Panels F-J (patient 2) correspond to diffusion-weighted imaging (DWI) (F,H,J) and FLAIR-T2 (G,I) MRI sequences obtained at symptom onset (F-I) and at the last follow-up (2 years later). There are bilateral, predominantly cortical, cerebellar abnormalities, best seen with

DWI, with mass effect on the 4th ventricle. The vermis was similarly involved, and on apparent diffusion coefficient (ADC) maps no restriction was observed (not shown). At the last follow-up, most of the DWI abnormalities had resolved, but there was moderate residual atrophy (J).

Panels K-O (patient 5) correspond to DWI (K,M,O) and FLAIR-T2 (L,N) MRI sequences obtained at symptom onset (K-N) and 5 weeks later (O). Note the extensive abnormalities bilaterally involving the cerebellum and vermis, best seen in DWI sequences; there is milder involvement of the temporal lobes (left > right). ON ADC maps no restriction was observed. Five 5 after symptom onset most of the DWI abnormalities had improved.

Figure 3: Cell based assay and immunoprecipitation of GluK2

Panels A-C: Cell-based assay with HEK293 cells expressing GluK2 immunolabelled with patient's serum antibodies (green), or a commercial antibody against Myc-tag to confirm the expression of GluK2 (red). Panel C shows the merged reactivities. Panels D-F correspond to a similar CBA using serum from a healthy subject that demonstrates lack of reactivity with GluK2 (D). The nuclei of the cells (blue) is shown with 4',6-diamidino-2-phenylindole (DAPI). Scale bar = 20 μm.

Panel G) Immunoblot showing the immunoprecipitation of GluK2 from live HEK293 cells expressing GluK2 and patients' or control sera. Lanes (+) correspond to GluK2 precipitated with serum from 6 patients; lanes (-) show the lack of GluK2 precipitation using serum from 2 healthy participants; lane M is the molecular weight marker; lane T, corresponds to a lysate of HEK293 cells expressing GluK2, and lane UT correspond to a lysate of HEK293

cells not transfected with GluK2. In all lanes GluK2 was revealed with a polyclonal GluK2 antibody made in rabbit.

Figure 4: Pre-absorption of patient's serum with GluK2 abrogates brain immunoreactivity

Patient's serum reactivity with cerebellum (A,B), live hippocampal neurons (C,D), and a live cell-based assay expressing GluK2 (E,F). Panels on the left correspond to patient's serum preabsorbed with HEK293 cells not expressing GluK2, and panels on the right correspond to the same serum preabsorbed with HEK293 cells expressing GuK2. Note that pre-absorption with GluK2 abrogates the reactivity of patient's serum with cerebellum, live neurons, and live CBA (B,D,F). The red immunofluorescence is a commercial antibody against Myc-tag to confirm that the CBA cells express GluK2. Scale bars B, D, F = 20 μm.

Figure 5: Patient's antibodies cause a reduction of cell-surface and synaptic GluK2 in cultured neurons

Panel A shows that patients' CSF antibodies, but not control CSF, cause a progressive decrease of GluK2 clusters in representative dendrites of cultures of rat hippocampal neurons. Note that the levels of clusters return to normal after removing the antibodies from the media and allowing the neurons to recover for 96 hours. Scale bar = 5 μm. Panels B-D show the quantification of these effects on total neuronal surface GluK2 (B), PSD95 (C), and synaptic GluK2 (D, defined by the co-localization of surface GluK2 with PSD95). The effects on GluK2 are reversible after the 96 hour recovery. n=20 dendrites per condition, three independent experiments. Box plots show the median, and 25th and 75th percentiles;

whiskers indicate the minimum and maximum values. Significance of treatment effect was assessed by one-way ANOVA with Bonferroni correction. **=<0.01; ****=<0.0001.

Figure 6: Patient's serum decrease GluK2-mediated currents

Panels A and B correspond to HEK293 cells expressing GluK2 (Q) treated for 30 minutes or 5 hours with control serum or 2 patient's serum. Current responses were activated by ultra-rapid application of 10 mM glutamate in the cells at -60mV. Panel A, upper traces, show the current responses of cells treated for 30 minutes with the indicated samples, and lower traces show the current responses treated for 5 hours with the same samples. The traces shown correspond to the average of 4-7 consecutive glutamate applications. Panel B shows the average and S.E.M. of glutamate-evoked normalized peak currents for cells untreated (basal), incubated with control serum or 2 patient's serum. Circles denote single values for each experiment. The GluK2-mediated currents of cells treated for 30 minutes (244.7 ± 45.39 pA/pF) or 5 hours with control serum (317± 36.84 pA/pF) were similar to those of untreated cells (246.6±49.40 pA/pF;) and also similar to those of cells treated for 30 minutes with two different patients serum (Patient 1=289.1±39.22 pA/pF; Patient 2=324.9±64.1 pA/pF); p>0.99; n=15 recordings for each group from three independent experiments, Kruskall-Wallis with Dunn's comparison test. However, cells treated for 5 hours with the same two patients serum showed a significant reduction of GluK2-mediated currents compared with the control serum (Patient 1=142.3±45.41 pA/pF, Patient 5=145.8± 23.64 pA/pF *vs.* control (5h)= 317± 36.84 pA/pF); **p=0.0019 and **p=0.006 respectively; three independent experiments and at least n=8 recordings; Kruskall-Wallis with Dunn's comparison test.

Panel C shows that treatment of GluK2-expressing HEK293 cells with patient's serum induce robust internalization of receptors that is visible after 5 hours (red in lower row) but not after 30 minute treatments (upper row). These findings suggest that the reduction of GluK2-mediated currents by patient's serum is due to a reduction of receptors and not to a direct antagonistic (or blocking) effect of the antibody on receptor function. Scale bar = 10 μm.

References

1. Dalmau J, Graus F. Antibody-mediated encephalitis. N Engl J Med 2018;378:840-851.
2. Traynelis SF, Wollmuth LP, McBain CJ, et al. Glutamate receptor ion channels: structure, regulation, and function. Pharmacol Rev 2010;62:405-496.
3. Contractor A, Mulle C, Swanson GT. Kainate receptors coming of age: milestones of two decades of research. Trends Neurosci 2011;34:154-163.
4. Dalmau J, Gleichman AJ, Hughes EG, et al. Anti-NMDA-receptor encephalitis: case series and analysis of the effects of antibodies. Lancet Neurol 2008;7:1091-1098.
5. Lai M, Hughes EG, Peng X, et al. AMPA receptor antibodies in limbic encephalitis alter synaptic receptor location. Ann Neurol 2009;65:424-434.
6. Titulaer MJ, McCracken L, Gabilondo I, et al. Treatment and prognostic factors for long-term outcome in patients with anti-NMDA receptor encephalitis: an observational cohort study. Lancet Neurol 2013;12:157-165.
7. Hoftberger R, A. vS, Leypoldt F, et al. Encephalitis and AMPA receptor antibodies: Novel findings in a case series of 22 patients. Neurology 2015;84:2403-2412.
8. Joubert B, Kerschen P, Zekeridou A, et al. Clinical spectrum of encephalitis associated with antibodies against the alpha-amino-3-hydroxy-5-methyl-4-isoxazolepropionic acid receptor: Case series and review of the literature. JAMA Neurol 2015;72:1163-1169.
9. Hughes EG, Peng X, Gleichman AJ, et al. Cellular and synaptic mechanisms of anti-NMDA receptor encephalitis. J Neurosci 2010;30:5866-5875.
10. Haselmann H, Mannara F, Werner C, et al. Human autoantibodies against the AMPA receptor subunit GluA2 induce receptor reorganization and memory dysfunction. Neuron 2018;100:91-105 e109.
11. Ances BM, Vitaliani R, Taylor RA, et al. Treatment-responsive limbic encephalitis identified by neuropil antibodies: MRI and PET correlates. Brain 2005;128:1764-1777.
12. Landa J, Guasp M, Petit-Pedrol M, et al. Seizure-related 6 homolog like 2 autoimmunity: Neurologic syndrome and antibody effects. Neurol Neuroimmunol Neuroinflamm 2021;8.

13. Dalmau J, Tuzun E, Wu HY, et al. Paraneoplastic anti-N-methyl-D-aspartate receptor encephalitis associated with ovarian teratoma. Ann Neurol 2007;61:25-36.
14. Arino H, Armangue T, Petit-Pedrol M, et al. Anti-LGI1-associated cognitive impairment: Presentation and long-term outcome. Neurology 2016;87:759-765.
15. Sabater L, Gaig C, Gelpi E, et al. A novel non-rapid-eye movement and rapid-eye-movement parasomnia with sleep breathing disorder associated with antibodies to IgLON5: a case series, characterisation of the antigen, and post-mortem study. Lancet Neurol 2014;13:575-586.
16. Planaguma J, Leypoldt F, Mannara F, et al. Human N-methyl D-aspartate receptor antibodies alter memory and behaviour in mice. Brain 2015;138:94-109.
17. Planaguma J, Haselmann H, Mannara F, et al. Ephrin-B2 prevents N-methyl-D-aspartate receptor antibody effects on memory and neuroplasticity. Ann Neurol 2016;80:388-400.
18. Bettler B, Egebjerg J, Sharma G, et al. Cloning of a putative glutamate receptor: a low affinity kainate-binding subunit. Neuron 1992;8:257-265.
19. Egebjerg J, Heinemann SF. Ca2+ permeability of unedited and edited versions of the kainate selective glutamate receptor GluR6. Proc Natl Acad Sci USA 1993;90:755-759.
20. Burnashev N, Villarroel A, Sakmann B. Dimensions and ion selectivity of recombinant AMPA and kainate receptor channels and their dependence on Q/R site residues. J Physiol 1996;496 (Pt 1):165-173.
21. Sommer B, Kohler M, Sprengel R, Seeburg PH. RNA editing in brain controls a determinant of ion flow in glutamate-gated channels. Cell 1991;67:11-19.
22. Pinheiro PS, Mulle C. Presynaptic glutamate receptors: physiological functions and mechanisms of action. Nat Rev Neurosci 2008;9:423-436.
23. Lerma J. Kainate receptor physiology. Curr Opin Pharmacol 2006;6:89-97.
24. Contractor A, Swanson G, Heinemann SF. Kainate receptors are involved in short- and long-term plasticity at mossy fiber synapses in the hippocampus. Neuron 2001;29:209-216.
25. Schmitz D, Mellor J, Breustedt J, Nicoll RA. Presynaptic kainate receptors impart an associative property to hippocampal mossy fiber long-term potentiation. Nat Neurosci 2003;6:1058-1063.
26. Lourenco J, Cannich A, Carta M, Coussen F, Mulle C, Marsicano G. Synaptic activation of kainate receptors gates presynaptic CB(1) signaling at GABAergic synapses. Nat Neurosci 2010;13:197-204.
27. Mikasova L, P. DR, Bouchet D, et al. Disrupted surface cross-talk between NMDA and Ephrin-B2 receptors in anti-NMDA encephalitis. Brain 2012;135:1606-1621.
28. Peng X, Hughes EG, Moscato EH, Parsons TD, Dalmau J, Balice-Gordon RJ. Cellular plasticity induced by anti-alpha-amino-3-hydroxy-5-methyl-4-isoxazolepropionic acid (AMPA) receptor encephalitis antibodies. Ann Neurol 2015;77:381-398.
29. Crisp SJ, Dixon CL, Jacobson L, et al. Glycine receptor autoantibodies disrupt inhibitory neurotransmission. Brain 2019;142:3398-3410.
30. Rauschenberger V, von Wardenburg N, Schaefer N, et al. Glycine receptor autoantibodies impair receptor function and induce motor dysfunction. Ann Neurol 2020;88:544-561.
31. Van Samkar A, Poulsen MNF, Bienfait HP, Van Leeuwen RB. Acute cerebellitis in adults: a case report and review of the literature. BMC Res Notes 2017;10:610.

32. Emelifeonwu JA, Shetty J, Kaliaperumal C, et al. Acute Cerebellitis in Children: A Variable Clinical Entity. J Child Neurol 2018;33:675-684.
33. Shimokaze T, Kato M, Yoshimura Y, Takahashi Y, Hayasaka K. A case of acute cerebellitis accompanied by autoantibodies against glutamate receptor delta2. Brain Dev 2007;29:224-226.
34. Shiihara T, Kato M, Konno A, Takahashi Y, Hayasaka K. Acute cerebellar ataxia and consecutive cerebellitis produced by glutamate receptor delta2 autoantibody. Brain Dev 2007;29:254-256.
35. Kubota M, Takahashi Y. Steroid-responsive chronic cerebellitis with positive glutamate receptor delta 2 antibody. J Child Neurol 2008;23:228-230.
36. Berridge G, Menassa DA, Moloney T, et al. Glutamate receptor delta2 serum antibodies in pediatric opsoclonus myoclonus ataxia syndrome. Neurology 2018;91:e714-e723.
37. Matsumoto H, Okabe S, Hirakawa-Yamada M, et al. Steroid-responsive focal epilepsy with focal dystonia accompanied by glutamate receptor delta2 antibody. J Neuroimmunol 2012;249:101-104.
38. Fukuoka T, Takeda H, Ohe Y, Deguchi I, Takahashi Y, Tanahashi N. Anti-glutamate receptor delta2 antibody-positive migrating focal encephalitis. Clin Neurol Neurosurg 2012;114:1351-1354.
39. Kurian M, Lalive PH, Dalmau JO, Horvath J. Opsoclonus-myoclonus syndrome in anti-N-methyl-D-aspartate receptor encephalitis. Arch Neurol 2010;67:118-121.
40. Armangue T, Sabater L, Torres-Vega E, et al. Clinical and Immunological Features of Opsoclonus-Myoclonus Syndrome in the Era of Neuronal Cell Surface Antibodies. JAMA Neurol 2016;73:417-424.
41. Lancaster E, Lai M, Peng X, et al. Antibodies to the GABA(B) receptor in limbic encephalitis with seizures: case series and characterisation of the antigen. Lancet Neurol 2010;9:67-76.
42. Petit-Pedrol M, Armangue T, Peng X, et al. Encephalitis with refractory seizures, status epilepticus, and antibodies to the GABAA receptor: a case series, characterisation of the antigen, and analysis of the effects of antibodies. Lancet Neurol 2014;13:276-286.

Figure 1

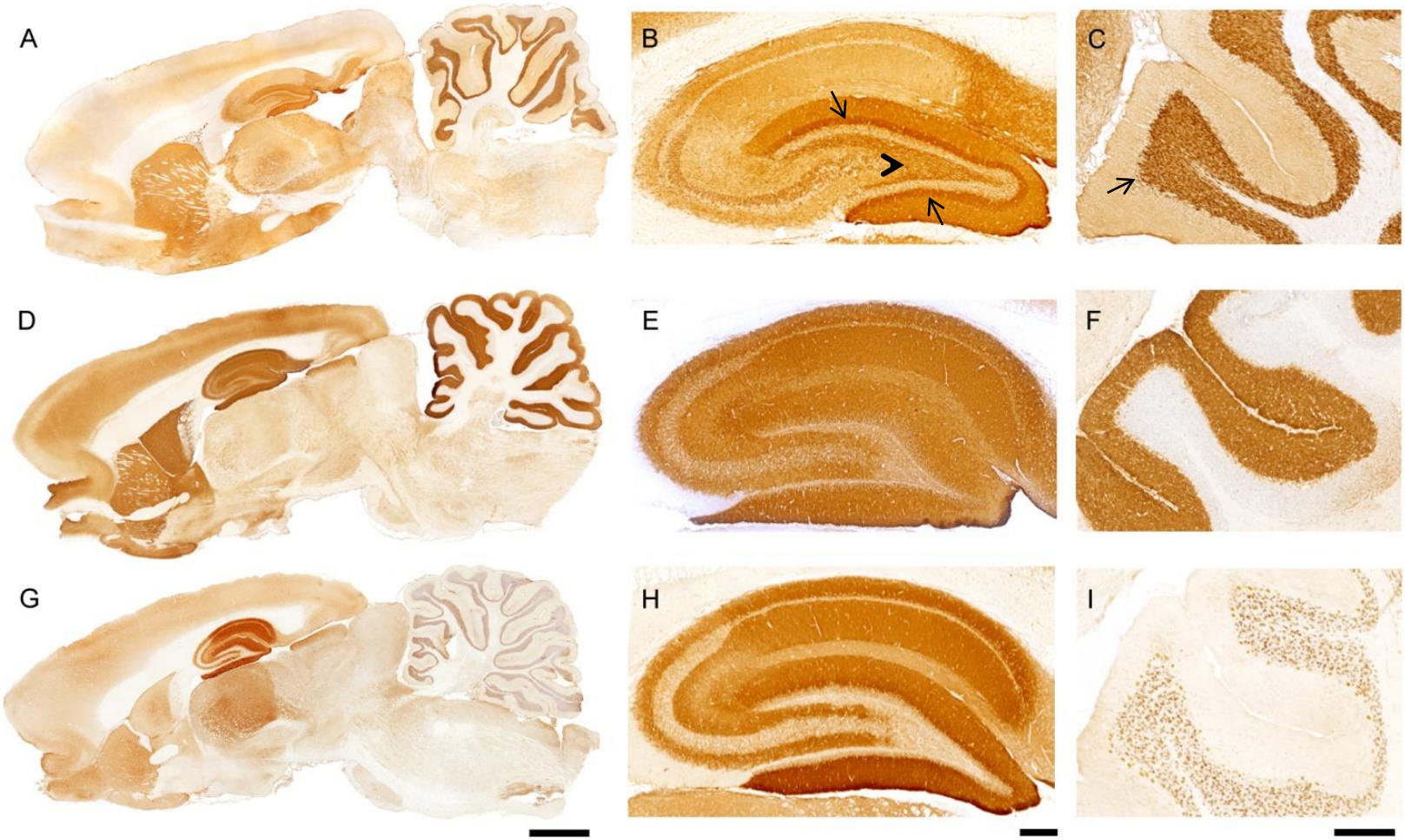

Figure 2

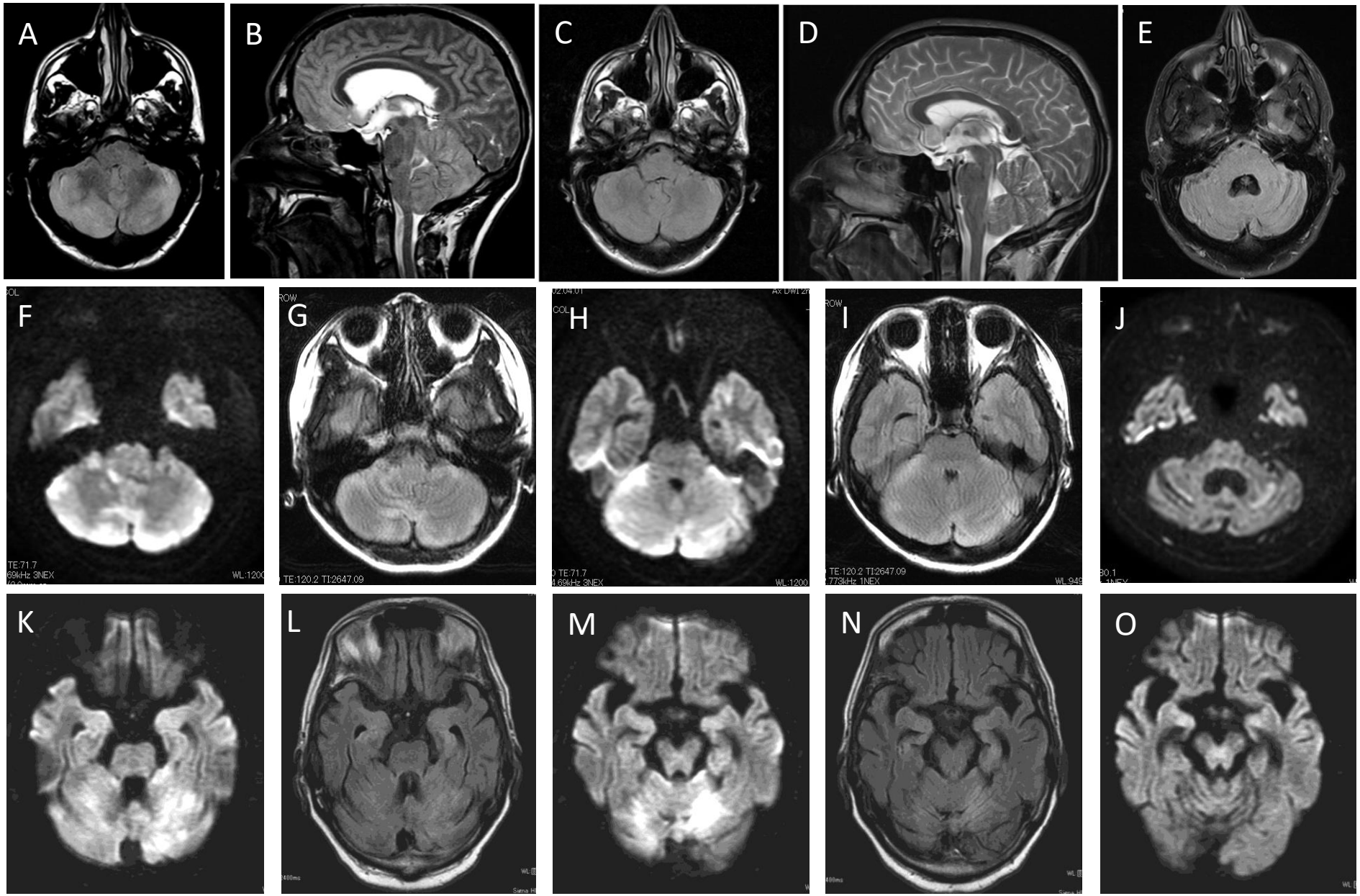

Figure 3

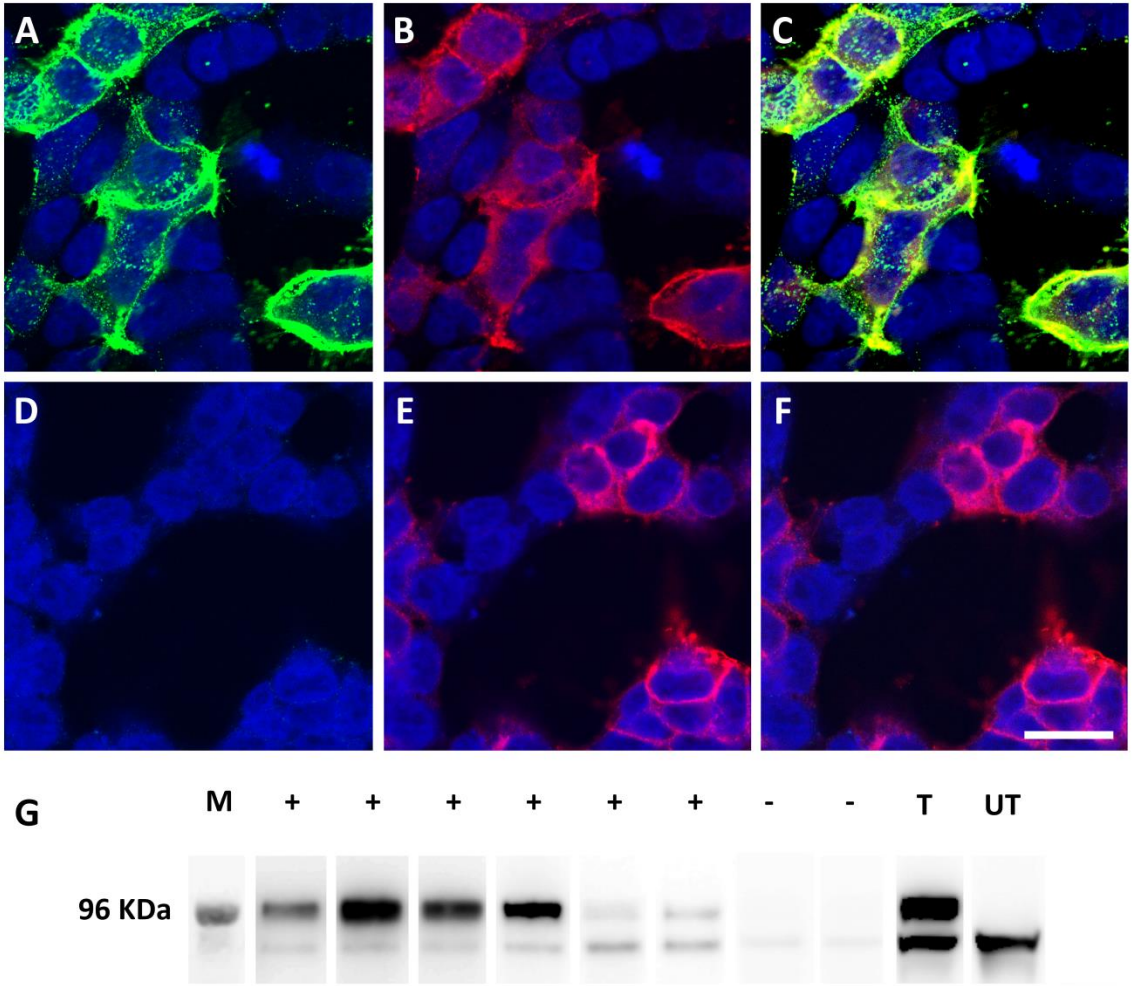

Figure 4

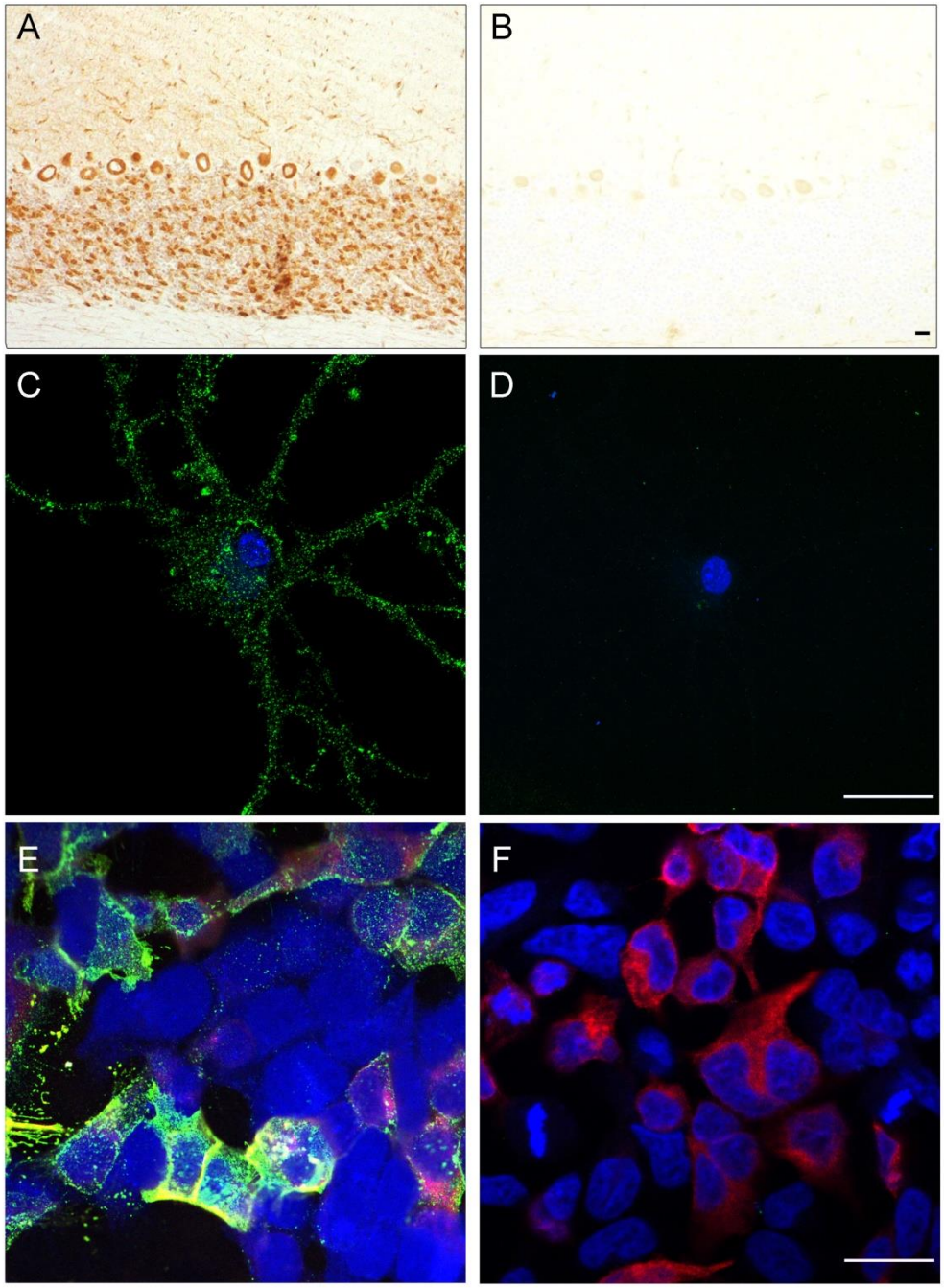

Figure 5

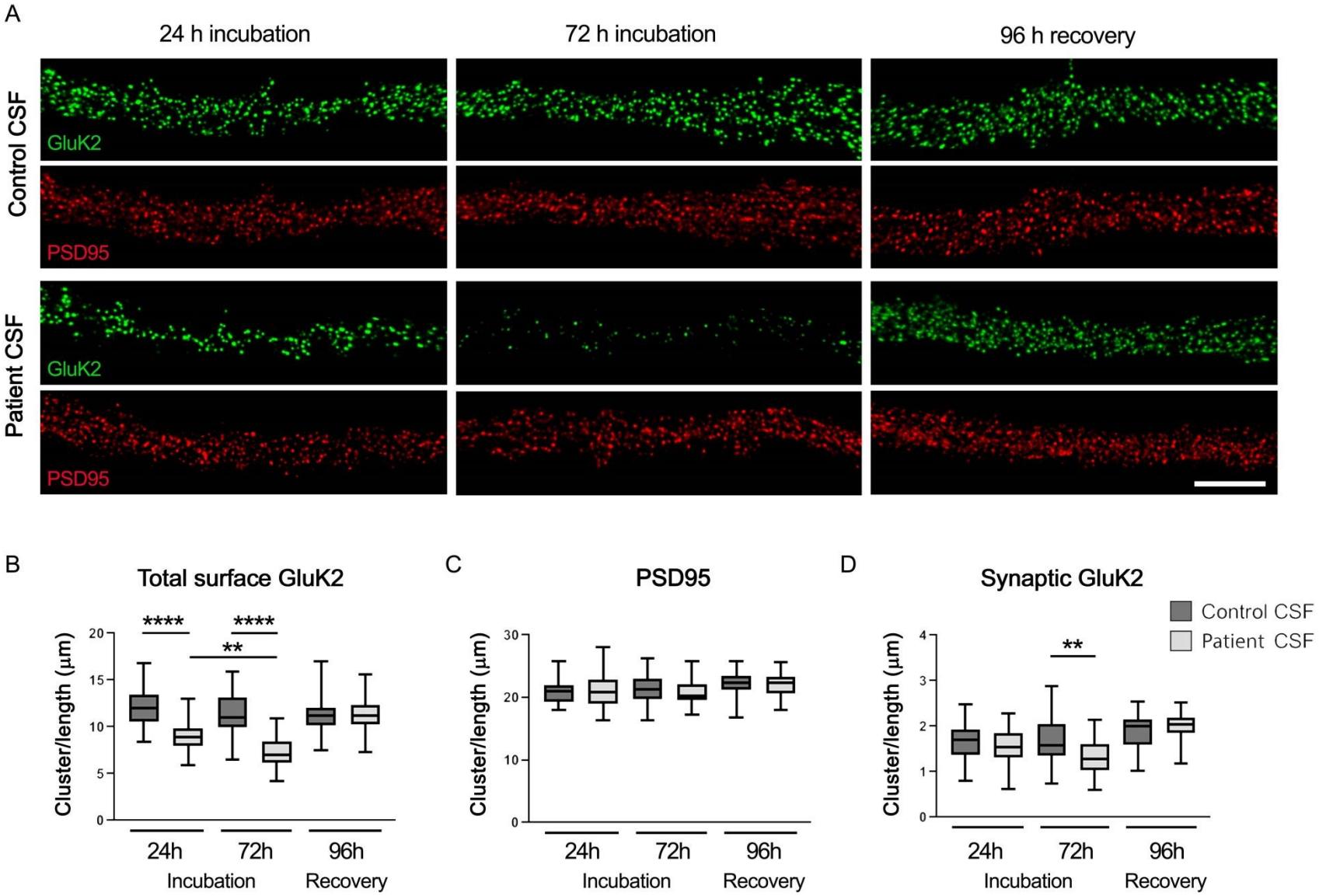
A
24 h incubation
72 h incubation
96 h recovery
Control CSF
Patient CSF
GluK2
PSD95
B
Total surface GluK2
Cluster/length (µm)
****
****
**
24h
72h
96h
Incubation
Recovery
C
PSD95
D
Synaptic GluK2
Control CSF
Patient CSF
**

Figure 6

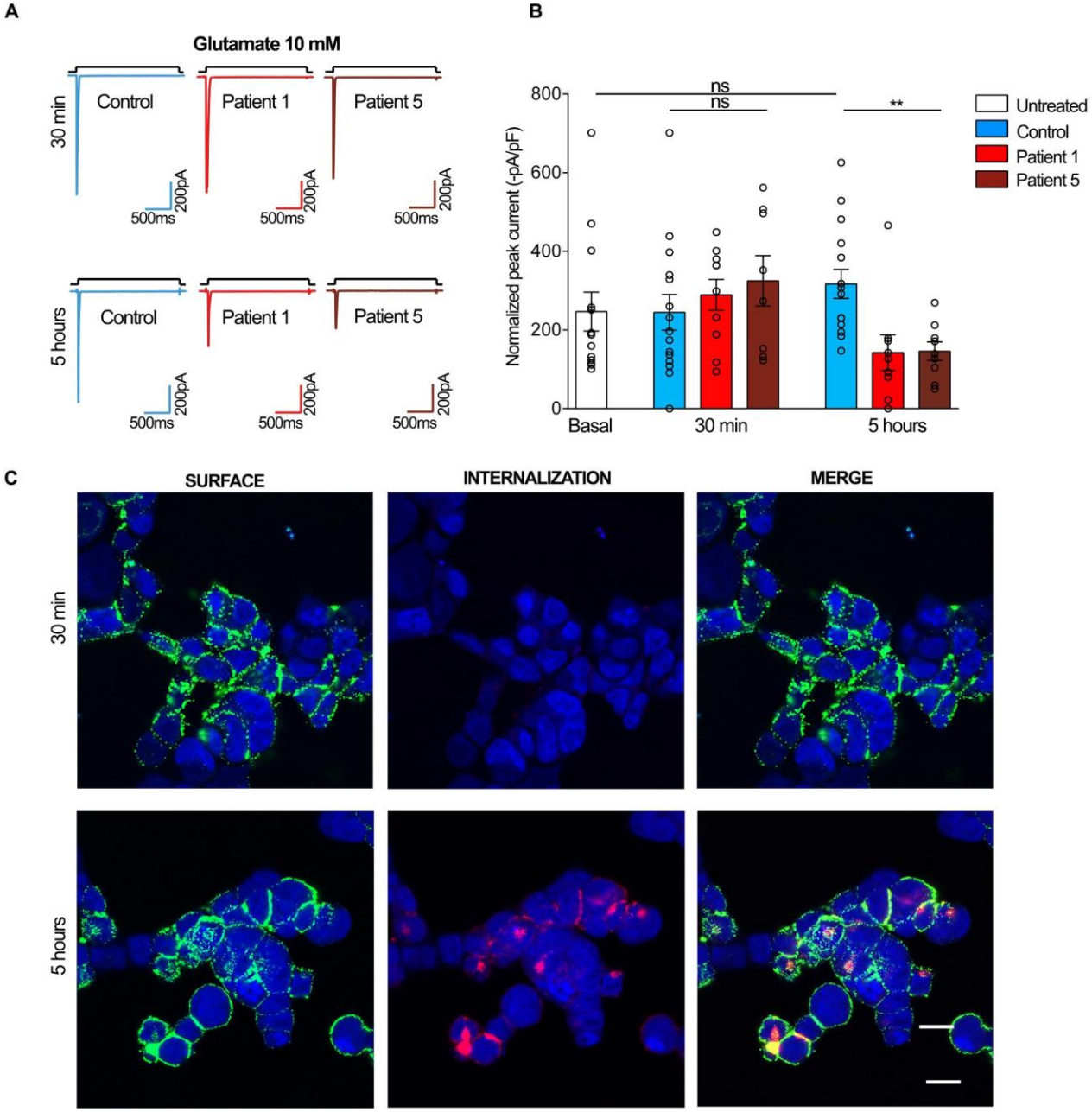
A
Glutamate 10 mM
30 min
Control
Patient 1
Patient 5
200pA
500ms
5 hours
B
Normalized peak current (-pA/pF)
800
600
400
200
0
ns
ns
**
Basal
30 min
5 hours
Untreated
Control
Patient 1
Patient 5
C
SURFACE
INTERNALIZATION
MERGE
30 min
5 hours