

Consensus Statement on Hemostatic Management, Anticoagulation, and Antiplatelet Therapy in Liver Transplantation

Eva Montalvá, MD, PhD,^{1,2} Manuel Rodríguez-Perálvarez, MD, PhD,^{2,3} Annabel Blasi, MD, PhD,⁴ Santiago Bonanad, MD,⁵ Olga Gavín, MD, PhD,⁶ Loreto Hierro, MD,⁷ Laura Lladó, MD, PhD,⁸ Elba Llop, MD, PhD,^{3,9} Juan Carlos Pozo-Laderas, MD, PhD,¹⁰ and Jordi Colmenero, MD, PhD^{2,11}; on behalf of the Spanish Society of Liver Transplantation and the Spanish Society of Thrombosis and Haemostasis*

Abstract. Anticoagulation and antiplatelet therapies are increasingly used in liver transplant (LT) candidates and recipients due to cardiovascular comorbidities, portal vein thrombosis, or to manage posttransplant complications. The implementation of the new direct-acting oral anticoagulants and the recently developed antiplatelet drugs is a great challenge for transplant teams worldwide, as their activity must be monitored and their complications managed, in the absence of robust scientific evidence. In this changing and clinically heterogeneous scenario, the Spanish Society of Liver Transplantation and the Spanish Society of Thrombosis and Haemostasis aimed to achieve consensus regarding the indications, drugs, dosing, and timing of anticoagulation and antiplatelet therapies initiated from the inclusion of the patient on the waiting list to post-LT surveillance. A multidisciplinary group of experts composed by transplant hepatologists, surgeons, hematologists, transplant-specialized anesthesiologists, and intensivists performed a comprehensive review of the literature and identified 21 clinically relevant questions using the patient-intervention-comparison-outcome format. A preliminary list of recommendations was drafted and further validated using a modified Delphi approach by a panel of 24 transplant delegates, each representing a LT institution in Spain. The present consensus statement contains the key recommendations together with the core supporting scientific evidence, which will provide guidance for improved and more homogeneous clinical decision making.

(*Transplantation* 2022;106: 1123–1131).

Received 25 June 2021. Revision received 8 September 2021.

Accepted 18 September 2021.

¹ Department of HPB Surgery and Transplantation, La Fe University Hospital and University of Valencia, Instituto de Investigación Sanitaria de La Fe, Valencia, Spain.

² Centro de Investigación Biomédica en Red de Enfermedades Hepáticas y Digestivas (CIBERehd), Madrid, Spain.

³ Department of Hepatology and Liver Transplantation, Reina Sofía University Hospital, IMIBIC, University of Córdoba, Córdoba, Spain.

⁴ Department of Anesthesiology, Hospital Clínic de Barcelona, IDIBAPS, CIBERehd, Barcelona, Spain.

⁵ Unidad de Hemostasia y Trombosis, Servicio de Hematología, Hospital Universitario i Politècnic La Fe, Valencia, Spain.

⁶ Departamento de Hematología y Hemoterapia, Hospital Clínico Universitario Lozano Blesa, Zaragoza, Spain.

⁷ Department of Liver Transplantation, Hospital Universitario La Paz, Madrid, Spain.

⁸ Liver Transplant Unit, Department of Surgery, Bellvitge University Hospital, IDIBELL, University of Barcelona, Barcelona, Spain.

⁹ Servicio de Aparato Digestivo, Instituto de Investigación Puerta de Hierro-Segovia Arana (IDIPHISA), Madrid, Spain.

¹⁰ Department of Intensive Care Medicine, Reina Sofía University Hospital, IMIBIC, Córdoba, Spain.

¹¹ Department of Hepatology and Liver Transplantation, Hospital Clínic de Barcelona, IDIBAPS, CIBERehd, Barcelona, Spain.

E.M. and M.R.-P. have contributed equally to this article and may be considered cofirst authors.

*The full list of consensus panel delegates is shown in appendix.

E.M., M.R.-P., A.B., S.B., O.G., L.H., L.L., E.L., J.C.P., and J.C. drafted the article and acted as consensus panel coordinators on behalf of the Spanish Society of Liver Transplantation and the Spanish Society of Thrombosis and Haemostasis (full panel listed in appendix).

A.B. has received a lecture fee from Octapharma. The remaining authors declare no conflicts of interest.

The present article is free of any industry sponsorship. The Spanish Society of Liver Transplantation provided the consensus panel members with technical support in order to organize the online consensus meeting.

Supplemental Visual Abstract; <http://links.lww.com/TP/C322>.

Supplemental digital content (SDC) is available for this article. Direct URL citations appear in the printed text, and links to the digital files are provided in the HTML text of this article on the journal's Web site (www.transplantjournal.com).

Correspondence: Manuel Rodríguez-Perálvarez, MD, PhD, Department of Hepatology and Liver Transplantation, Reina Sofía University Hospital, University of Córdoba, Avda/ Menéndez Pidal s/n, 14004 Córdoba, Spain. (ropeml@hotmail.com).

Copyright © 2022 The Author(s). Published by Wolters Kluwer Health, Inc. This is an open-access article distributed under the terms of the Creative Commons Attribution-Non Commercial-No Derivatives License 4.0 (CCBY-NC-ND), where it is permissible to download and share the work provided it is properly cited. The work cannot be changed in any way or used commercially without permission from the journal.

ISSN: 0041-1337/20/1066-1123

DOI: 10.1097/TP.0000000000004014

INTRODUCTION

Anticoagulation or antiplatelet therapy may be required in liver transplant (LT) patients either for prophylactic or therapeutic purposes, and this need will probably increase in the near future as metabolic-associated fatty liver disease becomes one of the leading indications of LT.¹ Indeed, nowadays, both LT donors and candidates are older and have a more adverse cardiovascular risk profile.² In addition, recent surgical advances allow LT to be considered in patients with complex splanchnic vein thrombosis receiving anticoagulants. There is growing interest in evaluating the role of anticoagulation or antiplatelet therapy to prevent graft thrombosis.³ Finally, some vascular complications are initially approached percutaneously, with specific hemostatic requirements.

In parallel to the growing indications of anticoagulation and antiplatelet therapy in the LT setting, the pharmacological armamentarium has become wider with the upcoming of new direct-acting oral anticoagulants, including factor Xa inhibitors (rivaroxaban, apixaban, edoxaban, betrixaban) and the direct thrombin inhibitor dabigatran, and also the recently developed antiplatelet drugs, with which there is limited experience in patients with advanced liver disease or LT. Indeed, the scientific evidence regarding the efficacy and safety of anticoagulation and antiplatelet therapies in the peritransplant setting is scarce and of sub-optimal quality.³ As a result, there is wide heterogeneity in clinical practice.

The Spanish Society of Liver Transplantation and the Spanish Society of Thrombosis and Haemostasis aimed to achieve consensus regarding the indications, drugs, dosing, and timing of anticoagulation and antiplatelet therapies initiated from the inclusion of the patient on the waiting list to post-LT surveillance. In the present document, we summarize the main recommendations and the core supporting scientific evidence facilitating improved and more homogeneous clinical decision making.

MATERIALS AND METHODS

In December 2020, the Spanish Society of Liver Transplantation engaged a multidisciplinary group of experts composed of 2 transplant hepatologists, 2 surgeons, 1 transplant-specialized anesthesiologist, and 1 intensivist. The Spanish Society of Thrombosis and Haemostasis endorsed this initiative and identified 2 expert hematologists who joined the multidisciplinary group. The consensus statement was stratified into 3 sections, each corresponding to a period with inherent peculiarities regarding anticoagulation and antiplatelet therapy: (a) the pretransplant period, which was defined from the inclusion of the patient on the waiting list until the upcoming of a donor; (b) the intraoperative period; and (c) the posttransplant period. Three experts were assigned to each section taking into account their area of expertise and a total of 21 clinically relevant questions were formulated according to the patient-intervention-comparison-outcome (PICO) format.⁴ This questionnaire was distributed among 25 transplant delegates, each of whom represented a LT institution in Spain. The inputs

received allowed the expert panel to identify the most conflicting clinical scenarios and major sources of clinical heterogeneity to delineate the structure of the consensus document.

A modified Delphi approach⁵ was used as summarized in Figure 1. A comprehensive literature search was conducted by the expert panel to identify all relevant articles regarding anticoagulation and antiplatelet therapy in patients with end-stage liver disease or with LT. MEDLINE, Google Scholar, PubMed, the Cochrane Library, and resources of international societies of transplantation and hepatology were searched using the following keywords or equivalent free-text terms: [“cirrhosis” OR “Liver Transplantation”] AND [“anticoagulation” OR “antiaggregant therapy” OR “thrombosis”]. Recent reviews and position statements were hand-searched to retrieve additional relevant studies. A preliminary list of recommendations was issued to address each of the PICO questions. In the first Delphi-like round, the list of recommendations was distributed among the 24 transplant delegates who reviewed the list and provided feedback to implement modifications, which were incorporated to the preliminary article upon approval by the expert multidisciplinary panel. Then, an online interactive consensus meeting was organized including the expert panel and the transplant delegates on February 17 and 18, 2021. Recommendations were reviewed individually, and the level of agreement for each statement was obtained using a real-time voting system. If the agreement among the transplant delegates for a given recommendation was lower than 90%, a debate took place to reassess the recommendation. Only recommendations with an agreement higher than 90% entered the final version of the document, which was distributed among transplant delegates for minor remarks and final approval (second Delphi-like round).

The scientific evidence and strength of recommendations was evaluated using the “Grading of Recommendations Assessment, Development and Evaluation” (GRADE) system,⁶ which rates 2 dimensions: (a) Strength of the recommendation: classified as “1” (if strong) or as “2” (if weak), and (b) Quality of the evidence: classified as “A” (high-quality evidence coming from well-designed randomized trials or overwhelming evidence from other sources), “B” (moderate-quality evidence from randomized trials with methodological limitations or well-designed observational studies), or “C” (low-quality evidence from observational studies or unsystematic clinical experience). Recommendations with more solid scientific background classified as grade 1A or 1B formed part of the main document, while the recommendations based on weaker evidence are provided as **Supplementary Digital Content**, <http://links.lww.com/TP/C321>. The present consensus statement complies with the highest methodological standards according to the Guidelines International Network.⁷ This initiative did not involve patients and was exempt from approval from an ethics’ board.

Pretransplant Period

There is a growing number of medical conditions routinely managed with anticoagulant or antiplatelet

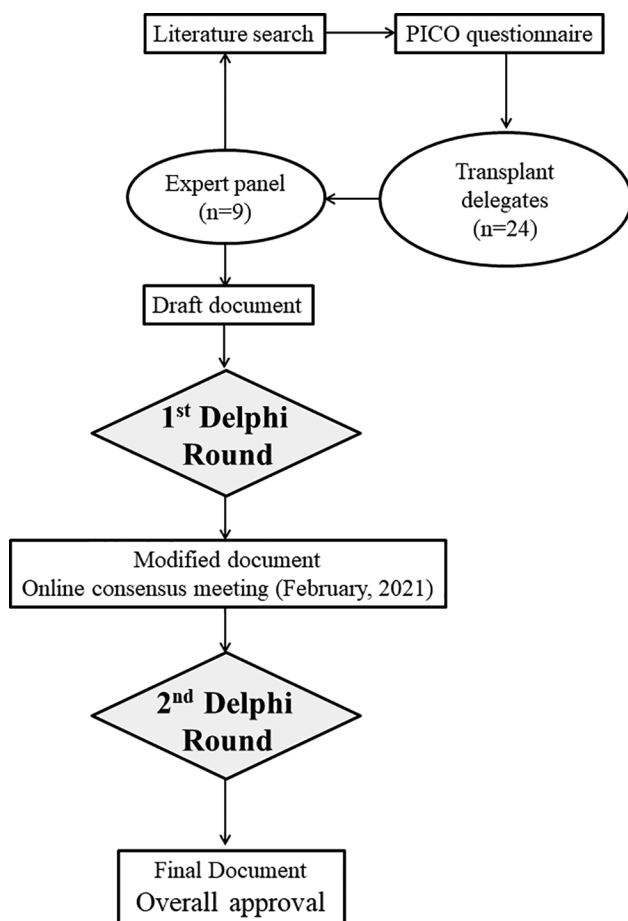


FIGURE 1. Flow chart illustrating the modified Delphi approach to achieve consensus regarding indications of anticoagulation and antiplatelet therapy in patients with end-stage liver disease or liver transplantation. PICO, patient-intervention-comparison-outcome.

therapies in LT candidates, which may be classified as related and unrelated to the liver disease. Although the vast majority of patients with advanced liver disease show severe thrombocytopenia and prolonged prothrombin time, liver cirrhosis is associated with a complex and fragile rebalanced hemostasis,⁸ often complicated with thrombotic events. The most specific liver-related thrombotic events are the Budd-Chiari syndrome, which is an uncommon indication of LT,⁹ and portal vein thrombosis with a prevalence ranging from 5% to 26% of LT candidates.¹⁰ It is paramount to rule out malignant disease underlying both conditions. In patients with Budd-Chiari syndrome, a complete hematological workup is mandatory, while patients with portal vein thrombosis may require dynamic liver imaging techniques (computed tomography or magnetic resonance) reviewed by an expert radiologist within a multidisciplinary team. On the other hand, extrahepatic conditions requiring specific hemostatic management are becoming more frequent due to: older age and more adverse cardiovascular profile of LT candidates,¹¹ particularly among patients with metabolic-associated fatty liver disease,^{2,12} a deeper cardiovascular pretransplant workup,¹³ and recent advances in percutaneous management of coronary artery disease.¹⁴ Indeed, patients with significant coronary stenosis, even with 2 or 3 vessels involved, may safely receive a LT

nowadays if they undergo prior percutaneous stenting, with subsequent double antiplatelet therapy.¹⁵ The prevalence of atrial fibrillation is expected to rise from 7.8% to 9.5% among patients older than 65 y in Europe in the next decades.¹⁶ Other frequent clinical conditions among LT candidates requiring chronic hemostatic management are heart valve replacement, venous thromboembolism, and ischemic stroke, among others.

In parallel, the anticoagulant and antiplatelet therapeutic armamentarium has become wider and there is a paucity of high-quality studies evaluating the safety and efficacy of these drugs in patients with cirrhosis.³ Novel direct oral anticoagulants, which inhibit the active site of thrombin (dabigatran) or coagulation factor Xa (apixaban, betrixaban, edoxaban, and rivaroxaban), offer fixed dose administration, waived routine coagulation monitoring, and reduced bleeding risk, and they are currently the mainstay in nonvalvular atrial fibrillation and venous thromboembolism, including splanchnic vein thrombosis.^{17,18} However, patients with chronic liver disease were systematically excluded from the pivotal randomized trials of these drugs, and thus, data regarding safety and efficacy are lacking in this population.¹⁹ Drug regulatory agencies including the European Medicines Agency and the Food and Drug Administration allow the use of direct oral anticoagulants without restrictions in patients with Child-Pugh class A. In patients with Child-Pugh class B, rivaroxaban and edoxaban are contraindicated, while dabigatran and apixaban may be used with caution. In Child-Pugh C patients, direct oral anticoagulants are associated with a high risk of bleeding events²⁰ and they are contraindicated.² Antiplatelet therapies aim to reduce or slow down platelet aggregation, thus precluding thrombus formation. They are considered more effective than anticoagulants to prevent or treat arterial thrombosis and atherothrombotic events. There is a myriad of antiplatelet drugs classified according to their mechanism of action: inhibition of the enzyme cyclooxygenase (ie, aspirin), P2Y12 receptor blockade (ie, clopidogrel, prasugrel, and ticagrelor), and inhibition of glycoprotein receptor IIb/IIIa (ie, abciximab, tirofiban, and eptifibatide), being the latter group mainly indicated in acute coronary syndrome. Among LT candidates, it is frequent to find indications for aspirin with or without P2Y12 inhibitors in bearers of coronary stents or as secondary prevention of noncardioembolic ischemic stroke.^{21,22} Again, the scientific evidence supporting antiplatelet therapies in patients with advanced liver disease is scarce and their use is considered of high risk, particularly in patients with severe thrombocytopenia.

In this volatile and uncertain context, patients with advanced liver disease may require invasive procedures while awaiting LT such as paracentesis, thoracocentesis, and loco-regional ablative therapies of hepatocellular carcinoma, among others. The correction of coagulation disorders and reversal of anticoagulant and antiplatelet therapies depends on the bleeding risk of each procedure, which may be classified as low or high. Table 1 shows the most frequent procedures performed in patients with cirrhosis in each category.

In summary, an increasing number of LT candidates receive anticoagulant or antiplatelet therapies while on

the waiting list and there are many issues requiring clinical guidance including indications/contraindications, monitoring, and effect reversal in patients requiring invasive procedures. The consensus panel has identified 6 PICO questions containing 18 recommendations, 5 with weak supporting evidence shown in **Supplementary Material, SDC**, <http://links.lww.com/TP/C321>, and 13 supported by strong evidence and summarized later:

- (1) Should patients listed for LT receive specific therapy to correct coagulation disorders before undergoing invasive procedures? (Continued in **Supplementary Material, SDC**, <http://links.lww.com/TP/C321>)
 - (1.1) In procedures with low risk of bleeding (Table 1), prophylactic correction of coagulation disorders is not required²³⁻²⁶ (Recommendation 1B).
 - (1.2) In urgent procedures associated with a high risk of bleeding (Table 1), prophylactic correction of coagulation disorders is recommended if the platelet count is <50 000/ μ L or serum fibrinogen is <1.3 g/L²⁷⁻²⁹ (Recommendation 1B).
 - (1.3) The use of fresh frozen plasma to correct coagulation disorders before an invasive procedure should be discouraged in patients with decompensated liver cirrhosis (Recommendation 1B).²⁷⁻²⁹
- (2) Should patients listed for LT undergo screening of portal vein thrombosis using abdominal imaging techniques?
 - (2.1) The screening of portal vein thrombosis in patients awaiting LT should be performed every 3 mo, alternating Doppler ultrasound with dynamic radiological techniques (angio-computed tomography or angi-magnetic resonance)³⁰⁻³² (Recommendation 1B).
- (3) Should patients at risk of portal vein thrombosis receive thromboprophylaxis while awaiting LT? (Continued in

Supplementary Material, SDC, <http://links.lww.com/TP/C321>)

- (3.1) Workup of thrombophilia cannot be universally recommended although it may prove useful in patients with a family history or analytic suspicion³³ (Recommendation 1A).
- (4) Should patients with portal vein thrombosis receive anticoagulation or other interventions to prevent progression of thrombosis while awaiting LT? (Continued in **Supplementary Material, SDC**, <http://links.lww.com/TP/C321>)
 - (4.1) In patients diagnosed with new onset portal vein thrombosis while awaiting LT, a dynamic liver imaging study (computed tomography or magnetic resonance) should be performed as soon as possible to rule out hepatocellular carcinoma^{34,35} (Recommendation 1A).
 - (4.2) A dynamic imaging study (angio-computed tomography or angio-magnetic resonance) is recommended every 3 mo to evaluate potential progression of thrombosis³⁰⁻³² (Recommendation 1B).
 - (4.3) Anticoagulation should be initiated in all patients with portal vein thrombosis awaiting LT unless otherwise contraindicated^{36,37} and maintained until LT irrespective of thrombus resolution^{36,38,39} (Recommendation 1A).
 - (4.4) Low molecular weight heparin is the first line anticoagulation therapy in this setting⁴⁰ (Recommendation 1C). The dose of low molecular weight heparin should be tailored according to patient weight, renal function, and platelet count, including an individual risk/benefit evaluation (Recommendation 1A).
 - (4.5) Vitamin K antagonists may be considered second-line therapies and their effect can be reverted using vitamin K or prothrombin complex⁴⁰ (Recommendation 1B).
 - (4.6) The indication of transjugular intrahepatic portosystemic shunt in patients with portal vein thrombosis should be evaluated within a multidisciplinary team on a case-by-case basis.⁴¹⁻⁴³ This procedure is contraindicated in patients with Child-Pugh class C (Recommendation 1A).
 - (4.7) The indication of percutaneous thrombolysis in patients with portal vein thrombosis should be evaluated within a multidisciplinary team on a case-by-case basis⁴⁴⁻⁴⁶ (Recommendation 1A).
- (5) Should patients with portal vein thrombosis requiring anticoagulation receive prophylaxis of variceal bleeding?
 - (5.1) Primary or secondary prophylaxis of variceal bleeding (beta-blockers or band ligation) should not be delayed in patients with portal vein thrombosis requiring anticoagulation. If needed, variceal bleeding prophylaxis and anticoagulation can be initiated simultaneously^{28,47} (Recommendation 1A).

TABLE 1.

Most frequent invasive procedures performed in patients with liver cirrhosis according to their risk of bleeding

Low-moderate risk of bleeding procedures

- Thoracentesis
 - Paracentesis
 - Upper gastrointestinal endoscopy with biopsy
 - Colonoscopy with biopsy or polypectomy
 - Superficial percutaneous drainage
 - Phlebotomy
 - Liver biopsy
 - Bronchoscopy with or without biopsy
- High risk of bleeding procedures
- Transarterial chemoembolization
 - Transarterial radioembolization
 - Upper gastrointestinal endoscopy with variceal banding or sclerotherapy.
 - Renal biopsy
 - Dental procedures
 - Intraabdominal abscess drainage
 - Cholecystostomy
 - Transjugular percutaneous portosystemic shunt (TIPS)
 - Transhepatic biliary drainage
 - Percutaneous tumor ablation

Intraoperative Period

Patients with end-stage liver disease admitted for LT require a specific intraoperative anesthetic management.⁴⁸ Anemia, thrombopenia, prolonged prothrombin time, hyperfibrinolysis, and complex rebalanced hemostasis are almost universal, and their reversal is challenging, particularly in cirrhotic patients receiving anticoagulant or

antiplatelet therapies. Although the supporting scientific evidence is generally weak, it seems that optimal hematological perioperative management has a positive impact in short-term outcomes. Indeed, a liberal policy of red blood cell transfusion is associated with increased mortality rates after LT.^{49,50} A restrictive transfusion policy to target hemoglobin levels between 7 g/dL and 8 g/dL in the absence of massive bleeding or structural cardiomyopathy is currently considered the standard of care.⁵¹ Thrombocytopenia certainly increases the risk of bleeding in cirrhotic patients undergoing elective surgery,⁵² although the target threshold to consider platelet transfusion is still a matter of debate. It seems that LT could be safely performed in patients with significant thrombocytopenia, even below 50 000/mm³, without requiring transfusions.⁵³ Coagulation abnormalities has been traditionally reversed with fresh frozen plasma, but recent evidence suggests that this strategy may not be effective,⁵⁴ and could even increase the risk of thromboembolic events in patients with advanced liver disease.⁵⁵

Monitoring hemostasis more closely immediately before and during LT would allow for a more accurate diagnosis and a more rational indication of transfusions. A combination of viscoelastic tests, whenever available, and fibrinogen levels performed at critical intraoperative time points, could add to conventional hematological tests such as prothrombin time, activated partial thromboplastin time, international normalized ratio (INR), and platelet count. Two small randomized trials and several observational single-center studies have reported that viscoelastic test-guided management is able to reduce the need for fresh frozen plasma transfusions, but these were replaced by prothrombin complex and fibrinogen concentrate transfusions as appropriate.⁵⁶ Although further high-quality studies are needed, the European Society of anesthesiology guidelines recommend the use of viscoelastic tests to monitor patients undergoing LT, particularly in cases with severe bleeding.⁵³

Based on the best available evidence, the consensus group has identified 5 PICO questions and have issued key recommendations including critical aspects such as correction of coagulation abnormalities, reversal of anticoagulant and antiplatelet therapies, intraoperative hemostatic monitoring, and blood product intraoperative transfusion. Five PICO questions containing 17 recommendations were included in this section. Seven recommendations with weak supporting evidence are shown in **Supplementary Material, SDC**, <http://links.lww.com/TP/C321>, and 10 recommendations with strong supporting evidence are shown later:

- (1) Should cirrhotic patients admitted to the hospital for LT undergo prophylactic correction of altered standard coagulation tests? (Continued in **Supplementary Material, SDC**, <http://links.lww.com/TP/C321>)
 - (1.1) If thromboelastography is not available, the prophylactic use of tranexamic acid is recommended in patients with Child-Pugh class B or C, unless otherwise contraindicated^{57,58} (Recommendation 1B).
 - (1.2) The prophylactic use of tranexamic acid should be balanced against the risk of thrombosis in the following situations: hypercoagulability, thrombotic events within the previous 6 mo, acute liver failure, grade III-IV portal vein thrombosis and uses of liver

disease associated with increased risk of thrombosis (autoimmune hepatitis, primary sclerosing cholangitis...),^{58,59} (Recommendation 1B).

- (1.3) Therapeutic administration of tranexamic acid should be considered if there is clinical suspicion of fibrinolysis (coagulopathy bleeding with decreasing fibrinogen) or there are compatible changes in the thromboelastography^{58,60} (Recommendation 1B).
- (2) Should patients admitted to the hospital for LT revert the effect of anticoagulant or antiplatelet therapy before surgery? (Continued in **Supplementary Material, SDC**, <http://links.lww.com/TP/C321>)
 - (2.1) In patients receiving vitamin K antagonists with an INR ≤ 3.5 , a single dose of intravenous vitamin K (10 mg) should be administered as soon as possible⁶¹⁻⁶³ since its reversal effect requires time (Recommendation 1C).
 - (2.2) The use of fresh frozen plasma to reverse the activity of vitamin K antagonists before LT should be discouraged^{54,63,64} (Recommendation 1B).
 - (2.3) In patients receiving direct-acting oral anticoagulants, the specific antidote should be administered before surgery whenever available (idarizumab or andexanet-alpha)^{63,65} (Recommendation 1B).
 - (2.4) In patients receiving antiplatelet therapy, with the exception of aspirin, the drug should be withdrawn as soon as possible^{63,66} (Recommendation 1B). Systematic platelet transfusion is not recommended^{63,67} (Recommendation 1B).
- (3) Should patients undergo hemostatic monitoring intraoperatively during LT?
 - (3.1) Thromboelastography is recommended for hemostatic management and can be helpful for transfusion guidance^{48,53,68,69} (Recommendation 1B). Whenever available, thromboelastography should be performed at baseline (after anesthetic induction), within the first 20–30 min after reperfusion, and at surgical wound closure. Additional determinations may also be required if coagulopathic bleeding is observed (ie, diffuse hemorrhage in the absence of macroscopic clots) or after any intraoperative hemostatic intervention⁷⁰ (Recommendation 1B).
- (4) Should patients with intraoperative hemostatic abnormalities receive replacement of coagulation factors or platelets? (Continued in **Supplementary Material, SDC**, <http://links.lww.com/TP/C321>)
 - (4.1) If thromboelastography is available, transfusion should be tailored according to the established algorithms and taking into account the presence of coagulopathic bleeding (Table 2). While normal thromboelastography values are well defined for the general population, normality values in patients with liver cirrhosis may be less strict^{69,71,72} (Recommendation 1B).
 - (4.2) If thromboelastography is not available, transfusion should be tailored to maintain the platelet count $>30\,000/\mu\text{L}$ and fibrinogen $>1\text{g/L}$. In patients with active bleeding, thresholds for platelet count and fibrinogen should be set higher (ie, $>50\,000/\mu\text{L}$ and $>1.3\text{g/L}$, respectively)^{48,73} (Recommendation 1C)

TABLE 2.
Thromboelastography-guided transfusion in liver transplantation

Thromboelastography findings	Clinical interpretation	Therapeutic intervention if diffuse bleeding
Lysis at 30 min < 85%	Hyperfibrinolysis	Tranexamic acid
Maximum clot firmness decreased	Fibrinogen and platelet deficiency	Fibrinogen ^b
Low FIBTEM ^a	Fibrinogen deficiency	Platelet concentrate ^c
Normal FIBTEM ^a	Platelet deficiency	
Clotting time prolonged	Coagulation factor deficiency	Fresh frozen plasma vs coagulation factors concentrate ^c

Coagulation abnormalities may be corrected if there is diffuse bleeding.

^aThromboelastography test which informs about fibrinogen levels.

^bConcentrate of fibrinogen or cryoprecipitates, depending on the availability.

^cDepending on the clinical context.

Posttransplant Period

The immediate postoperative period after LT requires a personalized hemostatic management after a careful balance of the individual risk of bleeding and thrombosis.⁷⁴ Thrombotic events after LT may be classified as systemic, which are associated with perioperative general conditions and rebalanced hemostasis, and related to the liver graft, which are strongly influenced by the surgical technique and anatomic variants of donor and recipients. Other external factors may modulate the thrombotic risk, including hydration status, immobilization, cytomegalovirus infection previous transfusions, or administration of prothrombotic agents.⁷⁵ Noteworthy, the use of mammalian target of rapamycin inhibitors early after LT, particularly sirolimus, was associated with increased risk of hepatic artery thrombosis in a single randomized trial,⁷⁶ thus motivating a warning issued by the Food And Drug Administration, and their authorization only beyond day 30 after LT.

The prognostic impact of thrombotic events early after LT is critical. Hepatic artery thrombosis may occur in 3% to 5% of adult patients, usually within the first week after LT, and provokes a rapid deterioration of graft function, thus motivating urgent retransplantation in most cases.⁷⁴ Late hepatic artery stenosis or thrombosis is infrequent but can lead to diffuse ischemic cholangiopathy. The incidence of portal vein thrombosis is approximately 2% of LT patients and may require surgery or even retransplantation.⁷⁴ Therefore, it is paramount to implement screening strategies to promptly detect these complications and to consider the use of preventive anticoagulant or antiplatelet therapies in patients with known risk factors of portal vein thrombosis (Table 3) or hepatic artery thrombosis (Table 4), respectively. In addition, patients receiving anticoagulant or antiplatelet therapies before LT may need to resume these therapies in a timely manner depending on their original indication.

In this section, the consensus panel has identified 10 PICO questions, and have issued 33 key recommendations to provide guidance on screening and treatment of graft-related vascular complications, management of bleeding, and indications of anticoagulant and antiplatelet

TABLE 3.
Risk factors of portal vein thrombosis

Risk factors before liver transplantation

- Low platelet count (<70 000/mm³).
- History of variceal bleeding.
- Hepatofugal portal flow or slow portal flow (<15 cm/s) on Doppler ultrasound.
- Thrombophilic disorders in the recipient

Risk factors after liver transplantation

- History of portal vein thrombosis before liver transplantation.
- Slow portal flow (after reperfusion) defined as <1300 mL/min or < 65 mL/min/100g.
- Partial thrombectomy or vein intimal layer lesion during thrombectomy
- Nonphysiological portal vein inflow reconstruction
- Thrombophilic disorders in the recipient

therapies after LT either with prophylactic or therapeutic purposes, including indications as adjuvant therapies after surgical or radiological procedures. Twenty-two recommendations with weak supporting evidence are shown in **Supplementary Material, SDC**, <http://links.lww.com/TP/C321>, and 11 recommendations with strong scientific evidence are shown later:

- (1) Should patients undergo screening of vascular complications of the liver graft immediately after transplantation?
 - (1.1) Screening of liver graft vascular complications after transplantation is mandatory. A Doppler ultrasound should be performed by a trained specialist within the first 24h after surgery and at any time point afterwards if there is graft dysfunction or an otherwise unexplained alteration of blood liver tests⁷⁷⁻⁷⁹ (Recommendation 1B).
 - (1.2) Hemostatic surveillance with routine coagulation tests is sufficient for most patients after LT. However, in critically ill patients with surgical complications, the use of thromboelastography could be helpful⁸⁰ (Recommendation 1B).
- (2) Should patients receive thromboprophylaxis after LT to prevent venous thromboembolism? (Continued in **Supplementary Material, SDC**, <http://links.lww.com/TP/C321>)
 - (2.1) Perioperative venous thromboembolism prophylaxis with early walking and compression devices

TABLE 4.
Risk factors of hepatic artery thrombosis

- Complex anastomosis (reduced artery diameter, discordant diameters between arteries of donor and recipient).
- Bench arterial reconstruction/use of vascular grafts.
- Arterial flow < 100 mL/min (after inflow modulation).
- Endothelial injury or thrombectomy.
- Reoperation including hepatic artery anastomosis reconstruction.
- Prolonged cold ischemia/operative times.
- Increased blood transfusion requirements.
- Old donor (>70 y old) with atheromatosis.
- Thrombophilia condition of the recipient.
- Familial amyloid polyneuropathy.

is universally recommended⁸¹⁻⁸⁴ (Recommendation 1A).

- (2.2) Pharmacological thromboprophylaxis should be prolonged between 10 and 24 d after hospital discharge according to the individual risk of thrombosis in each patient^{82,83,85,86} (Recommendation 1B).
- (3) Should patients receive specific therapy to correct altered coagulation tests immediately after LT?
- (3.1) In the absence of active bleeding, an increased INR or a reduced platelet count may not require any hemostatic intervention, not even before procedures associated with low risk of bleeding^{28,29,66} (Recommendation 1B).
- (3.2) The universal prescription of vitamin K after LT does not provide any clinical benefit. However, it can be considered in patients with chronic cholestasis or malabsorptive conditions. The initial intravenous dose in such cases would be 10mg every other day⁸⁷ (Recommendation 1B).
- (4) Should patients receive specific therapy to prevent portal vein or hepatic vein thrombosis after LT? (Continued in **Supplementary Material, SDC**, <http://links.lww.com/TP/C321>).
- (4.1) In the absence of coagulopathy, liver graft dysfunction or low platelet count (<30 000–50 000/ μ L), patients with risk factors of portal vein thrombosis (Table 2 from the main document) should receive therapeutic low molecular weight heparin (ie, 1 mg/kg) started within the first 24h after surgery^{88,89} (Recommendation 1B).
- (5) Should patients with postoperative bleeding receive replacement of coagulation factors or platelets to facilitate hemostasis?
- (5.1) Whole blood transfusion should aim to maintain hemoglobin around 8g/dL. Platelets should be maintained at >50 000/ μ L and serum fibrinogen >1.3g/L^{90,91} (Recommendation 1B).
- (5.2) Identification and correction of the cause of bleeding is paramount and massive transfusion should be discouraged, as it is associated with increased mortality^{92,93} (Recommendation 1B).
- (6) Should patients with pretransplant anticoagulation resume this therapy after LT?
- (6.1) In patients at high risk of thrombosis, anticoagulant therapy should be resumed within the first 24 h after LT using the same drug whenever possible. Bridging therapy with low molecular weight heparin can alternatively be considered^{81,94-96} (Recommendation 1B).
- (6.2) In patients at intermediate or low risk of thrombosis, anticoagulant therapy can be delayed 48–72 h after LT without bridging therapy with low molecular weight heparin^{81,94-96} (Recommendation 1B).

CONCLUSIONS

The present multidisciplinary consensus statement addresses 21 clinically relevant PICO questions with key recommendations to allow more objective and homogeneous clinical decision making regarding the use of anticoagulant and antiplatelet therapies in patients with advanced

liver disease before and after LT. Although agreement among the members of the expert panel was high for all recommendations, the quality of the evidence was moderate or low on average, thus highlighting the need for randomized controlled trials focused on patients with cirrhosis and LT receiving antiplatelet or anticoagulant therapies.

ACKNOWLEDGMENTS

The consensus group greatly appreciates the continuous support of Paloma Bellés from AOPC for her contribution to secretariat and logistic aspects. We also acknowledge Ms. Donna Pringle for professional English language polishing.

REFERENCES

1. Younossi ZM, Stepanova M, Ong J, et al. Nonalcoholic steatohepatitis is the most rapidly increasing indication for liver transplantation in the united states. *Clin Gastroenterol Hepatol*. 2021;19:580.e5–589.e5.
2. Ballestri S, Capitelli M, Fontana MC, et al. Direct oral anticoagulants in patients with liver disease in the era of non-alcoholic fatty liver disease global epidemic: a narrative review. *Adv Ther*. 2020;37:1910–1932.
3. Surianarayanan V, Hoather TJ, Tingle SJ, et al. Interventions for preventing thrombosis in solid organ transplant recipients. *Cochrane Database Syst Rev*. 2021;3:CD011557.
4. Centre for Evidence-Based Medicine. *Asking focused questions*. Available at <https://www.cebm.net/2014/06/asking-focused-questions/>. Accessed August 10, 2021.
5. Jones J, Hunter D. Consensus methods for medical and health services research. *BMJ*. 1995;311:376–380.
6. Guyatt GH, Oxman AD, Kunz R, et al; GRADE Working Group. Going from evidence to recommendations. *BMJ*. 2008;336:1049–1051.
7. Qaseem A, Forland F, Macbeth F, et al; Board of Trustees of the Guidelines International Network. Guidelines International Network: toward international standards for clinical practice guidelines. *Ann Intern Med*. 2012;156:525–531.
8. Zermatten MG, Fraga M, Moradpour D, et al. Hemostatic alterations in patients with cirrhosis: from primary hemostasis to fibrinolysis. *Hepatology*. 2020;71:2135–2148.
9. Adam R, Karam V, Delvart V, et al. All contributing centers (www.eltr.org); European Liver and Intestine Transplant Association (ELITA). Evolution of indications and results of liver transplantation in Europe. A report from the European Liver Transplant Registry (ELTR). *J Hepatol*. 2012;57:675–688.
10. Bhangui P, Lim C, Levesque E, et al. Novel classification of non-malignant portal vein thrombosis: a guide to surgical decision-making during liver transplantation. *J Hepatol*. 2019;71:1038–1050.
11. Aghaolour B, VanWagner LB. Cardiac and pulmonary vascular risk stratification in liver transplantation. *Clin Liver Dis*. 2021;25:157–177.
12. Tsochatzis E, Coilly A, Nadalin S, et al. International liver transplantation consensus statement on end-stage liver disease due to non-alcoholic steatohepatitis and liver transplantation. *Transplantation*. 2019;103:45–56.
13. Malhi H, Allen AM, Watt KD. Nonalcoholic fatty liver: optimizing pre-transplant selection and posttransplant care to maximize survival. *Curr Opin Organ Transplant*. 2016;21:99–106.
14. Hoole SP, Bambrough P. Recent advances in percutaneous coronary intervention. *Heart*. 2020;106:1380–1386.
15. Satapathy SK, Vanatta JM, Helmick RA, et al. Outcome of liver transplant recipients with revascularized coronary artery disease: a comparative analysis with and without cardiovascular risk factors. *Transplantation*. 2017;101:793–803.
16. Di Carlo A, Bellino L, Consoli D, et al; National Research Program: Progetto FAI. La Fibrillazione Atriale in Italia. Prevalence of atrial fibrillation in the Italian elderly population and projections from 2020 to 2060 for Italy and the European Union: the FAI Project. *Europace*. 2019;21:1468–1475.
17. Di Nisio M, Valeriani E, Riva N, et al. Anticoagulant therapy for splanchic vein thrombosis: ISTH SSC Subcommittee Control of Anticoagulation. *J Thromb Haemost*. 2020;18:1562–1568.
18. Fredenburgh JC, Weitz JI. New anticoagulants: Moving beyond the direct oral anticoagulants. *J Thromb Haemost*. 2021;19:20–29.

19. Qamar A, Vaduganathan M, Greenberger NJ, et al. Oral anticoagulation in patients with liver disease. *J Am Coll Cardiol*. 2018;71:2162–2175.
20. Semmler G, Ponej K, Bauer DJM, et al. Safety of direct oral anticoagulants in patients with advanced liver disease. *Liver Int*. 2021;41:2159–2170.
21. Kamran H, Jneid H, Kayani WT, et al. Oral antiplatelet therapy after acute coronary syndrome: a review. *JAMA*. 2021;325:1545–1555.
22. De Luca L, Bellettini E, Di Maio D, et al. Oral antiplatelet therapy for secondary prevention of non-cardioembolic ischemic cerebrovascular events. *J Clin Med*. 2021;10:1721.
23. Giannini EG, Greco A, Marengo S, et al. Incidence of bleeding following invasive procedures in patients with thrombocytopenia and advanced liver disease. *Clin Gastroenterol Hepatol*. 2010;8:899–902; quiz e109.
24. Spyropoulos AC, Brohi K, Caprini J, et al; SSC Subcommittee on Perioperative and Critical Care Thrombosis and Haemostasis of the International Society on Thrombosis and Haemostasis. Scientific and Standardization Committee Communication: Guidance document on the periprocedural management of patients on chronic oral anticoagulant therapy: recommendations for standardized reporting of procedural/surgical bleed risk and patient-specific thromboembolic risk. *J Thromb Haemost*. 2019;17:1966–1972.
25. De Gottardi A, Thévenot T, Spahr L, et al. Risk of complications after abdominal paracentesis in cirrhotic patients: a prospective study. *Clin Gastroenterol Hepatol*. 2009;7:906–909.
26. Seeff LB, Everson GT, Morgan TR, et al; HALT-C Trial Group. Complication rate of percutaneous liver biopsies among persons with advanced chronic liver disease in the HALT-C trial. *Clin Gastroenterol Hepatol*. 2010;8:877–883.
27. O’Leary JG, Greenberg CS, Patton HM, et al. AGA clinical practice update: coagulation in cirrhosis. *Gastroenterology*. 2019;157:34.e1–43.e1.
28. Intagliata NM, Argo CK, Stine JG, et al; faculty of the 7th International Coagulation in Liver Disease. Concepts and controversies in haemostasis and thrombosis associated with liver disease: proceedings of the 7th international coagulation in liver disease conference. *Thromb Haemost*. 2018;118:1491–1506.
29. Northup PG, Garcia-Pagan JC, Garcia-Tsao G, et al. Vascular liver disorders, portal vein thrombosis, and procedural bleeding in patients with liver disease: 2020 practice guidance by the american association for the study of liver diseases. *Hepatology*. 2021;73:366–413.
30. Stine JG, Shah NL, Argo CK, et al. Increased risk of portal vein thrombosis in patients with cirrhosis due to nonalcoholic steatohepatitis. *Liver Transpl*. 2015;21:1016–1021.
31. Englesbe MJ, Schaubel DE, Cai S, et al. Portal vein thrombosis and liver transplant survival benefit. *Liver Transpl*. 2010;16:999–1005.
32. Stine JG, Pelletier SJ, Schmitt TM, et al. Pre-transplant portal vein thrombosis is an independent risk factor for graft loss due to hepatic artery thrombosis in liver transplant recipients. *HPB (Oxford)*. 2016;18:279–286.
33. Ma SD, Wang J, Bezinover D, et al. Inherited thrombophilia and portal vein thrombosis in cirrhosis: a systematic review and meta-analysis. *Res Pract Thromb Haemost*. 2019;3:658–667.
34. Sandrasegaran K, Tahir B, Nutakki K, et al. Usefulness of conventional MRI sequences and diffusion-weighted imaging in differentiating malignant from benign portal vein thrombus in cirrhotic patients. *AJR Am J Roentgenol*. 2013;201:1211–1219.
35. Tublin ME, Dodd GD III, Baron RL. Benign and malignant portal vein thrombosis: differentiation by CT characteristics. *AJR Am J Roentgenol*. 1997;168:719–723.
36. Loffredo L, Pastori D, Farcomeni A, et al. Effects of anticoagulants in patients with cirrhosis and portal vein thrombosis: a systematic review and meta-analysis. *Gastroenterology*. 2017;153:480.e1–487.e1.
37. Francoz C, Belghiti J, Vilgrain V, et al. Splanchnic vein thrombosis in candidates for liver transplantation: usefulness of screening and anticoagulation. *Gut*. 2005;54:691–697.
38. de Franchis R; Baveno VI Faculty. Expanding consensus in portal hypertension: Report of the Baveno VI Consensus Workshop: stratifying risk and individualizing care for portal hypertension. *J Hepatol*. 2015;63:743–752.
39. Pettinari I, Vukotic R, Stefanescu H, et al; BO-LIVES (BOlogna LIVEr vascular Studies). Clinical Impact and safety of anticoagulants for portal vein thrombosis in cirrhosis. *Am J Gastroenterol*. 2019;114:258–266.
40. Turon F, Hernández-Gea V, García-Pagán JC. Portal vein thrombosis: yes or no on anticoagulation therapy. *Curr Opin Organ Transplant*. 2018;23:250–256.
41. Rosenqvist K, Eriksson LG, Rorsman F, et al. Endovascular treatment of acute and chronic portal vein thrombosis in patients with cirrhotic and non-cirrhotic liver. *Acta Radiol*. 2016;57:572–579.
42. Salem R, Vouche M, Baker T, et al. Pretransplant portal vein recanalization and transjugular intrahepatic portosystemic shunt in patients with complete obliterative portal vein thrombosis. *Transplantation*. 2015;99:2347–2355.
43. Thornburg B, Desai K, Hickey R, et al. Pretransplantation portal vein recanalization and transjugular intrahepatic portosystemic shunt creation for chronic portal vein thrombosis: final analysis of a 61-patient cohort. *J Vasc Interv Radiol*. 2017;28:1714.e2–1721.e2.
44. Hollingshead M, Burke CT, Mauro MA, et al. Transcatheter thrombolytic therapy for acute mesenteric and portal vein thrombosis. *J Vasc Interv Radiol*. 2005;16:651–661.
45. Smalberg JH, Spaander MV, Jie KS, et al. Risks and benefits of transcatheter thrombolytic therapy in patients with splanchnic venous thrombosis. *Thromb Haemost*. 2008;100:1084–1088.
46. Liu K, Li WD, Du XL, et al. Comparison of systemic thrombolysis versus indirect thrombolysis via the superior mesenteric artery in patients with acute portal vein thrombosis. *Ann Vasc Surg*. 2017;39:264–269.
47. Cerini F, Gonzalez JM, Torres F, et al. Impact of anticoagulation on upper-gastrointestinal bleeding in cirrhosis. A retrospective multicenter study. *Hepatology*. 2015;62:575–583.
48. Biancofiore G, Blasi A, De Boer MT, et al. Perioperative hemostatic management in the cirrhotic patient: a position paper on behalf of the Liver Intensive Care Group of Europe (LICAGE). *Minerva Anesthesiol*. 2019;85:782–798.
49. Han S, Kwon JH, Jung SH, et al. Perioperative fresh red blood cell transfusion may negatively affect recipient survival after liver transplantation. *Ann Surg*. 2018;267:346–351.
50. Rana A, Petrowsky H, Hong JC, et al. Blood transfusion requirement during liver transplantation is an important risk factor for mortality. *J Am Coll Surg*. 2013;216:902–907.
51. Franchini M, Marano G, Mengoli C, et al. Red blood cell transfusion policy: a critical literature review. *Blood Transfus*. 2017;15:307–317.
52. Abbas N, Makker J, Abbas H, et al. Perioperative care of patients with liver cirrhosis: a review. *Health Serv Insights*. 2017;10:1178632917691270.
53. Kozek-Langenecker SA, Ahmed AB, Afshari A, et al. Management of severe perioperative bleeding: guidelines from the European Society of Anaesthesiology: First update 2016. *Eur J Anaesthesiol*. 2017;34:332–395.
54. Huber J, Stanworth SJ, Doree C, et al. Prophylactic plasma transfusion for patients without inherited bleeding disorders or anticoagulant use undergoing non-cardiac surgery or invasive procedures. *Cochrane Database Syst Rev*. 2019;11:CD012745.
55. Tischendorf M, Fuchs A, Zeuzem S, et al. Use of prothrombin complex concentrates in patients with decompensated liver cirrhosis is associated with thromboembolic events. *J Hepatol*. 2019;70:800–801.
56. Sakai T. Viscoelastic testing in liver transplantation. *Transfusion*. 2020;60 (Suppl 6):S61–S69.
57. Dalmau A, Sabaté A, Acosta F, et al. Tranexamic acid reduces red cell transfusion better than epsilon-aminocaproic acid or placebo in liver transplantation. *Anesth Analg*. 2000;91:29–34.
58. Molenaar IQ, Warnaar N, Groen H, et al. Efficacy and safety of antifibrinolytic drugs in liver transplantation: a systematic review and meta-analysis. *Am J Transplant*. 2007;7:185–194.
59. Myles PS, Smith J, Knight J, et al; ATACAS Trial Group. Aspirin and Tranexamic Acid for Coronary Artery Surgery (ATACAS) Trial: rationale and design. *Am Heart J*. 2008;155:224–230.
60. Raza I, Davenport R, Rourke C, et al. The incidence and magnitude of fibrinolytic activation in trauma patients. *J Thromb Haemost*. 2013;11:307–314.
61. Douketis JD, Berger PB, Dunn AS, et al. The perioperative management of antithrombotic therapy: American College of Chest Physicians Evidence-Based Clinical Practice Guidelines (8th Edition). *Chest*. 2008;133:299S–339S.
62. Saja MF, Abdo AA, Sanai FM, et al. The coagulopathy of liver disease: does vitamin K help? *Blood Coagul Fibrinolysis*. 2013;24:10–17.
63. Ageno W, Gallus AS, Wittkowsky A, et al. Oral anticoagulant therapy: antithrombotic therapy and prevention of thrombosis, 9th ed: American College of Chest Physicians Evidence-Based Clinical Practice Guidelines. *Chest*. 2012;141:e44S–e88S.
64. Kwon JO, MacLaren R. Comparison of fresh-frozen plasma, four-factor prothrombin complex concentrates, and recombinant factor via to facilitate procedures in critically ill patients with coagulopathy from liver disease: a Retrospective Cohort Study. *Pharmacotherapy*. 2016;36:1047–1054.

65. Cuker A, Burnett A, Triller D, et al. Reversal of direct oral anticoagulants: Guidance from the Anticoagulation Forum. *Am J Hematol*. 2019;94:697–709.
66. Veitch AM, Vanbiervliet G, Gershlick AH, et al. Endoscopy in patients on antiplatelet or anticoagulant therapy, including direct oral anticoagulants: British Society of Gastroenterology (BSG) and European Society of Gastrointestinal Endoscopy (ESGE) guidelines. *Endoscopy*. 2016;48:385–402.
67. Sierra P, Gómez-Luque A, Llau JV, et al. Recommendations for perioperative antiplatelet treatment in non-cardiac surgery. Working Group of the Spanish Society of Anaesthesiology-Resuscitation and Pain Therapy, Division of Haemostasis, Transfusion Medicine, and Perioperative Fluid Therapy. Update of the Clinical practice guide 2018. *Rev Esp Anestesiol Reanim (Engl Ed)*. 2019;66:18–36.
68. Smart L, Mumtaz K, Scharpf D, et al. Rotational thromboelastometry or conventional coagulation tests in liver transplantation: comparing blood loss, transfusions, and cost. *Ann Hepatol*. 2017;16:916–923.
69. De Pietri L, Bianchini M, Rompianesi G, et al. Thromboelastographic reference ranges for a cirrhotic patient population undergoing liver transplantation. *World J Transplant*. 2016;6:583–593.
70. Donohue CI, Mallett SV. Reducing transfusion requirements in liver transplantation. *World J Transplant*. 2015;5:165–182.
71. Görlinger K, Pérez-Ferrer A, Dirkmann D, et al. The role of evidence-based algorithms for rotational thromboelastometry-guided bleeding management. *Korean J Anesthesiol*. 2019;72:297–322.
72. Wang SC, Lin HT, Chang KY, et al. Use of higher thromboelastogram transfusion values is not associated with greater blood loss in liver transplant surgery. *Liver Transpl*. 2012;18:1254–1258.
73. Bezinover D, Dirkmann D, Findlay J, et al. Perioperative coagulation management in liver transplant recipients. *Transplantation*. 2018;102:578–592.
74. Duffy JP, Hong JC, Farmer DG, et al. Vascular complications of orthotopic liver transplantation: experience in more than 4,200 patients. *J Am Coll Surg*. 2009;208:896–903; discussion 903.
75. Pastacaldi S, Teixeira R, Montalto P, et al. Hepatic artery thrombosis after orthotopic liver transplantation: a review of nonsurgical causes. *Liver Transpl*. 2001;7:75–81.
76. Asrani SK, Wiesner RH, Trotter JF, et al. De novo sirolimus and reduced-dose tacrolimus versus standard-dose tacrolimus after liver transplantation: the 2000–2003 phase II prospective randomized trial. *Am J Transplant*. 2014;14:356–366.
77. Ghadimi K, Levy JH, Welsby JI. Perioperative management of the bleeding patient. *Br J Anaesth*. 2016;117(Suppl 3):iii18–iii30.
78. Ghabril M, Agarwal S, Lacerda M, et al. Portal vein thrombosis is a risk factor for poor early outcomes after liver transplantation: analysis of risk factors and outcomes for portal vein thrombosis in waitlisted Patients. *Transplantation*. 2016;100:126–133.
79. Mourad MM, Lioussis C, Gunson BK, et al. Etiology and management of hepatic artery thrombosis after adult liver transplantation. *Liver Transpl*. 2014;20:713–723.
80. Graff JT, Cortez AR, Dhar VK, et al. Perioperative thrombelastography serves as an important assessment tool of transfusion requirements during liver transplantation. *Surg Open Sci*. 2020;2:70–74.
81. Vivas D, Roldán I, Ferrandis R, et al; Expert reviewers. Perioperative and Periprocedural Management of Antithrombotic Therapy: Consensus Document of SEC, SEDAR, SEACV, SECTCV, AEC, SECPRE, SEPD, SEGO, SEHH, SETH, SEMERGEN, SEMFYC, SEMG, SEMICYUC, SEMI, SEMES, SEPAR, SENEC, SEO, SEPA, SERVEI, SECOT and AEU. *Rev Esp Cardiol (Engl Ed)*. 2018;71:553–564.
82. Kearon C, Akl EA, Comerota AJ, et al. Antithrombotic therapy for VTE disease: Antithrombotic Therapy and Prevention of Thrombosis, 9th ed: American College of Chest Physicians Evidence-Based Clinical Practice Guidelines. *Chest*. 2012;141:e419S–e496S.
83. De Pietri L, Montalti R, Nicolini D, et al. Perioperative thromboprophylaxis in liver transplant patients. *World J Gastroenterol*. 2018;24:2931–2948.
84. Gould MK, Garcia DA, Wren SM, et al. Prevention of VTE in nonorthopedic surgical patients: Antithrombotic Therapy and Prevention of Thrombosis, 9th ed: American College of Chest Physicians Evidence-Based Clinical Practice Guidelines. *Chest*. 2012;141:e227S–e277S.
85. Arcelus JI, Monreal M, Caprini JA, et al; RIETE investigators. Clinical presentation and time-course of postoperative venous thromboembolism: results from the RIETE Registry. *Thromb Haemost*. 2008;99:546–551.
86. Iannuzzi JC, Young KC, Kim MJ, et al. Prediction of postdischarge venous thromboembolism using a risk assessment model. *J Vasc Surg*. 2013;58:1014–20.e1.
87. Senzolo M, Burra P, Cholongitas E, et al. New insights into the coagulopathy of liver disease and liver transplantation. *World J Gastroenterol*. 2006;12:7725–7736.
88. Teng F, Sun KY, Fu ZR. Tailored classification of portal vein thrombosis for liver transplantation: focus on strategies for portal vein inflow reconstruction. *World J Gastroenterol*. 2020;26:2691–2701.
89. Sharshar M, Yagi S, Iida T, et al. Liver transplantation in patients with portal vein thrombosis: A strategic road map throughout management. *Surgery*. 2020;168:1160–1168.
90. Northup PG, Lisman T, Roberts LN. Treatment of bleeding in patients with liver disease. *J Thromb Haemost*. 2021;19:1644–1652.
91. Lisman T, Hernandez-Gea V, Magnusson M, et al. The concept of rebalanced hemostasis in patients with liver disease: communication from the ISTH SSC working group on hemostatic management of patients with liver disease. *J Thromb Haemost*. 2021;19:1116–1122.
92. Ertel AE, Chang AL, Kim Y, et al. Management of gastrointestinal bleeding in patients with cirrhosis. *Curr Probl Surg*. 2016;53:366–395.
93. Lisman T, Stravitz RT. Rebalanced hemostasis in patients with acute liver failure. *Semin Thromb Haemost*. 2015;41:468–473.
94. Doherty JU, Gluckman TJ, Hucker WJ, et al. 2017 ACC expert consensus decision pathway for periprocedural management of anticoagulation in patients with nonvalvular atrial fibrillation: a report of the American College of Cardiology Clinical Expert Consensus Document Task Force. *J Am Coll Cardiol*. 2017;69:871–898.
95. Burnett AE, Mahan CE, Vazquez SR, et al. Guidance for the practical management of the direct oral anticoagulants (DOACs) in VTE treatment. *J Thromb Thrombolysis*. 2016;41:206–232.
96. Baron TH, Kamath PS, McBane RD. Management of antithrombotic therapy in patients undergoing invasive procedures. *N Engl J Med*. 2013;368:2113–2124.

APPENDIX A

Consensus panel delegates of the Spanish Society of Liver Transplantation (SETH) listed in alphabetic order: Victoria Aguilera, La Fe Hospital Universitari i Politècnic; Ana Arias, Hospital Puerta de Hierro; Carme Baliellas, Hospital Universitario de Bellvitge; Inmaculada Benítez, Hospital Virgen del Rocío; Gerardo Blanco, Hospital Universitario de Badajoz; Antonio Cuadrado, Hospital Universitario Marqués de Valdecilla; Inmaculada Fernández Vázquez, Hospital Universitario 12 de Octubre; Yiliam Fundora, Hospital Clínic Barcelona; Luisa González Diéguez, Hospital Central de Asturias; Rocío González Grande, Hospital Regional Universitario de Málaga; Javier Graus, Hospital Universitario Ramón y Cajal; Ernest Hidalgo, Hospital Vall d’Hebron; Francisco

Hidalgo, Clínica Universitaria de Navarra; Sara Lorente, Hospital Clínico U. Lozano Blesa; María Flor Nogueras, Hospital Virgen de la Nieves; Alejandra Otero, Hospital Universitario de A Coruña; Sonia Pascual, Hospital General Universitario de Alicante; Baltasar Pérez Saborido, Hospital Universitario Río Hortega; José Antonio Pons, Hospital Universitario Virgen de la Arrixaca; Antonio Poyato González, Hospital Universitario Reina Sofía; María Vega Catalina Rodríguez, Hospital Gregorio Marañón; Patricia Salvador, Hospital Universitario de Cruces; Santiago Tomé, Hospital Clínico Universitario de Santiago; Aránzazu Varona, Hospital Universitario Nuestra Señora de la Candelaria; Juan José Vila, La Fe Hospital Universitari i Politècnic infantil.