

The Role of Endoscopic Ultrasound in the Interventional Management of Mediastinal Collections: A Narrative Review

Review began 07/20/2022

Review ended 08/07/2022

Published 08/09/2022

© Copyright 2022

Velasquez-Rodriguez et al. This is an open access article distributed under the terms of the Creative Commons Attribution License CC-BY 4.0., which permits unrestricted use, distribution, and reproduction in any medium, provided the original author and source are credited.

Julio G. Velasquez-Rodriguez ^{1, 2, 3}, Sandra Maisterra ^{1, 2, 3}, Ricard Ramos ^{4, 2, 3}, Ignacio Escobar ^{4, 2, 3}, Joan B. Gornals ^{1, 2, 3, 5}

1. Digestive Diseases/Endoscopy, Hospital Universitari de Bellvitge/Universitat de Barcelona, Barcelona, ESP 2. Clinical Research, Bellvitge Biomedical Research Institute (IDIBELL), Barcelona, ESP 3. Department of Clinical Sciences, School of Medicine and Health Sciences, University of Barcelona, Barcelona, ESP 4. Thoracic Surgery, Hospital Universitari de Bellvitge/Universitat de Barcelona, Barcelona, ESP 5. Faculty of Health Sciences, Universitat Oberta de Catalunya (UOC), Barcelona, ESP

Corresponding author: Joan B. Gornals, jgornals@bellvitgehospital.cat

Abstract

The numerous causes underlying mediastinal lesions require different diagnostic and therapeutic approaches, including conservative, minimally invasive, and surgical interventions. Solid lesions of a malignant nature, mostly located in the anterior mediastinum, are properly treated with surgical resection either with or without adjuvant schemes. In contrast, a surveillance program is usually recommended with solid benign tumors, depending on their size and related symptomatology. In the management of mediastinal collections, when a drainage intervention is required (suspicion of infection and symptomatology), a minimally invasive nonsurgical procedure or thoracic surgery is considered. The minimally invasive nonsurgical procedures that can be available are percutaneous radiology-guided imaging (abdominal ultrasound (US) or computed tomography (CT) scan), complete single-aspiration guided by endoscopic ultrasound (EUS) or endobronchial ultrasound (EBUS), and transmural drainage guided by EUS. Surgical debridement is feasible to treat collections, but as this entails considerable risk of postoperative complications, it is chosen only when other minimally invasive therapies are not possible. The published literature related to the interventional endoscopic approach to mediastinal lesions is scarce. Nevertheless, reports in this field reveal that interventional EUS may have a role in both the diagnosis of and therapeutic approach to mediastinal lesions, mainly in the management of mediastinal collections.

Categories: Other, Therapeutics

Keywords: mediastinal pseudocyst, interventional endoscopy, therapeutics, transmural drainage, endoscopic ultrasound, mediastinal cyst, mediastinal collection

Introduction And Background

Mediastinal lesions include a broad spectrum of pathologies. According to their nature, they may complicate locally with a mass effect on adjacent organs [1]. These lesions are divided into primary (e.g., solid or cystic lesions) and secondary (e.g., infectious, inflammatory, or hemorrhagic lesions) [2]. Multiple treatment options for mediastinal lesions exist, such as conservative management, minimally invasive procedures, and surgical interventions. Endoscopic ultrasound (EUS) is in most cases limited to posterior mediastinum-located lesions, offering an interventional ability to obtain diagnostic samples of mediastinal lesions.

The management of mediastinal collections that require drainage includes a surgical approach or a minimally invasive nonsurgical procedure such as percutaneously guided imaging or endoscopically by EUS.

The main objective of this review is to highlight the management of mediastinal collections (mainly posterior or middle) with simple (single aspiration) (safer but higher relapse rate) or transmural drainage (stenting) (high efficiency but more aggressive) guided by EUS.

Review

Methodology

We conducted a traditional narrative review (non-systematic and not including all available evidence) for obtaining a broad perspective on this topic. The main purpose was to identify peer-reviewed, published studies evaluating the role of interventional EUS in the management of mediastinal collections.

The literature cited in this narrative review was published from 1973 to 2022 and was searched on PubMed and Google Scholar. The following keywords were used: “mediastinal collection,” “mediastinal cyst,” “mediastinal pseudocyst,” “endoscopic ultrasound,” “fine needle aspiration,” and “transmural drainage.” The reviewers selected these articles by reviewing their titles and abstracts. Eligible studies considered relevant

How to cite this article

Velasquez-Rodriguez J G, Maisterra S, Ramos R, et al. (August 09, 2022) The Role of Endoscopic Ultrasound in the Interventional Management of Mediastinal Collections: A Narrative Review. *Cureus* 14(8): e27803. DOI 10.7759/cureus.27803

for drafting this narrative review included those that evaluated mediastinal collections or mediastinal pseudocyst treated by endoscopic ultrasound guidance (single aspiration, drainage, or pancreatic stent in the case of mediastinal pseudocyst). Additionally, the reference lists of the included studies were hand-searched.

Classification of mediastinal lesions

The mediastinum is a division of the thoracic cavity that has two main compartments: superior and inferior. The inferior is the larger one and so is further subdivided into three compartments: anterior, middle, and posterior [3].

This division accurately accounts for localizing and characterizing mediastinal lesions. Firstly, the mediastinum is divided into superior and inferior compartments by a plane that runs from the sternal angle to the T4-T5 vertebrae. The superior mediastinum is limited by the root of the neck at the top of the first ribs and by the inferior mediastinum below the described transverse thoracic plane. Secondly, the inferior mediastinum is divided into the anterior, middle, and posterior mediastinum, as shown in Figure 1.

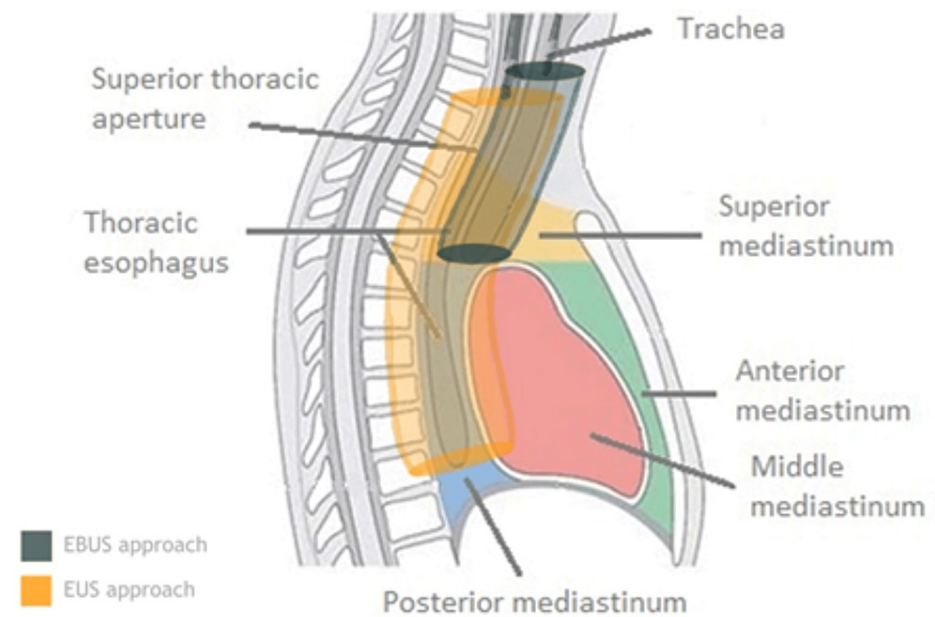


FIGURE 1: Compartments of the mediastinum

The two main compartments are the superior and inferior mediastinum (including anterior, middle, and posterior). The location of the trachea and esophagus is essential for understanding the role and limitations of EBUS and EUS, respectively.

Table 1 presents the main structural contents of each mediastinal compartment.

| | Superior mediastinum | Inferior mediastinum | | |
|-------------------------|--|--|---|---|
| | | Anterior | Middle | Posterior |
| Organs | Thymus, trachea, and esophagus | Thymus | Heart pericardium | Esophagus, thoracic spine, and paravertebral soft tissues |
| Arteries | Aortic arch, brachiocephalic trunk, and left common carotid | Smaller vessels and left brachiocephalic trunk | Ascending aorta, pulmonary trunk, branches, and pericardiophrenic | Thoracic aorta and branches |
| Veins and lymph vessels | Superior vena cava, brachiocephalic trunk, and thoracic duct | Smaller vessels, lymphatics, and lymph nodes | Superior vena cava, azygos, pulmonary, and pericardiophrenic | Azygos, hemiazygos, and thoracic duct |
| Nerves | Vagus, phrenic, and left recurrent laryngeal | None | Phrenic | Vagus |

TABLE 1: Mediastinum contents by compartment

Mediastinal lesions are clustered according to their tumor or cystic formation as malignant or benign course and primary or secondary origin. Following this classification, we may carry out differential diagnoses and identify potential treatment approaches.

Table 2, Table 3, and Table 4 include most of the mediastinal lesions, arranged according to their locations [1,4-28].

Lesions of the anterior mediastinum are solid tumors; thus, their treatment is usually based on surgical intervention. Some exceptions, where first-line treatment includes chemotherapy, exist, such as lymphoma (Table 2) [1,29-38]. In the middle mediastinum, most lesions are primary benign cysts such as bronchogenic cysts (Table 3) [32,33]. In the posterior mediastinum, most lesions are benign secondary collections, mainly liquid-containing lesions, with pseudocysts and abscesses being the most prevalent. More details concerning this group are presented in Table 4.

| Differential diagnosis | Features | Diagnosis | Approach |
|--------------------------|---|---|--|
| Thymus epithelial tumors | | | |
| Thymoma | Solid tumor, malignant, associated with myasthenia gravis | Contrasted CT scan, CT-FNA, US-FNA (staging) | SurgT ± CT ± RT |
| Thymic carcinoma | Malignant, symptomatic, associated with pleural effusion and pericardial cyst [1] | Contrasted CT scan, CT-FNA, US-FNA (staging) | SurgT, unresectable: CT/RT |
| Thymic carcinoid | Malignant, associated with Cushing syndrome and MEN1 [29], metastasis frequently | Contrasted CT scan to rule out hemorrhage, necrosis | SurgT ± CT/RT |
| Fat content lesions | | | |
| Thymolipoma | Rare, benign | MRI better than CT scan in differing fat | SurgT |
| Lipoma | Rare, benign, incidental | Contrasted CT scan | SurgT if with symptoms |
| Thymus hyperplasia | Young patient, follicular type associated with myasthenia gravis [30] | MRI better than CT scan in ruling out neoplastic features [8] | SurgT if with symptoms |
| Cystic lesions | | | |
| Thymic cyst | Rare, unilocular/multilocular, associated with inflammation or neoplasm (HD) | Contrasted CT scan; if solid component, MRI | SurgT if with symptoms |
| Pericardial cyst | Benign, right cardiophrenic angle [31] | Contrasted CT scan: unilocular, non-enhancing | SurgT if with symptoms |
| Lymphangioma | Congenital, benign, 10% mediastinal, associated with chylothorax and hemangiomas | CT scan, lymphangiography [32] | SurgT if with symptoms, visceral mediastinum, EBUS-TBNA [33] |
| Lymphoma | Rare, 10% of lymphoma, Hodgkin disease | CT scan | CT, RT |
| Germ cell tumors | | | |
| Teratoma | Benign, asymptomatic | CT scan | SurgT if with symptoms |
| Seminoma [37,38] | Men, 20-40 years, until 10% SVCS [34] | Gallium CT scan [35] | RT, CT, SurgT |

TABLE 2: Mediastinal lesions according to topographic location (prevascular (or anterior) mediastinum)

CT: chemotherapy; CT-FNA: computed tomography-guided fine needle aspiration; CT scan: computed tomography scan; EBUS-TBNA: endobronchial ultrasound-guided transbronchial needle aspiration; HD: Hodgkin disease; MEN1: multiple endocrine neoplasia type 1; MRI: magnetic resonance image; RT: radiotherapy; SurgT: surgical treatment; SVCS: superior vena cava syndrome; US-FNA: ultrasound-guided fine needle aspiration

| Differential diagnosis | Features | Diagnosis | Approach |
|------------------------|--|--------------------------------|--|
| Cystic lesions | | | |
| Bronchogenic cyst | Cartilaginous content, near the carina | CT scan, EBUS, EUS (sample) | SurgT, single aspiration |
| Esophageal cyst | Esophageal wall | CT scan, EUS | SurgT, VATS |
| Pericardial cyst | Congenital, benign; right cardiophrenic angle | | |
| Lymphangioma | Congenital, benign, 10% mediastinal, associated with chylothorax and hemangiomas | CT scan, lymphangiography [32] | SurgT if with symptoms, visceral mediastinum, EBUS-TBNA [33] |
| Esophageal lesions | | | |
| Esophageal cancer | Dysphagia | EGD, CT scan, EUS | SurgT (T1a: endoscopy) |
| Esophageal leiomyoma | Benign | EUS | Conservative, endoscopy, SurgT |
| Metastasis | | CT scan, EUS-FNA | According to primary |

TABLE 3: Mediastinal lesions according to topographic location (visceral (or middle) mediastinum)

CT scan: computed tomography scan; EBUS: endobronchial ultrasound; EBUS-TBNA: endobronchial ultrasound-guided transbronchial needle aspiration; EGD: esophagogastroduodenoscopy; EUS-FNA: endoscopic ultrasound-guided fine needle aspiration; SurgT: surgical treatment; VATS: video-assisted thoracoscopic surgery

| Differential diagnosis | Features | Diagnosis | Approach |
|-----------------------------|---|--|--|
| Neurogenic tumors | | | |
| Nerve sheath tumors | Benign | CT scan, MRI for intraspinal extension | SurgT ± CT, RT |
| Autonomic ganglionic tumors | Malignant, associated with neurofibromatosis, 5% sarcomatous degeneration | CT scan | |
| Cystic lesions | | | |
| Pancreatic pseudocyst | Acute or chronic pancreatitis history | CT scan to rule out necrosis, EUS-FNA | Conservative, SurgT, EUS drainage, transpapillary (via ERCP) |
| Mediastinal abscess | Esophageal surgery or injury history | CT scan to rule out associated empyema | Conservative, SurgT, EUS drainage |

TABLE 4: Mediastinal lesions according to topographic location (paravertebral (or posterior) mediastinum)

CT: chemotherapy; CT-FNA: computed tomography-guided fine needle aspiration; CT scan: computed tomography scan; EUS-FNA: endoscopic ultrasound-guided fine needle aspiration; SurgT: surgical treatment; RT: radiotherapy; US-FNA: ultrasound-guided fine needle aspiration

Mediastinal collections in the posterior mediastinum

Lesions located in the posterior mediastinum are most commonly punctured or treated by EUS. As previously commented, most of these lesions are abscesses and pancreatic fluid collections (pseudocyst or rarely walled-off pancreatic necrosis).

Mediastinal Abscess

A mediastinal abscess can be fatal, with mortality rates reaching 40%, especially when proper diagnosis and treatment are delayed [4]. Injury of adjacent organs such as esophageal perforation, sternal osteomyelitis, and extension of pulmonary, pleural, cervical, or retroperitoneal infection are the primary causes of associated morbimortality. Classically, antibiotic therapy in combination with surgical debridement, either by open surgery or video-assisted, is the treatment of choice [5]. Nevertheless, minimally invasive procedures, such as percutaneous drainage, have proven effective, and they carry lower complication rates [6].

Pancreatic Fluid Collections

Pancreatic fluid collections, mainly pseudocysts, are the second cause of secondary mediastinal lesions. They develop by encapsulation with an inflammatory tissue wall, which appears in the background of acute or chronic pancreatitis. Due to the location of the pancreas, the pancreatic fluid collection grows throughout the retroperitoneal region; however, it may be allocated in other cavities such as the mediastinum. The lesion reaches the mediastinum typically through the diaphragmatic hiatus and less commonly via the aorta or inferior cava hiatus vein. Most pancreatic fluid collections resolve spontaneously [7]. In accordance with lesion features such as size, related symptom severity, pancreatic ductal anatomy, and operator experience, the need for therapy will be discussed below.

Diagnosis of mediastinal lesions

Diagnostic and Interventional Imaging

It appears that a CT scan is equal to or slightly superior to magnetic resonance imaging (MRI) in the diagnosis of anterior mediastinal tumors, except for thymic cysts. Some studies analyzing and comparing the sensitivity of CT scan images to MRI in mediastinum lesion diagnosis reported only a slight superiority of CT scan, with an accuracy of 61% compared to 56%. They optimized the diagnosis, putting the two together and reaching 67% accuracy [8]. However, MRI benefits were the focus of the study of cystic lesions since it is capable of identifying malignancy signs, such as solid components, and areas of necrosis, and also explicitly distinguishing thymus hyperplasia from thymus neoplasia [8].

Transthoracic ultrasound (US) has proven its utility in the study of mediastinal lesions since it offers the advantage of sampling via US-guided fine needle aspiration (US-FNA). Nevertheless, the benefits are limited to the anterior mediastinum [9].

Interventional Diagnosis by EBUS

Mediastinal lesion samples obtained by either EBUS-guided transbronchial needle aspiration (TBNA) or endoscopic ultrasound-guided tissue acquisition (EUS-TA) show an average sensitivity of 93%, a result that is notably valuable regarding lymphoma and other mediastinal neoplastic studies since diagnosis requires immunohistochemical evidence [10]. These are minimally invasive procedures that permit the avoidance of more aggressive interventions such as mediastinoscopy and thoracoscopy and thereby offer a lower complication rate [11]. In addition, it is important to consider anatomical references to better understand the range of intervention capacity for each procedure. Thus, EBUS-TBNA is performed with a bronchoscope using a transducer on the tip, which enables approaching the peribronchial or peritracheal areas to either sample tissue or drain aspiration. Furthermore, lesions located in the anterior mediastinum are still not accessible by EBUS-TBNA.

Interventional Diagnosis by EUS of Middle and Posterior Mediastinal Lesions

EUS-TA offers the power to acquire tissue from the middle and posterior mediastinum along the esophagus for cytohistological study with significant accuracy and safety [12,13,18,39-45]. A study that compared the usefulness of EBUS-TBNA versus EUS-FNA in the diagnosis of mediastinal lesions under suspicion of malignancy did not uncover differences between the two procedures, and by combining them, researchers achieved nearly 100% accuracy [12]. These results suggest the utility of combining the two procedures to inspect and sample within the different mediastinum regions.

In contrast, although they are both considered minimally invasive interventions compared to the classically used methods such as mediastinoscopy, there could still be complications. A national retrospective survey evaluated the rate of adverse events related to EBUS-TBNA and EUS-FNA. For a 12-year period, the study obtained an adverse event rate of 0.11% and 0.16% related to EBUS-TBNA and EUS-FNA, respectively, and found an overall mortality rate of 0.04% [13]. Most complications were infectious diseases related to tissue acquisition; bleeding was less frequent and better controlled during procedures. A technical advantage of EUS-TA also includes the capability of using a wider-diameter needle such as 19-gauge needles [14].

Treatment approaches for mediastinal collections

Conservative Management Strategy

Conservative treatment is considered the first step of therapy only if the patient is suitable for this approach. This involves the lesion type and its clinical impact. Mediastinal collections such as pancreatic pseudocyst can be handled by diverse approaches. Case reports have shown the efficacy of conservative treatment with octreotide, a somatostatin analog that inhibits pancreatic secretions and facilitates the closing of the pancreatic fistula, which forms the collection [15-17]. Nonetheless, the evidence for clinical recommendation of the treatment is lacking. On the other hand, mediastinal abscess shows a poor response to conservative treatment. Therefore, a better approach would be surgical drainage and then minimally interventional procedures.

Interventionist Treatment

Patients who are nonresponders to conservative treatment of lesions are considered for therapeutic intervention, aiming at debridement and/or drainage. In this setting and because of overall morbidity especially in nonsurgical candidates, minimally invasive techniques have been offered and have shown satisfactory results. These techniques include CT-guided percutaneous drainage, EUS- or EBUS-guided single needle aspiration, and/or EUS-guided transmural drainage. Decisions on strategy therapy should be made by a multidisciplinary committee. The use of CO₂ is highly recommended for EUS-guided transmural procedures to prevent air embolism.

CT-Guided Percutaneous Drainage

CT-guided percutaneous drainage represents an appropriate alternative to interventionist treatment. Since the first report in 1987 of a mediastinal abscess treated by CT-guided percutaneous drainage, several case reports and a 10-year series including 23 patients have been published [6,25-28]. Some 84% of abscesses were located in the posterior mediastinum, while the remainder were located in the anterior mediastinum. Technical success was achieved in 100% of procedures, while clinical success, which was defined as abscess resolution by a percutaneous approach without the need for surgical debridement, was achieved in 22 of 23 patients (96%) [6]. However, studies comparing this procedure to surgical debridement and endoscopic management are lacking.

EBUS-TBNA Drainage (Single Aspiration)

There are a few data concerning treatment using the EBUS-TBNA approach. Table 5 summarizes case reports of successful EBUS-TBNA treatment [36,46-53]. These reports suggest that EBUS-TBNA could be a safe alternative treatment compared to more aggressive strategies. The limitations of this approach include the use of narrow devices such as 22- or 25-gauge needles, which preclude performing drainage by single aspiration only. Furthermore, as previously mentioned, mediastinal access to the EBUS-TBNA is limited, so almost all reported cases listed involve lesions located in the paratracheal area within the middle mediastinum.

| Author, year | Number of patient(s) | Diagnosis | Size | Materials | Clinical success* | Stent removal | Adverse events | Follow-up |
|----------------------------|----------------------|---------------------------|-------------------|-------------------------------------|-------------------|---------------|----------------|-----------|
| Nakajima et al., 2007 [48] | 1 | Mediastinal cyst | 65 × 57 mm | Single EBUS-TBNA, 22 Ga | Yes | NA | No | 1 year |
| Twehues et al., 2011 [49] | 2 | Bronchogenic cyst | 40 × 56 mm | Single EBUS-TBNA, 22 Ga | Yes | NA | NA | 16 months |
| | | Bronchogenic cyst | 43 × 57 mm | Single EBUS-TBNA, 22 Ga | No | NA | NA | NA |
| Choi et al., 2012 [36] | 1 | Paratracheal lymphangioma | 137 mm (diameter) | Single EBUS-TBNA, 22 Ga | Yes | NA | No | 12 months |
| Alraiyes et al., 2015 [50] | 1 | Bronchogenic cyst | 50 mm (diameter) | Single EBUS-TBNA, unknown materials | Yes | NA | No | 3 months |
| Li et al., 2017 [51] | 1 | Thyroid cyst | 11 × 14 mm | Single EBUS-TBNA, 22 Ga | Yes | NA | No | 7 weeks |

TABLE 5: Mediastinal lesions treated using EBUS-TBNA single aspiration

* Disappearance of the lesion or enough reduction to exclude further procedures

EBUS-TBNA: endobronchial ultrasound-guided transbronchial needle aspiration; NA: not applicable

EUS-Guided Drainage (Single Aspiration and Transmural Drainage)

Several factors may influence the feasibility of endoscopic treatment in the mediastinal region. The tubular shape of the esophagus and the elastic property of the GI wall combined allow the endoscope tip to get closer to a remote anatomical region. Additionally, therapeutic scopes are provided with wider working channels so that a broader spectrum of devices is enabled, thereby allowing several alternative strategies to be considered. Mediastinal collections treated by EUS guidance are located in the posterior or middle (or paraesophageal) mediastinum. The esophagus is located at the posterior pole of the middle mediastinum, so access is confined to anterior paraesophageal structures corresponding to the middle mediastinum and posterior mediastinum region. The anterior mediastinum is limited by vascular structures and trachea and is far away from the esophagus, so these regions are best approached by other techniques. Several variables such as lesion features (size and solid component) and the clinical scenario (fever and sepsis) are taken into consideration when deciding upon the best strategy via EUS.

EUS-Guided Single Aspiration

EUS-guided single aspiration is defined as a needle puncture followed by total or near-total content aspiration to collapse the lesion volume; these steps allow for shortening the procedure duration in a safe way. This simple interventional approach is documented in several reports showing acceptable efficacy, reducing the risk of procedure complications compared to transmural drainage. However, the likelihood of recurrence on follow-up is real [18-21].

Table 6 shows a case series involving this endoscopic approach to mediastinal lesions [18,19].

| Author, year | Number of patient(s) | Diagnosis | Size | Materials | Clinical success* | Stent removal | Adverse events | Follow-up |
|------------------------------------|----------------------|---------------------------------|------------------|-----------------------------------|-------------------|---------------|----------------|-----------|
| Fritscher-Ravens et al., 2000 [18] | 2† | Mediastinal abscess | 25 mm (diameter) | Single EUS-FNA, 22 Ga | Yes | NA | No | 6 months |
| | | Traumatic paratracheal hematoma | 57 mm (diameter) | Single EUS-FNA, unknown materials | Yes | NA | NA | 8 months |
| Davarashvili et al., 2017 [19] | 1 | Infected bronchogenic cyst | 50 mm (diameter) | Single EUS-FNA, unknown materials | Yes | NA | NA | 4 years |

TABLE 6: Mediastinal lesions treated using EUS-guided single aspiration

* Disappearance of the lesion or enough reduction to exclude further procedures

† Three patients were reported in the original article; in the third patient (not included in our list), only diagnostic EUS-FNA of a mediastinal lesion suggestive of malignancy was performed

EUS-FNA: endoscopic ultrasound-guided fine needle aspiration; NA: not applicable

Although EUS-guided single aspiration represents a lower part of the series, it may offer benefits such as endoscopic drainage and obtaining a sample for culture at the same time. The strengths of this option are that it does not need great technical skill and it is less risky than transmural drainage. Moreover, if clinical outcomes are favorable, no further endoscopy is needed.

EUS-Guided Transmural Drainage

This approach is based on temporary stent (plastic or metal) placement to maintain proper drainage between the two cavities, the lesion, and the digestive lumen. EUS-guided transmural drainage of a mediastinal collection is the most common endoscopic treatment approach since its efficacy is well recognized in other body regions as well, such as the abdomen. Table 7 summarizes mediastinal lesions treated by EUS-guided transmural endoscopic drainage [22,23,44-47].

| Author, year | Number of patient(s) | Diagnosis | Size | Materials | Clinical success* | Stent removal | Adverse events | Follow-up |
|-------------------------------|----------------------|-----------------------------------|------------------|-------------------------------------|-------------------|---------------|----------------|------------------|
| Kahaleh et al., 2004 [44] | 1 | Postoperative mediastinal abscess | 40 × 28 mm | Single pigtail 7 Fr | Yes | 3 months | NA | 3 months |
| Jonas et al., 2005 [45] | 1 | Metastatic cyst | 30 mm (diameter) | Double pigtail 7 Fr | Yes | NA | NA | 18 months |
| Wehrmann et al., 2005 [22] | 20 | Paraesophageal abscess formation | >20 mm | Double pigtail 8,5 Fr (4)‡ | Yes, 100% (04/04) | NA | NA | 12 months (3-40) |
| | | | | Necrosectomy (Dormia, lavage) (15)‡ | Yes, 100% (15/15) | NA | 1 death, 6% | |
| | | | | Abscess access failed (1)‡ | No | NA | NA | |
| Saxena et al., 2014 [46] | 1 | Postoperative mediastinal abscess | 63 × 46 mm | Two double pigtail 7 Fr | Yes | 4 weeks | No | 3 months |
| Kawaguchi et al., 2014 [47] | 1 | Infected bronchogenic cyst | 90 × 70 mm | Nasocystic catheter 6 Fr | Yes | 3 days | NA | 5 months |
| Consiglieri et al., 2015 [23] | 1 | Postoperative mediastinal abscess | 60 × 50 mm | LAMS 10 × 10 mm | Yes | 7 days | NA | 2 years |

TABLE 7: Mediastinal lesions treated using EUS-guided transmural endoscopic drainage

* Disappearance of the lesion or enough reduction to exclude further procedures

‡ Total number of patients treated by each technique

LAMS: lumen-apposing metal stent; NA: not applicable

It has shown good results in abdominal lesions; in addition, it is considered the treatment of choice for abdominal lesion drainage in peripancreatic collections. This strategy directed to mediastinal lesions appeals to the abovementioned experience (EUS-guided transesophageal drainage), and the outcomes are acceptable. It seems that the presence of an abscess, likely in the form of a heterogeneous and solid-content lesion, induced the need to perform transmural drainage and, eventually, the creation of a stoma. Although these are case reports, a highlight is a German study that included 15 patients with paraesophageal abscesses treated by EUS-guided transmural technique, with the creation of esophagostomy and routine endoscopic washing, and achieving clinical success in all the patients included [22].

Given the low-level experience reported, it is difficult to recommend a specific stent; however, the majority of cases described involved plastic single- or double-pigtail stent use, likely to avoid local complications related to the use of self-expandable metal stents [23].

Regarding the safety of EUS-guided transmural drainage, two adverse events were reported. One was pneumothorax while performing transesophageal puncture, which was controlled during the procedure [24]. The other was a pulmonary artery embolism unrelated to the technique the day after the procedure, with a fatal outcome [22].

EUS-guided transmural drainage is not only effective for lesions originating in the mediastinum; there is also evidence of mediastinum-extended abdominal lesions successfully treated using transmural EUS guidance.

Table 8 shows abdominal lesions with mediastinal extension treated using endoscopic approach [20,21,24,52-66].

| Author, year | Number of patient(s) | Diagnosis | Size | Materials | Clinical success* | Stent removal | Adverse events | Follow-up |
|--------------|----------------------|------------|------|-----------|-------------------|---------------|----------------|-----------|
| Mohl et al., | | Pancreatic | | | | | | |

| | | | | | | | | |
|---------------------------------|-----|--------------------------------------|--------------------------|---|-----------------|---------|--|----------------------|
| 2004 [52] | 1 | pseudocyst | NA | Double pigtail 7 Fr | Yes | 2 weeks | NA | 8 months |
| Komtong et al., 2006 [53] | 1 | Pancreatic pseudocyst | 40 mm | Transpapillary pancreatic stent 10 Fr | Yes | 60 days | NA | 6 months |
| Săftoiu et al., 2006 [54] | 1 | Pancreatic pseudocyst | 150 mm | Plastic stent 10 Fr | Yes | 30 days | No | 3 months |
| Gupta et al., 2007 [20] | 1 | Pancreatic pseudocyst | 190 × 120 mm | Single EUS-FNA, 19 Ga | Yes | NA | NA | 3 months |
| Trevino et al., 2009 [55] | 3 | Pancreatic pseudocyst | 8 × 6 cm | Nasocystic stent 7 Fr | Yes | 4 days | No | 3 years |
| | | | 7 × 6 cm | Double pigtail 7 Fr | Yes | 8 weeks | No | 2 years |
| | | | 6 × 5 cm | Double pigtail 7 Fr | Yes | 8 weeks | No | 1 year |
| Mallavarapu et al., 2001 [56] | 2 | Pancreatic pseudocyst | NA | Transpapillary pancreatic stent 7 Fr | Yes | 6 weeks | No | 20 months |
| | | | NA | Transpapillary pancreatic stent 8.5 Fr | Yes | 3 weeks | No | 2 years |
| Bhasin et al., 2012 [57] | 11† | Pancreatic pseudocyst | 20-80 mm (median: 40 mm) | Naso-pancreatic drain 5 Fr (5) ‡ | Yes, 100% (5/5) | 8 weeks | No | 4 months to 10 years |
| | | | | Pancreatic stent 5 Fr (5) ‡ | Yes, 100% (5/5) | 8 weeks | No | |
| | | | | Pancreatic sphincterotomy (1) ‡ | Yes | NA | No | |
| Gornals et al., 2012 [24] | 1 | Pancreatic pseudocyst | 80 × 50 mm | LAMS 10 × 10 mm | Yes | 7 days | Pneumothorax | 6 months |
| Sugimoto et al., 2014 [58] | 1 | Pancreatic pseudocyst | NA | Double pigtail 7 Fr plus naso tube 5 Fr | Yes | NA | No | 10 days |
| Mishra et al., 2016 [59] | 1 | Pancreatic pseudocyst | 56 × 36 mm | NA | NA | NA | NA | NA |
| Nasa et al., 2016 [21] | 1 | Pancreatic pseudocyst | NA | Single EUS-FNA, 19 Ga | Yes | NA | NA | 6 months |
| Dabkowski et al., 2017 [61] | 1 | Pancreatic pseudocyst | NA | Pancreatic stent | Yes | NA | No | 12 months |
| Takayanagi et al., 2018§ [60] | 1 | Pancreatic pseudocyst | NA | Transgastric EUS-CD | Yes | NA | No | NA |
| Pizzicannella et al., 2019 [62] | 1 | Necrotic pancreatic fluid collection | NA | LAMS | Yes | NA | No | NA |
| Nakamura et al., 2021 [63] | 1 | Pancreatic pseudocyst | NA | EUS-guided drainage and naso-pancreatic stent | Yes | NA | No | NA |
| Aritake et al., 2021 [64] | 1 | Pancreatic pseudocyst | NA | EUS-guided drainage, stent | Yes | NA | Bronchial fistula and esophageal stricture | 4 months |
| Inomata et al., 2022 [65] | 1 | Pancreatic pseudocyst | NA | Naso-pancreatic drainage | Yes | NA | No | NA |
| Watanabe et al., 2022 [66] | 1 | Pancreatic pseudocyst | NA | Naso-pancreatic drainage (5 Fr) | Yes | NA | Recurrence at 6 months | 27 months |

TABLE 8: Mediastinal extended abdominal collections drained using an endoscopic approach

* Disappearance of the lesion or enough reduction to exclude further procedures

† Twelve patients in the original article; one patient refused treatment (not included in our list)

§ Abstract only

EUS-CD: endoscopic ultrasound-guided cyst drainage; EUS-FNA: endoscopic ultrasound-guided fine needle aspiration; LAMS: lumen-apposing metal stent, NA: not applicable

The main etiology of the lesions was pancreatic pseudocyst, which, as noted above, constitutes a minor but feasible extension. The endoscopic strategy is diverse, with the EUS-guided drainage being the most common approach. Other strategies include transpapillary pancreatic treatment and EUS-guided single aspiration. Clinical outcomes are promising for such an uncommon condition, as is the safety profile. Pneumothorax was reported while placing a lumen-apposing stent that was successfully treated by intercostal drainage. In spite of this, the thoracic surgeon who performed the procedure thought this was a complication from orotracheal positive pressure [24,54,61].

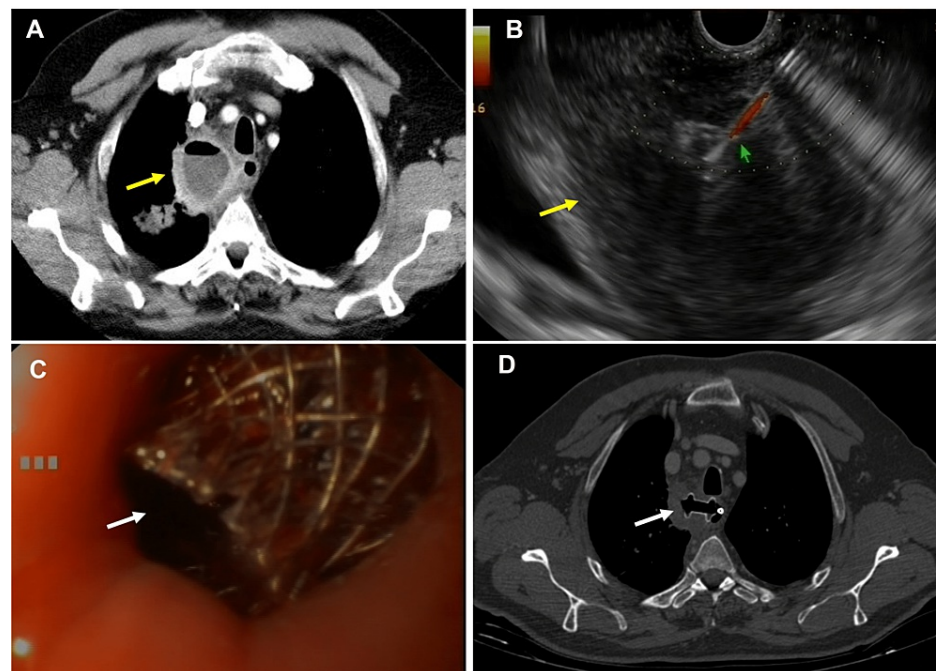


FIGURE 2: Transmural drainage of mediastinal collection

A: Computed tomography scan image of an infected mediastinal collection (note the air-fluid level, yellow arrow). B: Image of endosonography-guided transmural drainage of a mediastinal abscess (yellow arrow); EUS-guided aspiration using a 19 G needle (green arrow) was performed to obtain a sample. C: Endoscopic view of the transesophageal drainage of a mediastinal lesion by placing a lumen-apposing stent (white arrow). D: Computed tomography image of a lumen-apposing stent placed for mediastinal collection of transesophageal drainage (white arrow).

Surgical Approach

Mediastinal surgery constitutes the treatment of abscesses within the mediastinum with the highest success rate. Moreover, since the 1990s, the surgical approach has had new technologies based on video images available, allowing less invasive access compared to open surgery, with a similar recurrence rate [29]. Although these procedures are now less aggressive than conventional approaches, they carry a surgical and anesthesia-related morbidity risk.

Conclusions

The management of mediastinal collections in which a drainage is required includes a surgical approach and minimally invasive nonsurgical procedures such as percutaneously guided imaging and interventional endoscopy. The nature and location of the collection will condition the selection of the strategy.

Furthermore, although scientific evidence of EUS-guided therapy is limited, it is a promising, minimally invasive technique. The most common mediastinal collections treated by EUS are abscesses and pseudocyst (migrated to the mediastinum) located in the posterior compartment. Basically, EUS-guided drainage of

mediastinal collections includes two techniques: collapse by single aspiration (no stent) and transmural drainage (with stent deployment).

Single aspiration can be used by EBUS or EUS, depending on the collection site and accessibility. This is a well-acceptable, non-risky technique, but the potential relapse rate may be higher.

A EUS-guided transmural (transesophageal) drainage differs because of the necessity of stenting, using plastic stents or LAMS. Despite it being more aggressive and associated with complications, the outcomes in long term are superior.

Decisions on therapy strategy should be made by a multidisciplinary committee including surgeons, radiologists, and endoscopists.

Additional Information

Disclosures

Conflicts of interest: In compliance with the ICMJE uniform disclosure form, all authors declare the following: **Payment/services info:** All authors have declared that no financial support was received from any organization for the submitted work. **Financial relationships:** All authors have declared that they have no financial relationships at present or within the previous three years with any organizations that might have an interest in the submitted work. **Other relationships:** All authors have declared that there are no other relationships or activities that could appear to have influenced the submitted work.

Acknowledgements

We would like to thank CERCA Programme/Generalitat de Catalunya for institutional support.

References

- Duwe BV, Sterman DH, Musani AI: Tumors of the mediastinum. *Chest*. 2005, 128:2893-909. [10.1378/chest.128.4.2893](https://doi.org/10.1378/chest.128.4.2893)
- Cameron RB, Loehrer PJ, Thomas CR: Neoplasms of the mediastinum. *Cancer: principles and practice of oncology*. DeVita VT, Hellman S, Rosenber SA (ed): Lippincott Williams & Wilkins, Philadelphia, PA; 2015. 560-9.
- Carter BW, Betancourt SL, Benveniste MF: MR imaging of mediastinal masses. *Top Magn Reson Imaging*. 2017, 26:153-65. [10.1097/RMR.0000000000000134](https://doi.org/10.1097/RMR.0000000000000134)
- Misthos P, Katsarakakis S, Kakaris S, Theodorou D, Skottis I: Descending necrotizing anterior mediastinitis: analysis of survival and surgical treatment modalities. *J Oral Maxillofac Surg*. 2007, 65:635-9. [10.1016/j.joms.2006.06.287](https://doi.org/10.1016/j.joms.2006.06.287)
- Chen KC, Chen JS, Kuo SW, Huang PM, Hsu HH, Lee JM, Lee YC: Descending necrotizing mediastinitis: a 10-year surgical experience in a single institution. *J Thorac Cardiovasc Surg*. 2008, 136:191-8. [10.1016/j.jtcvs.2008.01.009](https://doi.org/10.1016/j.jtcvs.2008.01.009)
- Arellano RS, Gervais DA, Mueller PR: Computed tomography-guided drainage of mediastinal abscesses: clinical experience with 23 patients. *J Vasc Interv Radiol*. 2011, 22:673-7. [10.1016/j.jvir.2011.01.427](https://doi.org/10.1016/j.jvir.2011.01.427)
- Frenzer A, Schubarth P, Soucek M, Krähenbühl S: Disappearance of a large mediastinal pseudocyst in a patient with chronic alcoholic pancreatitis after total parenteral nutrition. *Eur J Gastroenterol Hepatol*. 1995, 7:369-71.
- Tomiya N, Honda O, Tsubamoto M, et al.: Anterior mediastinal tumors: diagnostic accuracy of CT and MRI. *Eur J Radiol*. 2009, 69:280-8. [10.1016/j.ejrad.2007.10.002](https://doi.org/10.1016/j.ejrad.2007.10.002)
- Chira RI, Chira A, Mircea PA, Valean S: Mediastinal masses-transthoracic ultrasonography aspects. *Medicine (Baltimore)*. 2017, 96:e9082. [10.1097/MD.00000000000009082](https://doi.org/10.1097/MD.00000000000009082)
- Yasufuku K, Nakajima T, Fujiwara T, Yoshino I, Keshavjee S: Utility of endobronchial ultrasound-guided transbronchial needle aspiration in the diagnosis of mediastinal masses of unknown etiology. *Ann Thorac Surg*. 2011, 91:831-6. [10.1016/j.athoracsur.2010.11.032](https://doi.org/10.1016/j.athoracsur.2010.11.032)
- Gu P, Zhao YZ, Jiang LY, Zhang W, Xin Y, Han BH: Endobronchial ultrasound-guided transbronchial needle aspiration for staging of lung cancer: a systematic review and meta-analysis. *Eur J Cancer*. 2009, 45:1389-96. [10.1016/j.ejca.2008.11.043](https://doi.org/10.1016/j.ejca.2008.11.043)
- Vilmann P, Krasnik M, Larsen SS, Jacobsen GK, Clementsen P: Transesophageal endoscopic ultrasound-guided fine-needle aspiration (EUS-FNA) and endobronchial ultrasound-guided transbronchial needle aspiration (EBUS-TBNA) biopsy: a combined approach in the evaluation of mediastinal lesions. *Endoscopy*. 2005, 37:833-9. [10.1055/s-2005-870276](https://doi.org/10.1055/s-2005-870276)
- von Bartheld MB, Annema JT: Endosonography-related mortality and morbidity for pulmonary indications: a nationwide survey in the Netherlands. *Gastrointest Endosc*. 2015, 82:1009-15. [10.1016/j.gie.2015.03.1973](https://doi.org/10.1016/j.gie.2015.03.1973)
- Yasuda I, Tsurumi H, Omar S, et al.: Endoscopic ultrasound-guided fine-needle aspiration biopsy for lymphadenopathy of unknown origin. *Endoscopy*. 2006, 38:919-24. [10.1055/s-2006-944665](https://doi.org/10.1055/s-2006-944665)
- Gullo L, Barbara L: Treatment of pancreatic pseudocysts with octreotide. *Lancet*. 1991, 338:540-1. [10.1016/0140-6736\(91\)91102-z](https://doi.org/10.1016/0140-6736(91)91102-z)
- Suga H, Tsuruta O, Okabe Y, et al.: A case of mediastinal pancreatic pseudocyst successfully treated with somatostatin analogue. *Kurume Med J*. 2005, 52:161-4. [10.2739/kurumemedj.52.161](https://doi.org/10.2739/kurumemedj.52.161)
- Yasuda H, Ino Y, Igarashi H, Arita Y, Nakamura M, Sumii T, Nawata H: A case of pancreatic pleural effusion and mediastinal pancreatic pseudocyst: management by a somatostatin analogue octreotide. *Pancreas*.

- 1999, 19:410-2. [10.1097/00006676-199911000-00015](https://doi.org/10.1097/00006676-199911000-00015)
18. Fritscher-Ravens A, Sriram PV, Pothman WP, Füllekrug B, Jäckle S, Thonke F, Soehendra N: Bedside endosonography and endosonography-guided fine-needle aspiration in critically ill patients: a way out of the deadlock?. *Endoscopy*. 2000, 32:425-7. [10.1055/s-2000-9001](https://doi.org/10.1055/s-2000-9001)
 19. Davarashvili IO, Epstein Y, Khoury T: Infected mediastinal bronchogenic cyst successfully treated by endoscopic ultrasound-guided fine-needle aspiration drainage through the esophagus. *Dig Endosc*. 2017, 29:727-8. [10.1111/den.12898](https://doi.org/10.1111/den.12898)
 20. Gupta R, Munoz JC, Garg P, Masri G, Nahman NS, Lambiase LR: Mediastinal pancreatic pseudocyst—a case report and review of the literature. *MedGenMed*. 2007, 9:8.
 21. Nasa M, Choudhary N, Patil G, Puri R: Mediastinal pancreatic pseudocyst. *J Dig Endosc*. 2016, 7:20-5. [10.4103/0976-5042.180095](https://doi.org/10.4103/0976-5042.180095)
 22. Wehrmann T, Stergiou N, Vogel B, Riphhaus A, Köckerling F, Frenz MB: Endoscopic debridement of paraesophageal, mediastinal abscesses: a prospective case series. *Gastrointest Endosc*. 2005, 62:344-9. [10.1016/j.gie.2005.03.001](https://doi.org/10.1016/j.gie.2005.03.001)
 23. Consiglieri CF, Escobar I, Gornals JB: EUS-guided transesophageal drainage of a mediastinal abscess using a diabolo-shaped lumen-apposing metal stent. *Gastrointest Endosc*. 2015, 81:221-2. [10.1016/j.gie.2014.04.060](https://doi.org/10.1016/j.gie.2014.04.060)
 24. Gornals JB, Loras C, Mast R, Botargues JM, Busquets J, Castellote J: Endoscopic ultrasound-guided transesophageal drainage of a mediastinal pancreatic pseudocyst using a novel lumen-apposing metal stent. *Endoscopy*. 2012, 44:E211-2. [10.1055/s-0032-1309384](https://doi.org/10.1055/s-0032-1309384)
 25. Semelka RC, Greenberg HM: Percutaneous drainage of an infected mediastinal pseudocyst. *Can Assoc Radiol J*. 1987, 38:54-5.
 26. Tanaka T, Inaba Y, Arai Y, Matsueda K, Aramaki T, Dendo S: Mediastinal abscess successfully treated by percutaneous drainage using a unified CT and fluoroscopy system. *Br J Radiol*. 2002, 75:470-3. [10.1259/bjr.75.893.750470](https://doi.org/10.1259/bjr.75.893.750470)
 27. Zhou S, Dong S, Du J: Percutaneous therapy of a mediastinal lymphangioma with fibrin glue: case report with clinical success after 4 years. *BMC Surg*. 2018, 18:4. [10.1186/s12893-018-0359-x](https://doi.org/10.1186/s12893-018-0359-x)
 28. Latif A, Selim M, Kapoor V, Ali M, Mirza MM, Stavas JM: Successful percutaneous computed tomography guided drainage of mediastinal abscess in esophageal perforation. *Intractable Rare Dis Res*. 2019, 8:221-3. [10.5582/irdr.2019.01080](https://doi.org/10.5582/irdr.2019.01080)
 29. Rakovich G, Deslauriers J: Video-assisted and minimally-invasive open chest surgery for the treatment of mediastinal tumors and masses. *J Vis Surg*. 2017, 3:25. [10.21037/jovs.2017.01.01](https://doi.org/10.21037/jovs.2017.01.01)
 30. Li Y, Wang J: Experience of video-assisted thoracoscopic resection for posterior mediastinal neurogenic tumours: a retrospective analysis of 58 patients. *ANZ J Surg*. 2013, 83:664-8. [10.1111/j.1445-2197.2012.06174.x](https://doi.org/10.1111/j.1445-2197.2012.06174.x)
 31. Gibril F, Chen YJ, Schrupp DS, et al.: Prospective study of thymic carcinoids in patients with multiple endocrine neoplasia type 1. *J Clin Endocrinol Metab*. 2003, 88:1066-81. [10.1210/jc.2002-021314](https://doi.org/10.1210/jc.2002-021314)
 32. Nishino M, Ashiku SK, Kocher ON, Thurer RL, Boiselle PM, Hatabu H: The thymus: a comprehensive review. *Radiographics*. 2006, 26:335-48. [10.1148/rg.262045213](https://doi.org/10.1148/rg.262045213)
 33. Takahashi K, Inaoka T, Murakami N, et al.: Characterization of the normal and hyperplastic thymus on chemical-shift MR imaging. *AJR Am J Roentgenol*. 2005, 180:1265-9. [10.2214/ajr.180.5.1801265](https://doi.org/10.2214/ajr.180.5.1801265)
 34. Feigin DS, Fenoglio JJ, McAllister HA, Madewell JE: Pericardial cysts. A radiologic-pathologic correlation and review. *Radiology*. 1977, 125:15-20. [10.1148/125.1.15](https://doi.org/10.1148/125.1.15)
 35. Shahriari A, Odell JA: Cervical and thoracic components of multiorgan lymphangiomatosis managed surgically. *Ann Thorac Surg*. 2001, 71:694-6. [10.1016/s0003-4975\(00\)02353-5](https://doi.org/10.1016/s0003-4975(00)02353-5)
 36. Choi SH, Kim L, Lee KH, Cho JH, Ryu JS, Kwak SM, Nam HS: Mediastinal lymphangioma treated using endobronchial ultrasound-guided transbronchial needle aspiration. *Respiration*. 2012, 84:518-21. [10.1159/000342872](https://doi.org/10.1159/000342872)
 37. Polansky SM, Barwick KW, Ravin CE: Primary mediastinal seminoma. *AJR Am J Roentgenol*. 1979, 132:17-21. [10.2214/ajr.132.1.17](https://doi.org/10.2214/ajr.132.1.17)
 38. Hosono M, Machida K, Honda N, et al.: Intense Ga-67 accumulation in pure primary mediastinal seminomas. *Clin Nucl Med*. 2003, 28:25-8. [10.1097/0003072-200301000-00006](https://doi.org/10.1097/0003072-200301000-00006)
 39. Lee YT, Lai LH, Sung JY, Ko FW, Hui DS: Endoscopic ultrasonography-guided fine-needle aspiration in the management of mediastinal diseases: Local experience of a novel investigation. *Hong Kong Med J*. 2010, 16:121-5.
 40. Ardengh JC, Bammann RH, Giovanni Md, Venco F, Parada AA: Endoscopic ultrasound-guided biopsies for mediastinal lesions and lymph node diagnosis and staging. *Clinics (Sao Paulo)*. 2011, 66:1579-85. [10.1590/s1807-59322011000900013](https://doi.org/10.1590/s1807-59322011000900013)
 41. Manucha V, Kaur G, Verma K: Endoscopic ultrasound-guided fine needle aspiration (EUS-FNA) of mediastinal lymph nodes: experience from region with high prevalence of tuberculosis. *Diagn Cytopathol*. 2013, 41:1019-22. [10.1002/dc.21698](https://doi.org/10.1002/dc.21698)
 42. Zeppa P, Barra E, Napolitano V, et al.: Impact of endoscopic ultrasound-guided fine needle aspiration (EUS-FNA) in lymph nodal and mediastinal lesions: a multicenter experience. *Diagn Cytopathol*. 2011, 39:723-9. [10.1002/dc.21450](https://doi.org/10.1002/dc.21450)
 43. Ikenberry S, Gress F, Savides T, Hawes R: Fine-needle aspiration of posterior mediastinal lesions guided by radial scanning endosonography. *Gastrointest Endosc*. 1996, 43:605-10. [10.1016/s0016-5107\(96\)70200-6](https://doi.org/10.1016/s0016-5107(96)70200-6)
 44. Kahaleh M, Yoshida C, Kane L, Yeaton P: EUS drainage of a mediastinal abscess. *Gastrointest Endosc*. 2004, 60:158-60. [10.1016/s0016-5107\(04\)01310-0](https://doi.org/10.1016/s0016-5107(04)01310-0)
 45. Jonas E, Josephson T: Endoscopic ultrasound-guided drainage of a cystic metastasis in the mediastinum that caused tracheal obstruction. *Endoscopy*. 2005, 37:273-4. [10.1055/s-2005-861013](https://doi.org/10.1055/s-2005-861013)
 46. Saxena P, Kumbhari V, Khashab MA: EUS-guided drainage of a mediastinal abscess. *Gastrointest Endosc*. 2014, 79:998-9. [10.1016/j.gie.2013.12.026](https://doi.org/10.1016/j.gie.2013.12.026)
 47. Kawaguchi Y, Hanaoka J, Asakura S, Fujita T: Infected bronchogenic cyst treated with drainage followed by resection. *Ann Thorac Surg*. 2014, 98:332-4. [10.1016/j.athoracsur.2013.09.070](https://doi.org/10.1016/j.athoracsur.2013.09.070)

48. Nakajima T, Yasufuku K, Shibuya K, Fujisawa T: Endobronchial ultrasound-guided transbronchial needle aspiration for the treatment of central airway stenosis caused by a mediastinal cyst. *Eur J Cardiothorac Surg*. 2007, 32:538-40. [10.1016/j.ejcts.2007.06.010](https://doi.org/10.1016/j.ejcts.2007.06.010)
49. Twehues A, Islam S: Cystic lesions of the thorax: role of endobronchial ultrasound-guided transbronchial needle aspiration. *J Bronchology Interv Pulmonol*. 2011, 18:265-8. [10.1097/LBR.0b013e3182281063](https://doi.org/10.1097/LBR.0b013e3182281063)
50. Alraiyes AH, Shaheen K, Reynolds J, Machuzak M: Recurrent bronchogenic cyst after surgical resection. *Ochsner J*. 2015, 15:176-9.
51. Li P, Zheng W, Liu H, Zhang Z, Zhao L: Endobronchial ultrasound-guided transbronchial needle aspiration for thyroid cyst therapy: a case report. *Exp Ther Med*. 2017, 13:1944-7. [10.3892/etm.2017.4213](https://doi.org/10.3892/etm.2017.4213)
52. Mohl W, Moser C, Kramann B, Zeuzem S, Stallmach A: Endoscopic transhiatal drainage of a mediastinal pancreatic pseudocyst. *Endoscopy*. 2004, 36:467. [10.1055/s-2004-814385](https://doi.org/10.1055/s-2004-814385)
53. Komtong S, Chanatrirattanapan R, Kongkam P, Rerknimitr R, Kullavanijaya P: Mediastinal pseudocyst with pericardial effusion and dysphagia treated by endoscopic drainage. *JOP*. 2006, 7:405-10.
54. Săftoiu A, Ciurea T, Dumitrescu D, Stoica Z: Endoscopic ultrasound-guided transesophageal drainage of a mediastinal pancreatic pseudocyst. *Endoscopy*. 2006, 38:538-9. [10.1055/s-2006-925229](https://doi.org/10.1055/s-2006-925229)
55. Trevino JM, Christein JD, Varadarajulu S: EUS-guided transesophageal drainage of peripancreatic fluid collections. *Gastrointest Endosc*. 2009, 70:793-7. [10.1016/j.gie.2009.05.023](https://doi.org/10.1016/j.gie.2009.05.023)
56. Mallavarapu R, Habib TH, Elton E, Goldberg MJ: Resolution of mediastinal pancreatic pseudocysts with transpapillary stent placement. *Gastrointest Endosc*. 2001, 53:367-70. [10.1016/s0016-5107\(01\)70421-x](https://doi.org/10.1016/s0016-5107(01)70421-x)
57. Bhasin DK, Rana SS, Rao C, et al.: Clinical presentation, radiological features, and endoscopic management of mediastinal pseudocysts: experience of a decade. *Gastrointest Endosc*. 2012, 76:1056-60. [10.1016/j.gie.2012.06.021](https://doi.org/10.1016/j.gie.2012.06.021)
58. Sugimoto S, Yamagishi Y, Higuchi H, Kanai T: Endoscopic ultrasound-guided drainage for a mediastinal pancreatic pseudocyst. *Intern Med*. 2014, 53:2651-2. [10.2169/internalmedicine.53.3503](https://doi.org/10.2169/internalmedicine.53.3503)
59. Mishra SK, Jain PK, Gupta S: Mediastinal pseudocyst in acute on chronic pancreatitis. *J Assoc Physicians India*. 2016, 64:80-1.
60. Takayanagi T, Sekino Y, Ishii K, et al.: [Successful endoscopic ultrasound-guided cyst drainage (EUS-CD) of pancreatic pseudocyst in the abdominal cavity to the cervical region accompanied by spontaneous rupture into the portal vein: a case study]. *Nihon Shokakibyō Gakkai Zasshi*. 2018, 115:219-27. [10.11405/nisshoshi.115.219](https://doi.org/10.11405/nisshoshi.115.219)
61. Dąbkowski K, Białek A, Kukla M, et al.: Mediastinal pancreatic pseudocysts. *Clin Endosc*. 2017, 50:76-80. [10.5946/ce.2016.089](https://doi.org/10.5946/ce.2016.089)
62. Pizzicannella M, Pandolfi M, Andrisani G, Signoretti M, Martino M, Rea R, Di Matteo FM: EUS-guided transesophageal drainage of a mediastinal necrotic fluid collection using the axios electrocautery enhanced delivery system™. *Scand J Gastroenterol*. 2019, 54:137-9. [10.1080/00365521.2019.1568542](https://doi.org/10.1080/00365521.2019.1568542)
63. Nakamura T, Masaki Y, Kawakami Y, Ishigami K, Murota A, Motoya M, Nakase H: [A case of mediastinal pancreatic pseudocyst diagnosed and treated successfully by endoscopic procedure]. *Nihon Shokakibyō Gakkai Zasshi*. 2021, 118:578-85. [10.11405/nisshoshi.118.578](https://doi.org/10.11405/nisshoshi.118.578)
64. Aritake T, Higaki E, Abe T, et al.: Bronchial fistula and esophageal stricture following endoscopic transgastric drainage for a mediastinal pancreatic pseudocyst. *Clin J Gastroenterol*. 2021, 14:466-70. [10.1007/s12328-021-01361-2](https://doi.org/10.1007/s12328-021-01361-2)
65. Inomata N, Sakai A, Abe S, Kodama Y: A case of mediastinal pancreatic pseudocysts mimicking esophageal varices with successful endoscopic drainage. *Dig Liver Dis*. 2022, 54:407-8. [10.1016/j.dld.2020.10.037](https://doi.org/10.1016/j.dld.2020.10.037)
66. Watanabe S, Toki M, Kambayashi K, et al.: Successful treatment of mediastinal pancreatic pseudocyst and pancreatic pleural effusion with endoscopic pancreatic duct drainage: a case report. *DEN open*. 2023, 3:e133. [10.1002/deo.2.133](https://doi.org/10.1002/deo.2.133)