

CASE REPORT



Minimally invasive bone grafting of simple cyst of the femoral head in femoroacetabular impingement.

Montoya C¹, Pomés J², Combalia A¹, Muñoz-Mahamud E¹

¹ Department of Orthopaedic Surgery and Department of Human Anatomy and Embriology, Hospital Clínic, Institut d'Investigació August Pi I Sunyer (IDIBAPS), Universitat de Barcelona, Spain. ² Department of Radiology, Hospital Clínic, Universitat de Barcelona, Spain.

Abstract

Femoral head and neck cysts are a common finding among patients with femoroacetabular impingement. However, their exact role in this pathology has not been yet clarified. We report herein the case of a 45-year-old male presenting with femoroacetabular impingement in which the treatment of a femoral simple bone cyst resolved the symptomatology.

Keywords

Femoroacetabular impingement, bone cyst.



Case Report

We present herein a 45 year-old caucasian male, professional water polo player with no relevant past medical history, who consulted for chronic left groin pain. Physical examination was compatible with an anterior femoroacetabular impingement syndrome in the left hip. Simple x-rays of the hip were performed, showing a radiolucent image surrounded by a sclerotic halo in the head-neck transition zone of the left femur (Figure 1.A).

A homogeneous, well-delimited cyst image associated to a cortical insufflation that produced a cam deformity was identified in the MRI (Figure 1.B) compatible with a simple bone cyst.

Bone curettage and high-speed burring of the cam deformity followed by bone graft supply (iliac bone autograft mixed with lyophilized allograft) of the cavity

was performed through a Röttinger intermuscular approach (Figure 1.C).

Weight bearing was delayed for 6 weeks after surgery. After 1 year follow-up, the patient had no symptoms at rest and while performing high-demanding impact activities, with a score of 100% in the Hip Outcome Score and 9 in the UCLA Activity Score. The patient returned to his water polo regular performance.

Discussion

Cystic changes in the femoral head or neck can be found up to 39% of femoral impingement syndrome according to the literature, although it remains unclear whether those cysts are the cause or the consequence of the hip disorder. Surgery of the cyst should be considered in those cases presenting a cyst of at least ≥ 15 mm and associated symptoms (1,2).

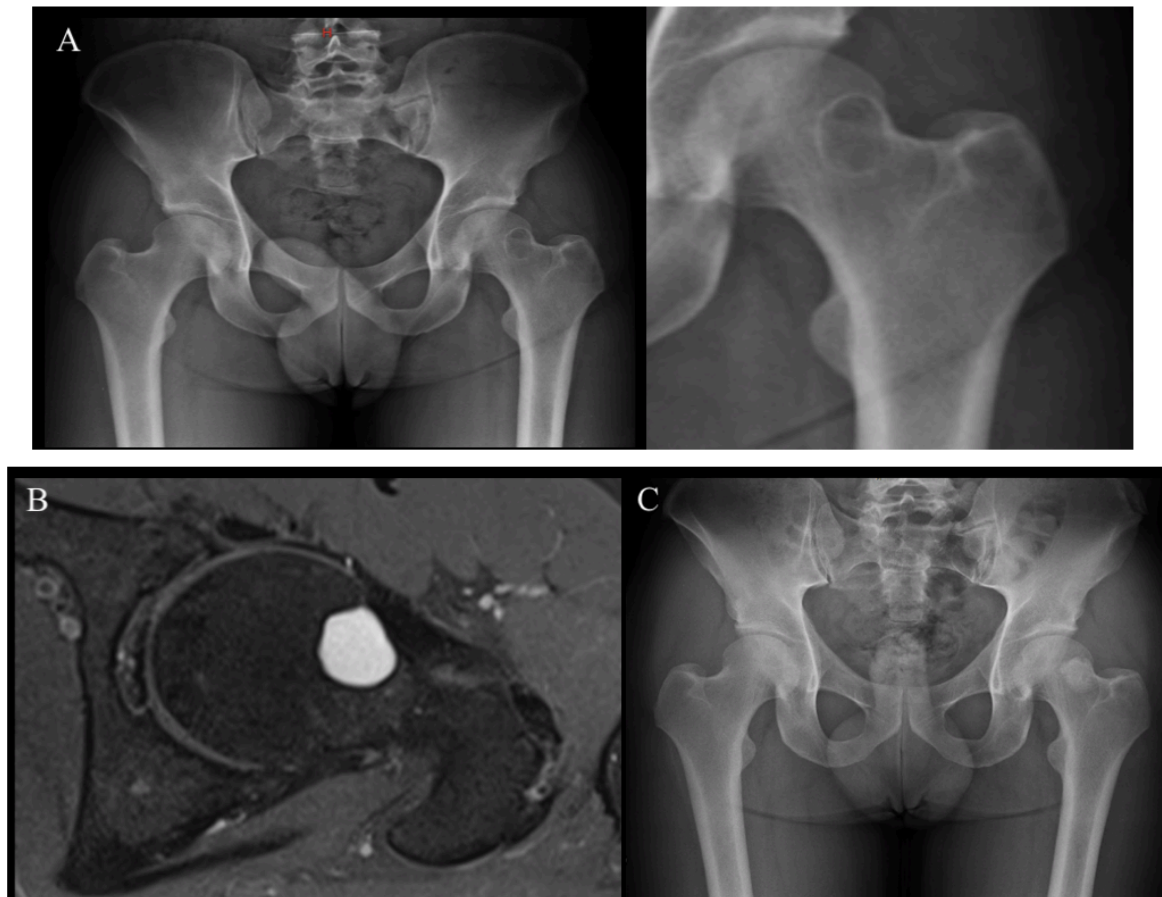


Figure 1. 1.A. Radiology of the pelvis, and on the left, a detail of the left hip. 1.B. MR image depicting a well limited bone cyst located in the transition from the left femoral head to the neck. 1.C. Postoperative result after bone cyst curettage and grafting.

Bone curettage, high-speed burring and bone graft supply seems to be a good treatment option for these cases. Identification of smaller cysts (3-15mm) as the cause of pain in a patient with femoroacetabular deformity is more difficult and the patient's clinical symptoms and physical examination should prevail over imaging findings. Arthroscopic curettage and bone filling through a catheter could be offered as a treatment in these cases or if another associate damage is previously identified (3,4,5).

References

1. Leunig M, Beck M, Kalhor M, Kim YJ, Werlen S, Ganz R. Fibrocystic changes at anterosuperior femoral neck: prevalence in hips with femoroacetabular impingement. *Radiology*. 2005;236(1):237-46.
2. Günther KP, Hartmann A, Aikele P, Aust D, Ziegler J. Large femoral-neck cysts in association with femoroacetabular impingement. A report of three cases. *J Bone Joint Surg Am*. 2007; 89(4):863-70.
3. Jamali AA, Fritz AT, Reddy D, Meehan JP. Minimally invasive bone grafting of cysts of the femoral head and acetabulum in femoroacetabular impingement: arthroscopic technique and case presentation. *Arthroscopy*. 2010;26(2):279-85.
4. Abdel-Mota'al MM, Othman Mohamad AS, Katchy KC et al. Management of unicameral bone cysts of proximal femur: experience of 14 cases and review of literature. *Kuwait Med J* 2008;40:202-10.
5. Nakamura T, Matsumine A, Asanuma K, Matsubara T, Sudo A. Treatment of the benign bone tumors including femoral neck lesion using compression hip screw and synthetic bone graft. *SICOT J*. 2015 Jun 26;1:15.

Copyright

Copyright © 2018 Montoya C et al. This is an open access article distributed under the [Creative Commons Attribution License](#), which permits unrestricted use, distribution, and reproduction in any medium, provided the original work is properly cited.

Conflicts of interest statement

The authors certify that they have no affiliations with or involvement in any organisation or entity with any financial interest, or non-financial interest in the subject matter or materials discussed in this manuscript.

How to cite

Montoya C, Pomés J, Combalia A, Muñoz-Mahamud E. Minimally invasive bone grafting of simple cyst of the femoral head in femoroacetabular impingement. Int J Adv Jt Reconstr. 2018; 5(2):33-35.