

Osteolytic metastasis detected by F18-FDG PET in a patient with lung carcinoma

González-Sistal, A¹; Baltasar Sánchez, A¹; Sánchez Salmón, A²; Ruibal Morell, A².

¹Medical Imaging Research Laboratory, Dpt. Physiological Sciences II, Faculty of Medicine, University of Barcelona, Spain. ²Nuclear Medicine Service, Complejo Hospitalario Universitario, Santiago de Compostela, Spain

We present a 53-year-old man with a vocal cord paralysis observed as a primary manifestation of lung carcinoma. Tc-99m MDP whole body bone scan were performed and resulted a normal scintiscan. The bone scan does not revealed suspicious foci of uptake. The possibility of bone metastasis was taken into consideration. A whole body F18-FDG-PET scan showed intense uptake in the left upper lung corresponding to the primary tumor. A bronchial biopsy confirmed infiltration by small cell lung carcinoma (SCLC). SCLC is composed of poorly differentiated, rapidly growing cells with disease usually occurring centrally rather than peripherally. It metastasizes early. The whole-body F18-FDG-PET scan clearly demonstrated a focus of increased uptake in the second lumbar vertebral body suspicious for osteolytic metastasis. A lytic bone metastasis was confirmed by MRI. The patient then received therapy and underwent follow up abdominal CT. The scan showed blastic changes in the L2 vertebra suggesting response to treatment.

This case is described in part in the paragraph of lung carcinoma (chapter 16):

Àngel González-Sistal, Alicia Baltasar Sánchez, Michel Herranz Carnero and Álvaro Ruibal Morell (2011). *Advances in Medical Imaging Applied to Bone Metastases*, Medical Imaging, Dr. Okechukwu Felix Erundu (Ed.), ISBN: 978-953-307-774-1.

DOI: <http://dx.doi.org/10.5772/28519>

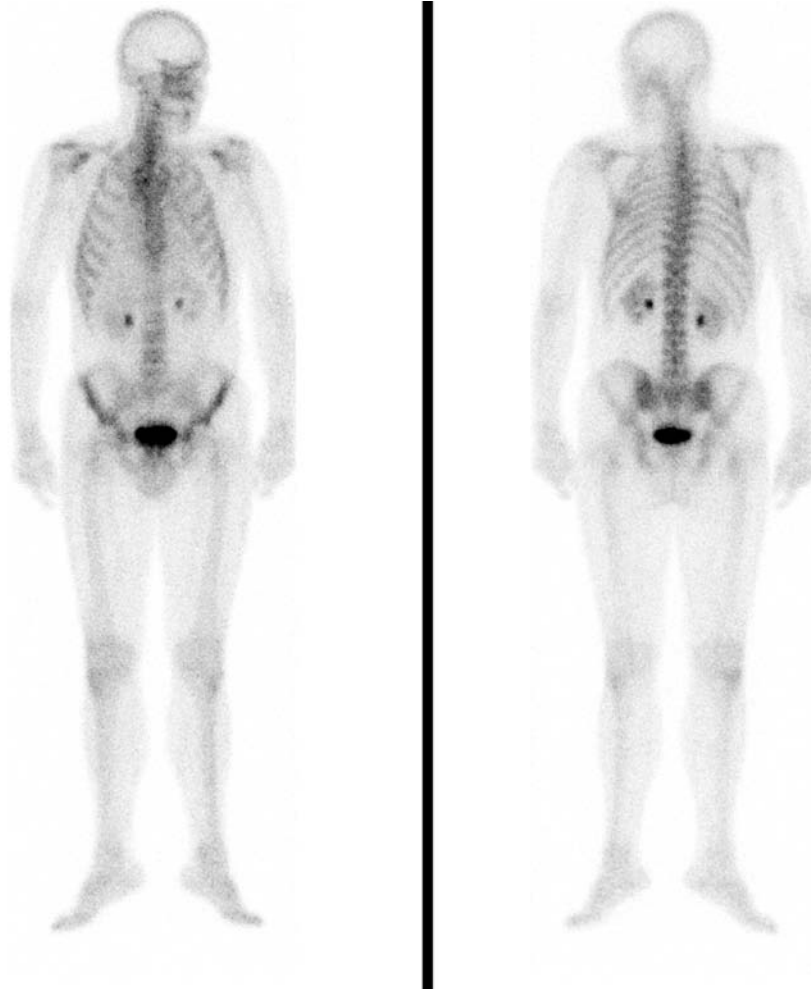


FIGURE 1. Bone scintigraphy is the method used to screen the whole body for bone metastasis in patients with malignancies. We present a 53-year-old man with a 4-month history of progressive dysphonia. Patient was referred to a consultant otolaryngologist for clinical examination. Vocal cord paralysis was observed as a primary manifestation of left upper lung carcinoma elucidated by chest radiograph.

Tc-99m MDP whole body bone scan were performed and resulted a normal scintiscan. The bone scan does not revealed suspicious foci of uptake. Bone metastasis develop in 30% of all patients with cancer. Bone metastases are usually located in the axial skeleton. Scintigraphy does not detect pure lytic metastasis when bone turnover is slow or when the site is avascular. The possibility of bone metastasis should be taken into consideration in patients with an underlying cancer history for avoiding delayed or misdiagnosis.

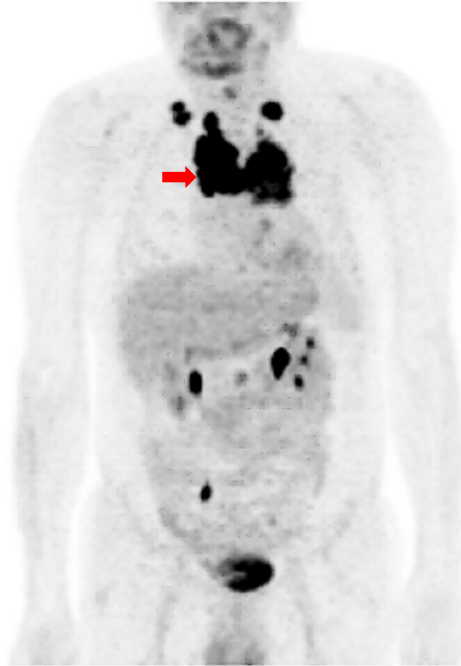

FIGURE 2. A whole body F18 fluorodeoxyglucose (FDG) PET scan showed intense uptake in the left upper lung corresponding to the primary tumor with a maximum standardized uptake value (SUV_{max}) of 19.7 (red arrow). Lung cancer was associated to paratracheal and subcarinal lymph nodes. Pathological lymph nodes are clearly demonstrated in clavicular regions (left SUV_{max} : 16.7; and right SUV_{max} :10.4). Bronchial biopsy of the upper left lobe confirmed infiltration by small cell lung carcinoma (SCLC). Cancer cells expressed: TTF1, CD56, p53, synaptophysin and chromogranin.

The two main histopathologic categories for lung malignancies are small cell lung cancer (SCLC) and non-small cell lung cancer (NSCLC). In both, its clinical behavior and treatment are different. SCLC accounts for the minority (14%) of a lung cancer cases and is composed of poorly differentiated, rapidly growing cells with disease usually occurring centrally rather than peripherally. It metastasizes early. Management for SCLC is nonsurgical, and therapy is via chemotherapy alone or in combination with radiotherapy.

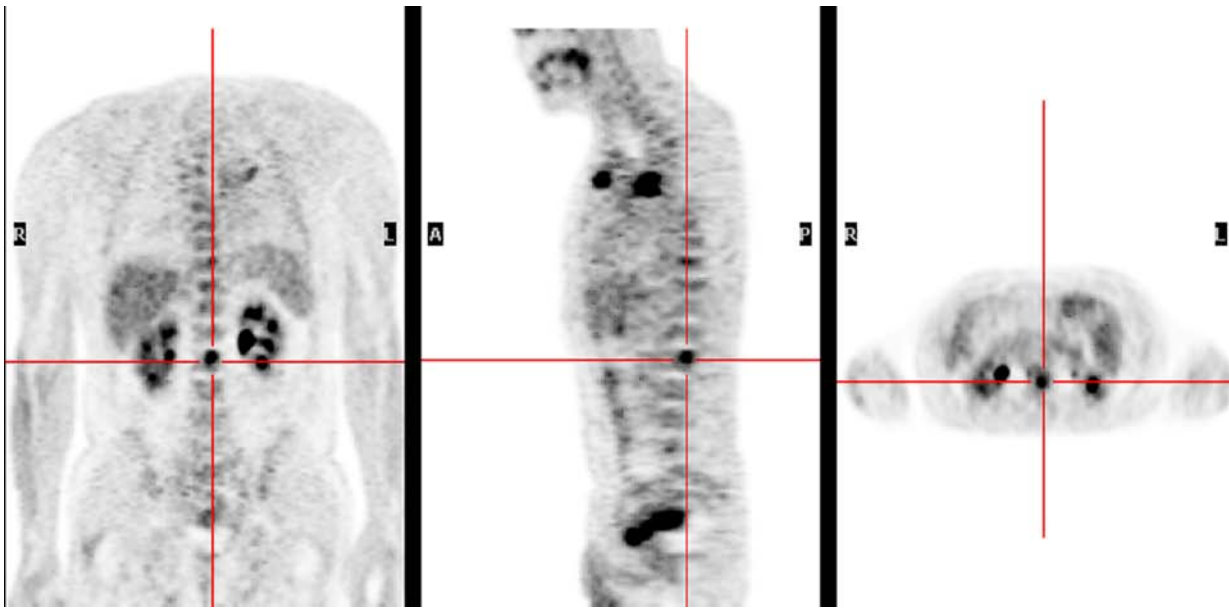
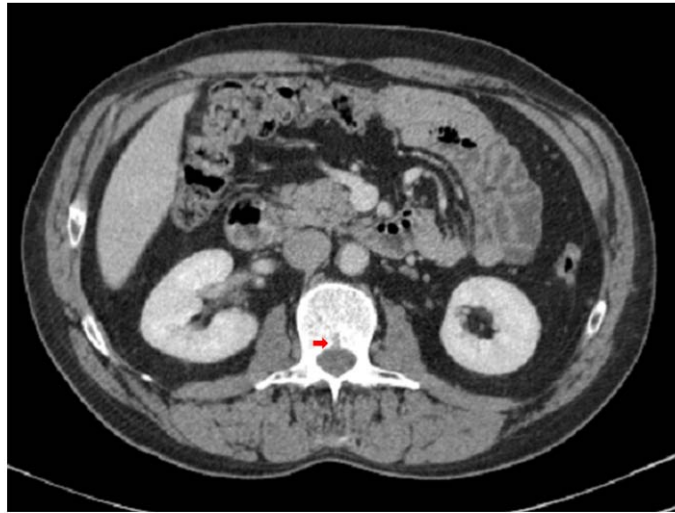


FIGURE 3. The whole-body F18 FDG PET scan clearly demonstrated a focus of increased uptake in the second lumbar vertebral body (red cross) which was suspicious for osteolytic metastasis and no other bony lesion was identified. An osteolytic bone metastasis was confirmed by MRI. Thus, FDG PET is useful for detecting osteolytic metastasis in patients with a malignancy. PET can be a sensitive modality for diagnosing and monitoring bone metastasis.

A)



B)

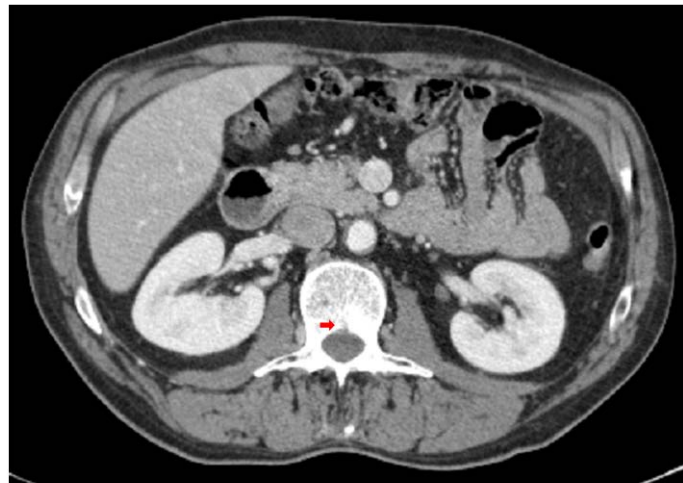


FIGURE 4. A) Selected axial slice of diagnostic abdominal CT scan, performed on March 8, 2011, showed the presence of oteolytic metastasis in L2 vertebra (red arrow). B) The patient received radiation therapy and chemotherapy. Four weeks later the patient underwent a second follow up CT, and the scan showed blastic changes in the posterior edge of the L2 vertebra (red arrow) suggesting response to treatment⁶. Bone metastases are well depicted on CT. But the usefulness of CT in detecting early deposits in bone marrow is limited. Although CT is superior to radiography some advanced destructive lesions on trabecular bone may not be visible in the absence of cortical bone involvement, so CT is less apparent than the marrow changes visualized on MRI. CT is also better than radiography and scintigraphy for depicting lesions in the spine and calvarium. CT is useful in guiding needle biopsy in bones such as vertebrae or ilia. When assessing the therapeutic response, sclerosis of a lytic metastasis on CT suggests a response to treatment. Notwithstanding, lysis or the appearance of new lysis or an increase in the size of blastic lesion represents a disease progression.

This work is licensed under a Creative Commons Attribution License, available at <http://creativecommons.org/licenses/by/3.0/>