

Case Report

Alveolar Bone Necrosis and Tooth Exfoliation Following Herpes Zoster Infection: A Review of the Literature and Case Report

C. Mendieta,* J. Miranda,* L.I. Brunet,* J. Gargallo,† and L. Berini†

Background: *Herpes zoster (HZ) presents as a cutaneous vesicular eruption in the area innervated by the affected sensory nerve, usually associated with severe pain. Oral manifestations of HZ appear when the mandibular or maxillary divisions of the trigeminal nerve are affected.*

Methods: *This is a case report of a 63-year-old woman with HZ infection with trigeminal nerve involvement that led to a rapid loss of alveolar bone and exfoliation of two teeth.*

Results: *The initial intraoral examination showed redness of the alveolar mucosa and gingiva of the lower right quadrant with multiple well-delimited and painful erosive lesions affecting the attached gingiva around the teeth. Two weeks later, teeth number 27 (lower right canine) and 28 (lower right first premolar) had class III mobility, flow of purulent exudate from the gingival sulcus, and deep pockets (>11 mm). The radiological examination showed advanced alveolar bone loss around both teeth. The prognosis for teeth number 27 and 28 was considered hopeless, and they were extracted. Due to extensive necrosis there was no interdental alveolar bone. The case is presented with a review of clinical data from patients with trigeminal HZ infection associated with osteonecrosis or exfoliation of teeth previously reported in the literature. The mechanisms by which the HZ infection leads to the alveolar bone necrosis are discussed.*

Conclusions: *Extensive osteonecrosis and exfoliation of teeth in the area innervated by the nerve affected by HZ has been reported after HZ infection. Clinicians should be aware of this possible outcome after a trigeminal HZ infection. J Periodontol 2005;76:148-153.*

KEY WORDS

Alveolar bone loss/etiology; herpes zoster; tooth loss/etiology; trigeminal nerve disease/etiology.

* Periodontics Unit, Dental Faculty, University of Barcelona, Barcelona, Spain.

† Oral Surgery Unit, Dental Faculty, University of Barcelona.

Varicella-zoster virus (VZV) causes two distinct clinical entities: varicella or chickenpox and herpes zoster (HZ) or shingles. Chickenpox, a ubiquitous and extremely contagious infection, is usually a benign illness of childhood characterized by an exanthematous vesicular rash. During the initial varicella infection, virus in the skin travels up the sensory nerves to become latent in the sensory ganglia. With reactivation of latent VZV, herpes zoster presents as a cutaneous vesicular eruption in the area innervated by the affected sensory nerve, usually associated with severe pain. The mechanisms that account for maintenance of latency and subsequent reactivation remain unknown. Reactivation results in active viral replication in sensory ganglia followed by spread of virus through nerves to the skin, and a vesicular cutaneous eruption develops in the area innervated by the affected sensory nerve.¹⁻³

The lesions are most commonly found in the thoracic dermatomes accounting for two-thirds of cases. The typical history is one of several days of itching, tingling, and burning, followed by a painful vesicular eruption along the course of the nerve. The vesicles become cloudy, dry, and crust over after 1 to 2 weeks. However, it may take as long as 2 to 4 weeks for the skin to return to normal.¹⁻³

When branches of the trigeminal nerve are involved, lesions may appear on the face, in the mouth, in the eye, or on the tongue. Oral manifestations of HZ appear when the mandibular or maxillary divisions of the trigeminal nerve are affected. Osseous alterations related to HZ infection were first reported by Rose⁴ in 1908, and Dechaume et al.⁵ credited Gonnet as the first, in 1922, to call attention to the alveolar bone necrosis and tooth loss associated with HZ infection. Since then, only a few cases have been reported on this rare complication. This is a case report of a patient with HZ infection of the trigeminal nerve, with neuralgia and ipsilateral hearing loss with mandibular nerve involvement that resulted in alveolar bone necrosis and rapid tooth exfoliation.¹⁻³

CASE REPORT

The patient, a 63-year-old woman previously diagnosed with HZ, was admitted to the Dental Clinic of the

University of Barcelona for diagnosis and treatment of pain of several weeks duration in the upper right lateral incisor. At the time of examination the patient had neuralgia and ipsilateral hearing loss related to the HZ infection involving the right mandibular division of the trigeminal nerve. A large erythematous zone with multiple coalescing vesicular and crusting lesions was present on the skin of the right mandible and the inferior lip (Fig. 1). The intraoral examination showed redness of the alveolar mucosa and gingiva of the lower right quadrant with multiple well-delimited and painful erosive lesions affecting the attached gingiva around the teeth. The HZ infection began 11 days earlier with typical itching and paresthetic sensation. This was followed 3 days later by the appearance of vesicles on an erythematous zone affecting the skin of the right mandible. The patient was being treated in another center with oral (800 mg/daily for 10 days) and topical acyclovir for the HZ infection. She was also on treatment with carbamazepine for the trigeminal nerve involvement. The intraoral examination showed a cervical caries lesion on tooth number 7, early caries lesions in molars of the fourth quadrant, and generalized gingivitis and early lesions of chronic periodontitis. The patient was instructed to rinse with 0.12% chlorhexidine digluconate three times daily, and dental treatment was delayed until the resolution of the HZ infection.

The patient was seen again two weeks later. The skin of the right mandible showed residual crusty lesions of the HZ infection. After almost a month under carbamazepine treatment (200 mg b.i.d.) the neuralgia had improved, but an audiometric evaluation revealed a 95% hearing loss in the right ear. The patient described increased mobility of teeth in the lower right

quadrant. The intraoral examination showed redness of the gingiva and alveolar mucosa with residual lesions. Upon dental examination, loosening of teeth number 27 (lower right canine) and 28 (lower right first premolar) with class III mobility, flow of purulent exudate from the gingival sulcus, and deep pockets (>11 mm) around both teeth were detected. Teeth number 26 (lower right lateral incisor) and 29 (lower right second premolar) had class II mobility, and there were no alterations in the remaining teeth of the lower right quadrant. The radiological examination showed advanced alveolar bone loss around teeth number 27 and 28 (Figs. 2 and 3).

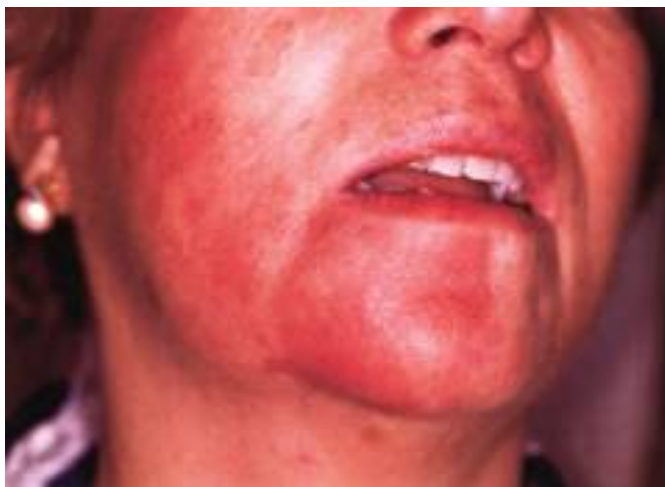
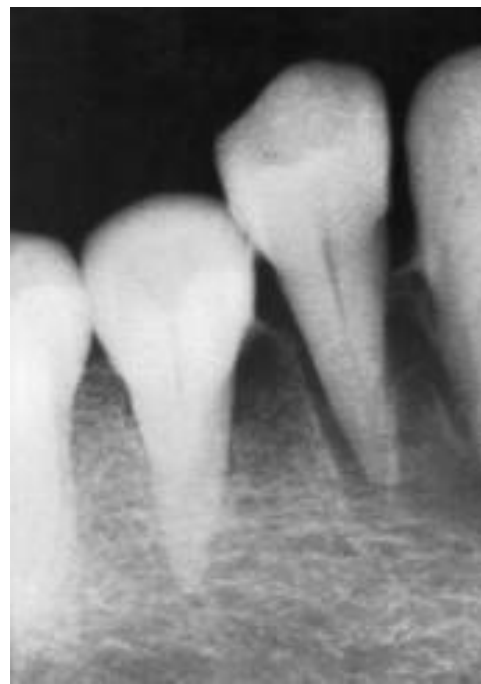
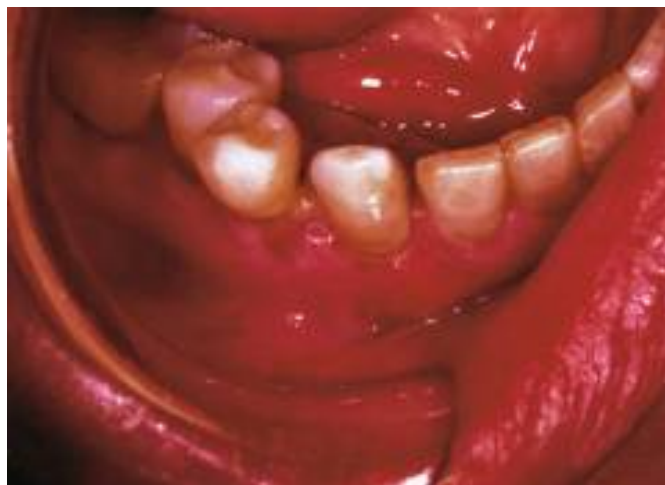Figure 1.

Skin lesions at the time of admission 11 days after the onset of the herpes zoster infection.



Figures 2 and 3.

Intraoral view and radiographic appearance of involved teeth 3 weeks after the onset of vesicular eruption.

The prognosis for teeth number 27 and 28 was considered hopeless and they were extracted. Due to extensive necrosis, there was no interdental alveolar bone (Fig. 4). At the time of removal, fragments of necrotic alveolar bone were meticulously removed. Specimens of tissue from the extraction socket and adjacent buccal and lingual gingiva were taken and sent for histopathologic examination. The soft tissue sections showed presence of non-specific granulation tissue. There were no signs of malignancy, viral infection, or vasculitis. The patient was placed on antibiotic therapy (amoxicillin 500 mg, three times daily for 10 days) and was instructed to rinse with 0.12% chlorhexidine digluconate. During the postoperative period an oral surgeon, a periodontist, and other dental staff treated the patient.

Six weeks later the intraoral lesions had resolved completely. Teeth number 26 and 29 had class I mobility and periodontal lesions in the rest of dentition were controlled. Radiographic examination showed advanced alveolar bone loss in the extraction sockets previously occupied by teeth number 27 and 28. Post-herpetic neuralgia had disappeared completely, while the hearing loss had slightly improved (75% in the right ear). The patient had a circular scar that appeared as a hyperpigmented area of about 4 cm on the skin of the right mandible.

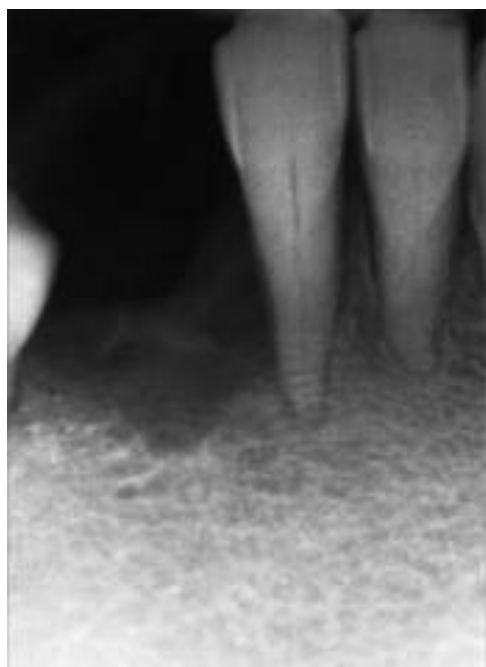


Figure 4.

View of alveolar sockets. Note that both sockets appear as a single one due to the total necrosis of the interdental alveolar bone.

DISCUSSION

The incidence of HZ infection in the general population has been reported to be 5.4%.⁶ HZ occurs at all ages, but it is rare in children and adolescents,⁷ it usually appears in individuals older than 45 years of age,⁸⁻¹⁰ its incidence is highest (five to 10 cases per 1,000 persons) among individuals in the sixth through the eighth decades of life, and it is slightly more frequent in males.⁸ The increased frequency of HZ infection in individuals with AIDS syndrome has shifted the incidence towards male and younger individuals.⁹ It can develop after situations of stress¹¹ or local trauma, but it is more frequently associated with situations of diminished immune response as in individuals under systemic corticosteroid treatment, cytostatic chemotherapy, immunosuppressive agents, or radiotherapy, or it is associated with malignancies like chronic lymphocytic leukemia and lymphomas.^{10,12-16} It has been suggested that approximately 2% of patients with HZ will develop a second episode of the infection.^{1,2}

HZ infection may affect cranial nerves, and the trigeminal nerve is the most frequently affected (18.5% to 22% of total cases), followed by glossopharyngeal nerve and hypoglossal nerve.⁸ Trigeminal nerve involvement is usually unilateral^{17,18} and limited to a single division, more often the first (ophthalmic).¹⁹ Oral manifestations appear when the second (maxillary) or third (mandibular) trigeminal divisions are affected. Frequently, the intraoral lesions are associated, as in our case, with cutaneous lesions affecting the corresponding area innervated by the affected sensory nerve. Although some cases may start with paresthesia of the mental nerve,¹⁴ the typical history is one of several days of itching or burning pain along the course of the nerve that, 3 to 4 days after, is followed by the appearance of a cutaneous eruption with clear vesicles on a distinct erythematous base. The vesicles dry and crust over after 1 to 2 weeks, but it may take several weeks for the skin to return to normal. The skin lesions usually precede the intraoral mucosa lesions¹⁴ and very rarely the skin appears free of lesions.¹⁻³ The intraoral vesicles, scattered and surrounded by an erythematous zone, soon become ulcerated and covered by a white pseudomembrane.^{8,12,14,20} The patient may have general malaise, and lymphadenopathies in the submandibular region may be present.^{5,12,17}

Spontaneous exfoliation of teeth in the area innervated by the affected nerve has been reported. Some authors believe that this is an early event occurring during the first 2 weeks of the infection,^{12-15,21} while others consider this to be a late complication that will occur between the third to twelfth week after the onset.²² Loss of teeth is due to alveolar bone necrosis and/or to necrosis of the periodontal ligament.¹² After tooth extraction, healing of the periodontal tissues is usually

slower than normal, and frequently fragments of necrotic bone remaining after the extraction need to be removed^{5,13-15,20,23} to preserve the height of the alveolar process.^{14,21} In our case the teeth were extracted due to extreme mobility 4 weeks after the onset of the HZ infection. Bone sequestra were removed at the time of surgery.

The most debilitating complication of HZ is pain associated with acute neuritis and post-herpetic neuralgia. Post-herpetic neuralgia is almost never seen in children who develop HZ and is uncommon (6%) in adults younger than 50, but about 45% of patients over age 50 report some degree of pain in the involved dermatome for more than 6 weeks after the disappearance of the rash.² Trigeminal neuralgia, also known as tic douloureux, is usually of idiopathic nature but it may be a complication of HZ infection.^{1,24} Carbamazepine is the drug of choice for the treatment of trigeminal neuralgia and is effective initially in 75% of cases.^{2,25,26} Even though it has been reported that early administration of acyclovir will reduce the length of the cutaneous rash and the intensity of pain,^{9,17,18,20,27,28} it has not been shown to result in a significant decrease in the incidence of post-herpetic neuralgia.²

Six months after the onset of the HZ infection, our patient still had a 75% hearing loss. Reactivation of virus in the geniculate ganglion is reported to produce the Ramsay-Hunt syndrome, consisting of facial palsy often associated with loss of taste in the anterior tongue, tinnitus, hearing loss, vertigo, and zoster eruptions found in the auditory meatus.¹ In this case the patient did not have the facial palsy or the loss of taste associated with the syndrome, and symptoms were reduced to the area innervated by the inferior alveolar nerve, mental nerve, and buccal nerve. The hearing loss may be related to concomitant involvement of the chorda tympani nerve. The occurrence of disseminated lesions in non-compromised patients is not unusual; a degree of generalization occurred in 33% of 88 subjects without cancer.^{29,30} It has been postulated that viremia accompanies ganglionic replication, accounting for the commonly observed disseminated lesions.^{29,30}

Table 1 summarizes clinical data from patients with trigeminal herpes zoster associated with osteonecrosis or exfoliation of teeth. A review of these previously reported cases shows an age range between 6 and 85 years; four were younger than 40 years, eight were between 40 and 60 years of age, and eight were older than 60 years. There was a similar prevalence for the maxilla (n = 9; 33 teeth lost) and the mandible (n = 11; 33 teeth lost). Of the teeth lost, 31 were anterior teeth, while 30 were posterior teeth (one study³⁴ did not specify the location of lost teeth). The number of teeth lost ranged from none to seven. Not all cases reported on

the gender of the individuals, but available data showed more females (N = 9) than males (N = 7) affected. Ten of the published cases did not report on concomitant systemic diseases. Eight patients had either a severe condition or were under chemotherapy treatment for malignancies. It is difficult to ascertain to which degree these systemic diseases may have contributed to the severity of the alveolar bone destruction. Our patient did not have any known severe disease problem.

The mechanisms by which the HZ infection leads to the alveolar bone necrosis are not well known. It has been suggested^{21,35} that preexisting pulpal or periodontal inflammatory conditions or surgical procedures performed in the site of a zoster infection have the potential to contribute to more destructive alveolar bone necrosis. Our patient did not have pulpal pathologic conditions in the affected teeth and, although she had gingivitis and early lesions of chronic periodontitis that may have contributed to the severity of the destruction, the case may be that, as it has been suggested previously,³⁸ a vasculitic component related to the HZ infection contributed to an obliteration of the vessels supplying the right mandible. Wright et al.³⁵ postulated that the necrosis could be the result of ischemia related to an infarction of vessels supplying the teeth. Direct invasion of blood vessels by virus spreading from adjacent cranial nerves³⁶ and segmental granulomatous vasculitis, associated with HZ infection, with multifocal infarcts in the brain and spinal cord³⁷ have been reported. Therefore, it has been suggested^{35,38} that, considering the close anatomical relationship between virus-infected fifth cranial nerve branches and blood vessels, this vasculitic component may contribute to the infarction of the vessels. Probably an ischemic problem with these characteristics would result in more than one tooth affected. Of interest to mention is that in 12 of the published reports, a minimum of three teeth were lost and in four of these cases (three involving the maxilla; one involving the mandible), all seven teeth of the affected quadrant were lost. In five of the published cases, no teeth were lost, and in only one a single tooth was lost (Table 1).

Varicella-zoster and the herpes simplex virus are similar ultrastructurally and induce similar histopathologic responses.²⁹ Herpes simplex virus may produce segmentally focal lesions that resemble zoster,²⁹ and both VZV and herpes simplex have been isolated from patients with varicella.³⁹ A herpesvirus co-infection may accelerate the rate of periodontal breakdown through a reduction of periodontal defense mechanisms. This, in turn, could favor the growth of subgingival periodontopathic bacteria.⁴⁰⁻⁴² Therefore, the understanding of the significance of these viruses in the pathogenesis of periodontal diseases deserves further investigation.

Table 1.

Summary of Published Data From Patients With Trigeminal Herpes Zoster Infection Associated With Osteonecrosis or Exfoliation of Teeth (chronological sequence)*

Reference	N Patients	Age	Gender	Systemic Disease/Treatment	Site of Necrosis	N Teeth Lost
Dechaume et al. 1955 ⁵	1	48	M	Chronic hepatitis, anemia, leukopenia	L. mandible	5 (18, 19, 20, 22, 23)
Delaire & Billet 1959 ²³	2	71	F	NP†	R. mandible	1 (29)
		79	F	NP	R. mandible	6 (25 to 30)
Hall et al. 1974 ²²	1	62	F	Reticulum cell sarcoma (nasopharynx); radiation therapy	R. maxilla	7 (2 to 8)
Chemitz 1976 ³¹	1	15	M	Disseminated Hodgkin's, stage IV-B; chemo/radiation therapy	L. maxilla	4 (10 to 13)
Vickery & Midda 1976 ³²	1	41	F	Disseminated Hodgkin's, stage IV-B; chemotherapy	L. mandible	7 (18 to 24)
Cooper 1977 ²¹	2	76	M	No major illness	L. maxilla	3 (11, 12, 13)
		85	M	NP	R. mandible	5 (25 to 29)
Dielert 1979 ³³	1	73	M	NP	Mandible	0
Delbrouck-Poot & Reginster 1979 ³⁴	1	44	M	Hodgkin's disease	R. maxilla	Five (?)
Schwartz & Kvorning 1981 ¹⁴	1	66	F	No major illness	R. mandible	4 (25 to 28)
Wright et al. 1983 ³⁵	1	56	F	Histiocytic lymphoma, stage IV-B; chemo/radiation therapy	L. maxilla	7 (9 to 15)
Mostofi et al. 1987 ¹³	1	56	NP	Leukemia; chemotherapy	R. mandible	3 (25 to 27)
Toshitaka et al. 1990 ¹²	1	72	NP	NP	R. mandible	2 (25, 26)
Mckenzie et al. 1990 ¹⁸	2	21	F	NP	R. maxilla	0
		22	F	NP	R. maxilla/mandible	0
Consolaro et al. 1990 ¹¹	1	46	NP	NP	NP	0
Peñarrocha et al. 1992 ²⁰	1	50	M	NP	R. maxilla	7 (2 to 8)
Eury et al. 1993 ¹⁷	1	6		NP	Maxilla	0
Tidwell et al. 1999 ²⁸	1	59	F	Brain tumor	L. mandible	0

* Modified and updated from Wright et al.³⁵

† Not provided.

REFERENCES

1. Tyler KL. Aseptic meningitis, viral encephalitis, and prion diseases. In: Fauci AS, Braunwald E, Isselbacher KJ, et al., eds. *Harrison's Principles of Internal Medicine*, 14th ed. New York: McGraw-Hill; 1998:2439-2451.
2. Martin JB, Beal MF. Disorders of the cranial nerves. In: Fauci AS, Braunwald E, Isselbacher KJ, et al., eds. *Harrison's Principles of Internal Medicine*, 14th ed. New York: McGraw-Hill; 1998:2377-2381.
3. García San Miguel J. Herpesvirus infections (in Spanish). In: Farreras P, Rozman C, eds. *Internal Medicine*. Barcelona: Doyma; 1989:2306-2310.
4. Rose F. Postherpetic neuralgia; trophic lesions in hand's bones similar to rheumatoid arthritis (in French). *Nouvelle Iconogr de la Salpêtrière, Soc Neurol* 1908;Jan 9:64.
5. Dechaume M, Descrozailles C, Garlopeau F, Robert J. Localized mandibular necrosis during herpes zoster infection (in French). *Rev Stomatol* 1955;56:516-521.
6. Hope-Simpson RE. The nature of herpes zoster. A long-term study and new hypothesis. *Proc R Soc Med* 1965; 58:9-20.
7. Schimpff S, Serpick A, Stoles B, et al. Varicella-zoster infection in patients with cancer. *Ann Intern Med* 1972; 76:241-254.
8. Hornstein OP, Gorlin RJ. Oral infectious diseases. In: Gorlin RJ, Goldman HM, eds. *Thoma's Oral Pathology*. Barcelona: Salvat; 1973:822-824.
9. Eversole LR. Viral infections of the head and neck among HIV-seropositive patients. *Oral Surg Oral Med Oral Pathol* 1992;73:155-163.

10. Beck JD, Watkins C. Epidemiology of nondental disease in elderly. *Clinics Geriat Med* 1992;8:461-482.
11. Consolaro A, Oliveira DT. Oral and cutaneous manifestations of herpes zoster: A case report (in Portuguese). *Rev Odontoestomatol USP* 1990;4:349-352.
12. Toshitaka M, Tsuchiya H, Sato K, Kanazawa M. Tooth exfoliation and necrosis of the mandible – a rare complication following trigeminal herpes zoster: Report of a case. *J Oral Maxillofac Surg* 1990;48:1000-1003.
13. Mostofi R, Marchmont-Robinson H, Freije S. Spontaneous tooth exfoliation and osteonecrosis following a herpes zoster infection of the fifth cranial nerve. *J Oral Maxillofac Surg* 1987;45:264-266.
14. Schwartz O, Kvorning A. Tooth exfoliation, osteonecrosis of the jaw and neuralgia following herpes zoster of the trigeminal nerve. *Int J Oral Surg* 1982;11:364-371.
15. Shira RB. Necrosis of maxilla in patient with herpes zoster. *Oral Surg Oral Med Oral Pathol* 1974;37:657-662.
16. Dolin R, Reichman RC, Mazur MH, Whitley RJ. Herpes zoster-varicella infections in immunosuppressed patients. *Ann Intern Med* 1978;89:375-388.
17. Eury J, Gilain L, Peynegre R. Oral manifestations of zona. A case report (in French). *Ann Otolaryng* 1993;110:170-172.
18. Mckenzie CD, Gobetti JP. Diagnosis and treatment of orofacial herpes zoster: Report of cases. *J Am Dent Assoc* 1990;120:679-681.
19. Tyldesley WR, Field EA. Infections of the oral mucosa. In: Tyldesley WR, Field EA, eds. *Oral Medicine*. Oxford: Oxford University Press; 1997:46-48.
20. Peñarrocha M, Bagán JV, Sanchís JM. Herpes zóster and maxillary osteonecrosis (in Spanish). *Rev Actual Odontoestomatol Esp* 1992;418:49-55.
21. Cooper JC. Tooth exfoliation and osteonecrosis of the jaw following herpes zoster. *Br Dent J* 1977;143:297-300.
22. Hall HD, Jacobs JS, O'Malley JP. Necrosis of maxilla in a patient with herpes zoster. *Oral Surg Oral Med Oral Pathol* 1974;37:657-662.
23. Delaire J, Billet J. New observations of alveolar necrosis during a zona of the mandibular nerve (in French) *Rev Stomatol* 1959;60:550-553.
24. Nally FF, Ross IH. Herpes zoster of the oral and facial structures. *Oral Surg Oral Med Oral Pathol* 1971;32:221-234.
25. Sindrup SH, Jensen TS. Efficacy of pharmacological treatments of neuropathic pain: An update and effect related to mechanism of drug action. *Pain* 1999;83:389-400.
26. Backonja MM. Use of anticonvulsants for treatment of neuropathic pain. *Neurology* 2002;59(Suppl. 2):S14-S17.
27. Scully C, McCarthy G. Management of oral health in persons with HIV infection. *Oral Surg Oral Med Oral Pathol* 1992;73:215-225.
28. Tidwell E, Hutson B, Burkhart N, Gutmann JL, Ellis CD. Herpes zoster of the trigeminal nerve third branch: A case report and review of the literature. *Int Endod J* 1999;32:61-6.
29. Weller TH. Varicella and herpes zoster. Changing concepts of the natural history, control and importance of a not-so-benign virus. Part I. *N Engl J Med* 1983;309:1362-1365.
30. Weller TH. Varicella and herpes zoster. Changing concepts of the natural history, control and importance of a not-so-benign virus. Part II. *N Engl J Med* 1983;309:1434-1440.
31. Chemitz JE. Herpes zoster in Hodgkin's disease: Unusual oral sequelae. *J Dent Child* 1976;43:181-186.
32. Vickery IM, Midda M. Dental complications of cytotoxic therapy in Hodgkin's disease. *Br J Oral Surg* 1976;13:282-288.
33. Dielert E. Clinical features of herpes zoster and pathogenesis of cranial nerves involvement (in German). *Schw Mschr Zahnheilk* 1979;89:135-145.
34. Delbrouck-Poot F, Reginster JP. Trigeminal herpes zoster and maxillary necrosis. *Dermatologica* 1979;158:210-213.
35. Wright WE, Davis ML, Geffen DB, et al. Alveolar bone necrosis and tooth loss: A rare complication associated with herpes zoster infection of the fifth cranial nerve. *Oral Surg Oral Med Oral Pathol* 1983;56:39-46.
36. Linneman CC, Alvira MM. Pathogenesis of varicella-zoster angiitis in the CNS. *Arch Neurol* 1980;37:239-240.
37. Ferguson RH. Vasculitis associated with herpes zoster. *Mayo Clin Proc* 1981;56:524-525.
38. Garty B, Dinari G, Sarnat H, Cohen S, Nitzan M. Tooth exfoliation and osteonecrosis of the maxilla after trigeminal herpes zoster. *J Pediatr* 1985;106:71-73.
39. Landry MJ, Hsiung GD. Diagnosis of dual herpes virus infection: Varicella and herpes simplex viruses. In: Nahmias AJ, Dowdle WR, Schinazi RF, eds. *The Human Herpesviruses: An Interdisciplinary Perspective*. New York: Elsevier; 1981:652-653.
40. Contreras A, Úmeda M, Chen C, Bakker I, Morrison JL, Slots J. Relationship between herpesviruses and adult periodontitis and periodontopathic bacteria. *J Periodontol* 1999;70:478-484.
41. Hanookai D, Nowzari H, Contreras A, Morrison JL, Slots J. Herpesviruses and periodontopathic bacteria in trisomy 21 periodontitis. *J Periodontol* 2000;71:376-384.
42. Kamma JJ, Contreras A, Slots J. Herpes viruses and periodontopathic bacteria in early-onset periodontitis. *J Clin Periodontol* 2001;28:879-885.

Correspondence: Dr. Carlos Mendieta, Facultat d'Odontologia, Universitat de Barcelona, Feixa Llarga, s/n, 08830 L'Hospitalet de Llobregat, Spain. E-mail: cmendieta@ub.edu.

Accepted for publication April 23, 2004.