

ACUTE CORONARY SYNDROME

MGuard Mesh-Covered Stent for Treatment of ST-Segment Elevation Myocardial Infarction with High Thrombus Burden Despite Manual Aspiration

RAFAEL ROMAGUERA, M.D., JOAN A. GÓMEZ-HOSPITAL, M.D., Ph.D.,
GUILLERMO SÁNCHEZ-ELVIRA, M.D., JOSEP GÓMEZ-LARA, M.D., Ph.D.,
JOSÉ L. FERREIRO, M.D., GERARD ROURA, M.D., MONTSERRAT GRACIDA, M.D.,
SILVIA HOMS, M.D., LUIS TERUEL, M.D., and ÁNGEL CEQUIER, M.D., Ph.D.

From the Heart Diseases Institute, Bellvitge University Hospital-IDIBELL, University of Barcelona, Barcelona, Spain

Objectives: To assess the usefulness of the MGuard stent in patients with ST-segment elevation myocardial infarction (STEMI) in whom a high thrombus burden persists after manual aspiration.

Background: In some patients with STEMI, a high thrombus burden may persist after manual aspiration. These patients may be at high risk of distal embolization and therefore impaired myocardial reperfusion. The MGuard is a novel mesh-covered stent designed to minimize thrombus embolization.

Methods: Single-arm, prospective registry of patients with STEMI and high thrombus burden after aggressive thrombus aspiration treated with the MGuard stent. High thrombus burden was defined as thrombus burden grade 4 or 5 according to the TIMI score. Lesions with a side branch ≥ 2 mm and patients with cardiogenic shock were not included. The study end-points were proportion of final TIMI 3 flow, normal myocardial blush, and complete ST-segment resolution.

Results: Fifty-six patients were included. After MGuard stent implantation $>85\%$ of cases had thrombus score = 0. Final TIMI 3 flow was achieved in 82% of cases, normal myocardial blush in 55%, and complete ST-segment resolution in 59%. Occlusion of a side branch (<2 mm) occurred in 2 cases (3.5%), embolization to a distal branch in 5 cases (8.9%), and transient no-reflow in 4 cases (7.1%). Major adverse cardiac events rate at 9 months was 3.6%, including 1 definite acute stent thrombosis and 1 target-vessel revascularization.

Conclusions: The MGuard stent may be useful to prevent distal embolization in patients with STEMI and high thrombus burden despite mechanical aspiration. (J Intervent Cardiol 2013;26:1–7)

Introduction

In patients with ST-segment elevation myocardial infarction (STEMI), distal embolization during percutaneous coronary intervention (PCI) is a common complication that may cause impaired myocardial reperfusion even with a patent epicardial vessel.^{1,2} The MGuard™ stent (InspireMD, Tel Aviv, Israel) is a novel mesh-covered stent that has been designed to

prevent thrombus fragmentation and distal embolization during stent implantation.³ Although the MGuard stent has been shown to be safe and effective in consecutive patients with STEMI, its use in selected patients with persistent high thrombus burden after thrombus aspiration has not been described.

Methods

Study Design. This was a single-arm, prospective registry in which all patients undergoing PCI with thrombus aspiration and MGuard mesh-covered stent implantation from July 2010 to October 2011 were evaluated. The criteria for MGuard stent implantation

Address for reprints: Rafael Romaguera, M.D., Hospital Universitari de Bellvitge, Feixa llarga s/n, 08907 L'Hospitalet de Llobregat, Barcelona, Spain. Fax: +34-932607541; e-mail: rafaromaguera@gmail.com

were: (1) myocardial infarction with persistent chest pain (onset of ≥ 30 minutes and ≤ 24 hours) and ST-segment elevation of ≥ 2 mm in 2 or more contiguous electrocardiographic leads; (2) evidence on coronary angiogram of high thrombus burden after aggressive mechanical aspiration, defined as thrombus grade 4–5 according to the TIMI score⁴; and (3) vessel diameter ≥ 2.5 and ≤ 4 mm by visual estimation. The exclusion criteria for MGuard stent implantation were: (1) involvement of a side branch ≥ 2 mm within the culprit lesion; and (2) severe calcification of target lesion. Patients with cardiogenic shock at presentation were not included in the analysis. The study was approved by our local institutional review board. Informed written consent for all procedures was obtained.

Study Device. The MGuard stent consists of a balloon-expandable cobalt–chromium alloy bare metal stent (the first generation of the device was a stainless steel stent) with a polyethylene terephthalate microfiber sleeve attached to its outer surface (Fig. 1). The net, although porous, appears to effectively act as a mechanical barrier decreasing or even preventing the thrombus protrusion and embolization to the distal vessel (Fig. 2). Stent diameters 2.5–4.0 mm and stent lengths 18–38 mm were available during the study period.

Procedure. Thrombus aspiration was performed with the 6-French Export™ Aspiration Catheter (Medtronic, Minneapolis, MN, USA) or with the 6-French Pronto V3™ Aspiration Catheter (Vascular Solutions, Minneapolis, MN, USA). Thrombus aspiration was repeated until no new macroscopic thrombus

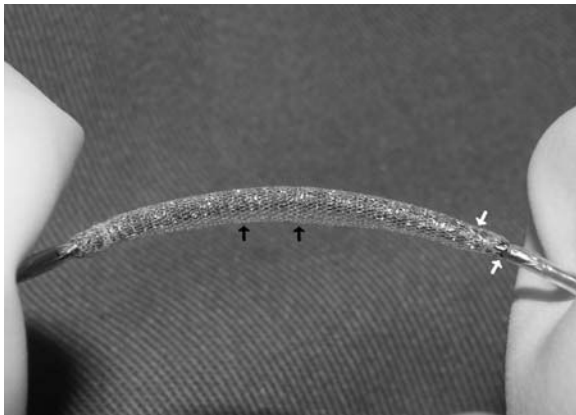


Figure 1. MGuard stent crimped onto a balloon. Black arrows indicate the mesh sleeve. White arrows indicate the metallic platform.

was obtained. Aspirated material was fixed in formalin, cut, stained with hematoxylin–eosin and examined with a light microscope. The aspiration was defined as effective or not effective on the basis of the presence of atherothrombotic material in the aspirate. The material was classified as thrombus containing platelets/erythrocytes or thrombus with plaque as previously described.⁵

After restoring the antegrade flow, intracoronary nitrates were given to ensure maximal epicardial vasodilation before determining the stent diameter. Direct stent implantation with no pre-dilatation was encouraged, unless moderate calcification was observed. Antiplatelet treatment before PCI included aspirin 300 mg and clopidogrel 300–600 mg. During PCI, anticoagulation regimens were chosen by the operator and included either unfractionated heparin targeted to achieve and maintain an activated clotting time of 250–300 seconds (200–250 seconds if glycoprotein IIb/IIIa inhibitors were used), enoxaparin 1 mg/kg or bivalirudin 0.75 mg/kg (bolus) followed by an infusion of 1.75 mg/kg per hour for the duration of the procedure. Adjunctive IIb/IIIa receptor inhibitors were used at the discretion of the operator. After the procedure, aspirin 100 mg was prescribed indefinitely and clopidogrel 75 mg was prescribed for a minimum of 6–12 months.

End-points and Definitions. The study end-points were frequency of postprocedure TIMI 3 flow, frequency of postprocedure normal myocardial blush, and proportion of patients with complete ST-segment resolution 60–90 minutes after PCI. Coronary angiograms were evaluated off-line by 2 experienced physicians not involved in the procedures, with differences resolved by consensus. TIMI thrombus score, TIMI flow, and myocardial blush grades were assessed as previously described.^{4,6,7} ST-segment resolution was assessed comparing a 12-lead ECG 60 minutes after PCI with the baseline 12-lead ECG. The sum of ST-segment elevation was measured 20 ms after the end of the QRS complex in leads I, aVL, and V1–V6 for anterior, and leads II, III, aVF, and V5–V6 for nonanterior myocardial infarction.⁸ Complete ST-segment resolution was defined as residual ST-segment elevation of $< 30\%$.^{5,9,10} Clinical follow-up was performed by telephone contact or office visit at 9 months. Major adverse cardiac events (MACE) were recorded, including all-cause death, myocardial infarction, target-vessel revascularization, and stent thrombosis. Stent thrombosis was defined according to the Academic

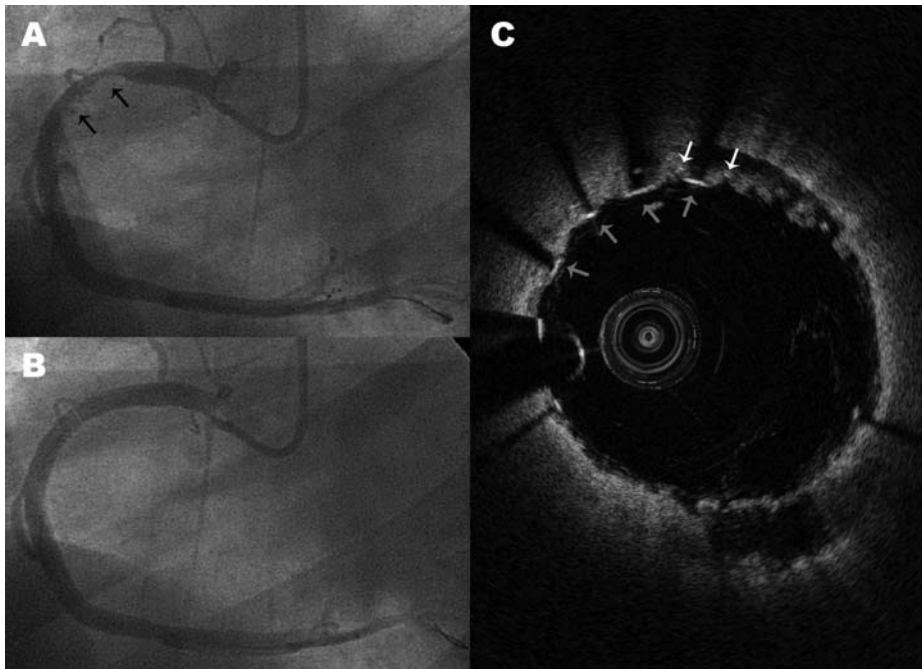


Figure 2. (A) Forty-five degree left oblique projection of a right coronary artery showing persistence of high thrombus burden after thrombus aspiration (black arrows). (B) Excellent angiographic result after MGuard stent implantation. (C) Optical coherence tomography after MGuard stent implantation (red line on panel B) showing absence of thrombus protrusion into the lumen. The thrombus appears to be trapped between the mesh (white arrows) and the vessel wall. Red arrows indicate the metallic struts.

Research Consortium definitions.¹¹ Source documentation of clinical events was obtained.

Statistical Analysis. Statistical analysis was performed using SPSS version 18. Continuous variables are shown as mean ± SD or median (interquartile range) if the distribution was not-normal. Categorical variables are expressed as frequencies and group percentages, and compared with the Chi-square test (or Fisher’s exact test if appropriate). The interobserver agreement on TIMI thrombus score, TIMI flow and myocardial blush measurements was assessed with the Kappa statistic.

Results

A total of 56 patients were included in this study. Baseline and procedural characteristics are detailed in Tables 1 and 2, respectively. In 3 instances (5.4%), the procedure was performed after failed thrombolysis. The right coronary artery was identified as the infarct-related artery in most cases. Only 6 (10.7%) cases had initial TIMI flow 2 to 3. Thrombus aspiration was performed at least twice in all patients. Histopathological examination showed atherothrombotic material in 45 cases (80.4%), of which 30 (67%) cases were thrombus containing platelets/erythrocytes and

Table 1. Baseline Characteristics

Variable	n = 56
Age (years)	60.0 ± 12.2
Male gender	45 (80.4%)
History of	
Diabetes mellitus	14 (25%)
Hypertension	25 (44.6%)
Hypercholesterolemia	34 (60.7%)
Prior myocardial infarction	6 (10.7%)
Prior CABG	1 (1.8%)
Prior PCI	3 (5.4%)
Current smoker	24 (42.9%)
Body mass index	28.0 ± 5.6
Peripheral vascular disease	8 (14.3%)
Chronic renal failure	3 (5.6%)
Chronic aspirin therapy	7 (12.5%)
Killip at presentation	
I	48 (85.7%)
II	4 (7.1%)
III	4 (7.1%)
Primary PCI	53 (94.6%)
Rescue PCI	3 (5.4%)

PCI, percutaneous coronary intervention; CABG, coronary artery bypass graft.

Table 2. Angiographic and Procedural Characteristics

Variable	n = 56
Radial access	39 (69.6%)
Number of diseased vessels	
1	30 (53.6%)
2	20 (35.7%)
3	6 (10.7%)
Target vessel	
Left anterior descending	7 (12.5%)
Circumflex	5 (8.9%)
Right coronary artery	44 (78.6%)
AHA/ACC lesion type	
Type B	34 (60.7%)
Type C	22 (39.3%)
Periprocedural anticoagulation	
Unfractionated heparin	40 (71.4%)
Enoxaparin	10 (17.9%)
Bivalirudin	6 (10.7%)
GP IIb/IIIa inhibitors	36 (64.3%)
IABP	2 (3.6%)
Ischemic times	
Total ischemic time (min)	210 (IQR 168–250)
Door to balloon or aspiration time (min)	30 (IQR 25–44)
Baseline TIMI flow	
TIMI 0–1	50 (89.3%)
TIMI 2	4 (7.1%)
TIMI 3	2 (3.6%)
Number of stents per patient	1.29 ± 0.56
Length of stented segment (mm)	27.6 ± 12.3
Diameter of stented segment (mm)	3.4 ± 0.4
Pre dilatation	14 (25%)
Post dilatation	1 (1.8%)

GP, glycoprotein; IABP, intraaortic balloon pump; IQR, interquartile range.

15 (33%) were thrombus with plaque. Mean atherothrombotic material length was 2.1 ± 0.5 mm. A total of 61 MGuard stents were implanted in the 56 patients. The study stent could be deployed over the culprit lesion in all cases but 1 (98.4%). In that case, a 3×38 mm MGuard stent could not be advanced to the distal RCA due to the tortuosity of the proximal segment. Additional nonstudy stents were implanted in 9 patients (8 bare-metal stents, 1 drug-eluting stent) in order to treat a distal edge stent dissection (1 patient, 1.8%) or additional severe lesions within the target vessel (8 patients). Occlusion of a side branch (1.5–2 mm) occurred in 2 cases (3.5%). Embolization to a distal branch was observed in 5 cases (8.9%) and transient no-reflow in 4 cases (7.1%). Thrombus score

after mechanical aspiration was grade 4 in most cases (Fig. 3). After MGuard stent deployment, >89% of cases had thrombus score = 0 ($p = 0.01$). Myocardial perfusion end-points are shown in Figure 4. TIMI flow and myocardial blush grade were evaluated in all cases. ST-segment resolution could be assessed in 46 cases. Most patients had final TIMI flow 2 to 3 (94.6%) and 76.8% had myocardial blush grade 2–3. Nearly half of the patients had TIMI 3 flow, blush grade 3, and complete ST-segment resolution. Subgroup analysis showed no relation between the right coronary artery being the culprit vessel and the final TIMI flow ($p = 0.2$) or final blush grade ($p > 0.5$). The Kappa statistic indicated excellent interobserver agreement for TIMI thrombus score ($\kappa = 0.862$, $p < 0.01$) and TIMI flow ($\kappa = 0.840$, $p < 0.01$). A Kappa statistic = 0.741 ($p < 0.01$) indicated substantial interobserver agreement for myocardial blush. Clinical follow-up at 9 months was assessed in all patients except 1 (this patient could not be reached because he permanently left the country). During the follow-up, no deaths occurred. There was 1 (1.8%) acute definite stent thrombosis 12 hours after a MGuard stent was placed in a distal RCA; intravascular ultrasound was then performed showing stent malapposition that was successfully treated with balloon dilatation. One patient (1.8%) developed asymptomatic occlusive restenosis that was left untreated. One patient experienced a target vessel nontarget lesion revascularization at 6 months (the study stent was patent without significant restenosis). MACE at 9 months was 3.6%.

Discussion

The main findings of this study suggest that MGuard stent implantation is a feasible and safe strategy in patients with STEMI and high thrombus burden despite manual aspiration. Two previous observational studies have sought to evaluate the usefulness of the MGuard stent in the treatment of consecutive patients with myocardial infarction.^{12,13} Both studies reported excellent results with low rates of distal embolization. However, the use of aspiration catheters in these studies was very low (<20%). In contrast to these reports, all our cases underwent manual aspiration, and direct stent implantation was performed in the majority of patients, which reflects the current standard of treatment in patients with STEMI. In addition to these observational studies, there are 2 ongoing randomized trials

MGUARD STENT IN MYOCARDIAL INFARCTION

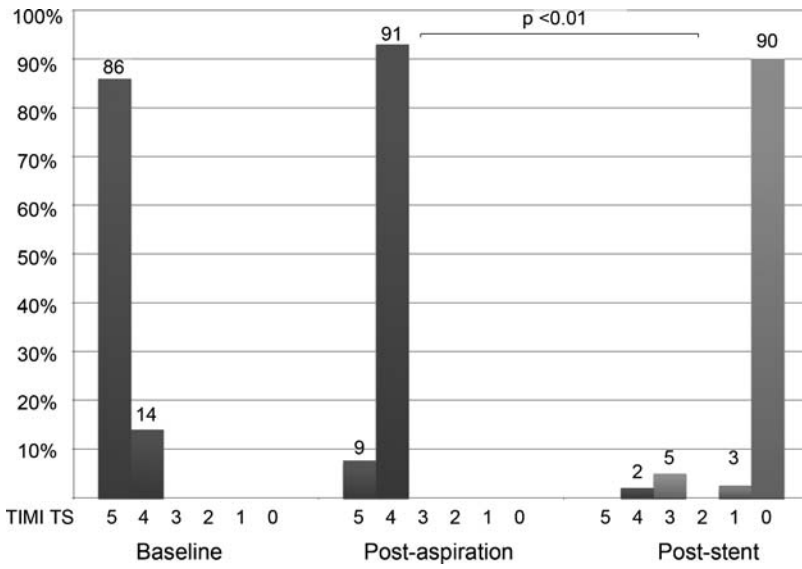


Figure 3. TIMI thrombus score (TS) at baseline was grade 5 in most cases. After mechanical aspiration, most patients had TIMI TS = 4. After MGuard stent implantation, almost 90% of cases had TIMI TS = 0 ($p = 0.01$).

evaluating the effectiveness and the safety of the MGuard stent in STEMI patients. In the prospective, randomized, multicenter evaluation of a polyethylene terephthalate micronet mesh-covered stent (MGuard) in the ST-segment elevation myocardial infarction (MASTER) trial, the use of the MGuard stent compared with conventional stents resulted in superior rates of epicardial coronary flow and complete ST-segment resolution, although clinical events at 30 days were

similar in both groups⁹. The MGuard versus bare metal stents plus manual thrombectomy in the ST-elevation myocardial infarction patients (GUARDIAN) trial, currently recruiting patients, will show if the MGuard stent without manual aspiration is noninferior to manual aspiration plus conventional stent with regard to the ST-segment resolution.¹⁴

Our study, however, is the first to evaluate the efficacy of the MGuard mesh-covered stent in cases in

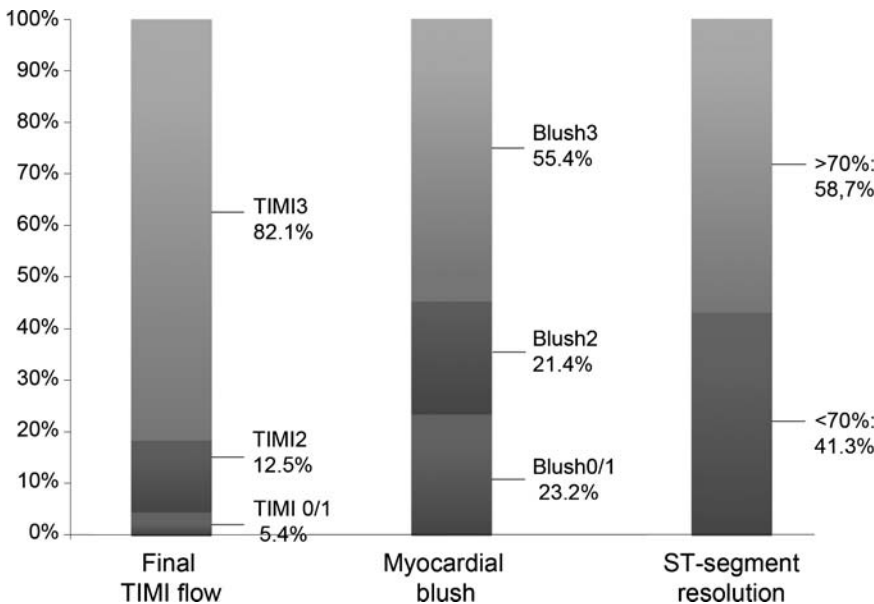


Figure 4. Myocardial reperfusion end-points.

which high thrombus burden persists after thrombus aspiration. Actually, our data are derived from a selected population with a high risk of thrombus embolization rather than consecutive patients with STEMI. Despite this unfavourable scenario, our frequencies of TIMI 3 flow, normal myocardial blush, and complete ST-segment resolution (as surrogates of myocardial reperfusion; Fig. 3) were comparables to those reported by the aspiration arm of the thrombus aspiration during primary percutaneous coronary intervention (TAPAS) trial.⁵

The risk of a major side branch occlusion due to MGuard stent implantation has been proposed previously,^{12,15,16} theoretically due to mechanical obstruction of the side branch by the struts and the mesh. Further, if a side branch is compromised, crossing through the stent platform and the mesh (in order to rescue the side branch) may be extremely complicated. In this study, although lesions with side branches >2 mm were excluded, 2 side branches of 1.5–2 mm were occluded after stent deployment. In our experience, side branch occlusion was due to thrombus shift to the side branch rather than mechanical obstruction by the stent. Therefore, we recommend avoid MGuard stent implantation in bifurcated lesions.

The strategy of covered stent implantation in order to create a mechanical barrier to prevent distal embolization has been tested previously.¹⁷ The Jostent Graftmaster™ (Abbott Vascular, Abbott Park, IL, USA) consists of a polytetrafluoroethylene membrane sandwiched between 2 coaxial steel bare metal stents. Actually, the membrane also prevented the endothelial ingrowth within the stent, which was eventually related to high rates of stent thrombosis as well as high rates of restenosis at the edges of the stent.^{17,18} In the case of the MGuard, however, it appears that the mesh does not prevent the neointimal proliferation within the stent.¹⁹ The rate of stent restenosis was low in our cohort. Importantly, routine angiographic follow-up was not performed and therefore we cannot rule out the occurrence of restenosis that does not provoke ischemia or symptoms in an infarcted myocardial territory. This possibility, coupled with the relatively short follow-up, may explain the low rate of ischemia-driven target-lesion revascularization in our population. Despite being one of the largest available series of combined use of mechanical aspiration and MGuard stent, the sample size was not sufficient to conduct adjusted analysis. Therefore this study carries inherent limitations of a small observational analysis. Further,

angiographic and electrocardiographic assessments were not performed by an independent Core Lab. Because the results were obtained from a single center, conclusions may not apply to centers with different practice patterns.

Conclusion

The MGuard stent may to be useful to prevent distal embolization in selected patients with STEMI and persistent high thrombus burden after mechanical aspiration. A randomized trial is warranted to establish the role of the MGuard stent in this scenario.

References

1. Silva-Orrego P, Bigi R, Colombo P, et al. Direct stenting after thrombus removal before primary angioplasty in acute myocardial infarction. *J Interv Cardiol* 2008;21:300–306.
2. Perez-Berbel P, Valencia J, et al. Rescue angioplasty: Characteristics and results in a single-center experience. *J Interv Cardiol* 2011;24:42–48.
3. Kaluski E, Tsai S, Klapholz M. Coronary stenting with MGuard: From conception to human trials. *Cardiovasc Revasc Med* 2008;9:88–94.
4. The TIMI IIIA Investigators. Early effects of tissue-type plasminogen activator added to conventional therapy on the culprit coronary lesion in patients presenting with ischemic cardiac pain at rest. Results of the thrombolysis in myocardial ischemia (TIMI IIIA) trial. *Circulation* 1993;87:38–52.
5. Svilaas T, Vlaar PJ, et al. Thrombus aspiration during primary percutaneous coronary intervention. *N Engl J Med* 2008;358:557–567.
6. The thrombolysis in myocardial infarction (TIMI) trial. Phase I findings. *N Engl J Med* 1985;312:932–936.
7. Van't Hof AW, Liem A, et al. Angiographic assessment of myocardial reperfusion in patients treated with primary angioplasty for acute myocardial infarction: Myocardial blush grade. Zwolle Myocardial Infarction Study Group. *Circulation* 1998;97:2302–2306.
8. Van't Hof AW, Liem A, de Boer MJ, et al. Clinical value of 12-lead electrocardiogram after successful reperfusion therapy for acute myocardial infarction. Zwolle Myocardial infarction Study Group. *Lancet* 1997;350:615–619.
9. Stone GW, Abizaid A, et al. Prospective, randomized, multicenter evaluation of a polyethylene terephthalate micronet mesh-covered stent (MGuard) in ST-segment elevation myocardial infarction: The MASTER trial. *J Am Coll Cardiol* 2012;60:1975–1984.
10. Ahmed TA, Atary JZ, et al. Aspiration thrombectomy during primary percutaneous coronary intervention as adjunctive therapy to early (in-ambulance) abciximab administration in patients with acute ST elevation myocardial infarction: An analysis from Leiden MISSION! acute myocardial infarction treatment optimization program. *J Interv Cardiol* 2012;25:1–9.
11. Cutlip DE, Windecker S, et al. Clinical end points in coronary stent trials: A case for standardized definitions. *Circulation* 2007;115:2344–2351.
12. Piscione F, Danzi GB, et al. Multicentre experience with MGuard net protective stent in ST-elevation myocardial infarction:

MGUARD STENT IN MYOCARDIAL INFARCTION

- Safety, feasibility, and impact on myocardial reperfusion. *Catheter Cardiovasc Interv* 2010;75:715–721.
13. Dudek D, Dziewierz A, et al. Mesh covered stent in ST-segment elevation myocardial infarction. *EuroIntervention* 2010;6:582–589.
 14. Cassese S, Esposito G, et al. MGUard versus bare-metal stents plus manual thrombectomy in ST-elevation myocardial infarction patients-(GUARDIAN) trial: Study design and rationale. *Catheter Cardiovasc Interv* 2012;79:1118–1126.
 15. Kaluski E, Hauptmann KE, et al. Coronary stenting with MGUard: First-in-man trial. *J Invasive Cardiol* 2008;20:511–515.
 16. Romaguera R, Gomez-Hospital JA, Cequier A. Novel use of the MGUard mesh-covered stent to treat coronary arterial perforations. *Catheter Cardiovasc Interv* 2012;80:75–78.
 17. Elsner M, Auch-Schwelk W, et al. Coronary stent grafts covered by a polytetrafluoroethylene membrane. *Am J Cardiol* 1999;84:335–338; A8.
 18. Romaguera R, Waksman R. Covered stents for coronary perforations: Is there enough evidence? *Catheter Cardiovasc Interv* 2011;78:246–253.
 19. Costa JR, Jr., Abizaid A, et al. One-year results of the INSPIRE trial with the novel MGUard stent: Serial analysis with QCA and IVUS. *Catheter Cardiovasc Interv* 2011;78:1095–1100.