



## ORIGINAL ARTICLE

# Elements of morphology: Standard terminology for the teeth and classifying genetic dental disorders

Muriel de La Dure-Molla<sup>1,2,3</sup> | Benjamin Philippe Fournier<sup>1,3,4</sup> |  
 Maria Cristina Manzanares<sup>5</sup> | Ana Carolina Acevedo<sup>6,7</sup> | Raoul C. Hennekam<sup>8</sup> |  
 Lisa Friedlander<sup>3,9</sup> | Marie-Laure Boy-Lefèvre<sup>1,3</sup> | Stephane Kerner<sup>1,3</sup> |  
 Steve Toupenay<sup>1,3</sup> | Pascal Garrec<sup>1,3</sup> | Brigitte Vi-Fane<sup>1,3</sup> | Rufino Felizardo<sup>1,3</sup> |  
 Marie-Violaine Berteretche<sup>1,3</sup> | Laurence Jordan<sup>1,3</sup> | François Ferré<sup>4</sup> |  
 François Clauss<sup>3,10,11</sup> | Sophie Jung<sup>3,10,11</sup> | Myriam de Chalendar<sup>3</sup> |  
 Sebastien Troester<sup>3,10,11</sup> | Marzena Kawczynski<sup>3,10,11</sup> | Jessica Chaloyard<sup>3</sup> |  
 International Group of Dental Nomenclature | Marie Cécile Manière<sup>3,10,11</sup> |  
 Ariane Berdal<sup>1,3,4</sup> | Agnès Bloch-Zupan<sup>3,10,11,12,13</sup>

<sup>1</sup>Centre de Référence des Maladies rares Orales et Dentaires, Hôpital Rothschild, AP-HP, Faculté Odontologie Garancière, Université de Paris, France

<sup>2</sup>INSERM UMR\_S1163 Bases moléculaires et physiopathologiques des ostéochondrodysplasies, Institut Imagine, Necker, Paris, France

<sup>3</sup>Filière de santé Maladies Rares TETECO: Malformations rares de la tête, du cou et des dents, Hôpital Necker-Enfants Malades, Paris, France

<sup>4</sup>Laboratoire de Physiopathologie Orale Moléculaire INSERM UMR S1138, Centre de Recherche des Cordeliers, Universités Paris-Diderot et Paris-Descartes, Paris, France

<sup>5</sup>Unitat d'Anatomia i Embriologia Humana, Departament de Patologia i Terapèutica Experimental, Facultat de Medicina i Ciències de la Salut, Universitat de Barcelona, Barcelona, Spain

<sup>6</sup>ral Care Center for Inherited Diseases, University Hospital of Brasilia, University of Brasilia, Brasilia, Brazil

<sup>7</sup>Department of Dentistry, Health Sciences School, University of Brasilia, Brasilia, Brazil

<sup>8</sup>Department of Pediatrics, Amsterdam UMC location AMC, University of Amsterdam, Amsterdam, The Netherlands

<sup>9</sup>INSERM UMR\_S1123, ECEVE, Epidémiologie clinique, évaluation économique des populations vulnérables, Paris, France

<sup>10</sup>Faculté de Chirurgie Dentaire, Université de Strasbourg, Strasbourg, France

<sup>11</sup>Pôle de Médecine et Chirurgie Bucco-Dentaires, Centre de Référence des Maladies Rares Orales et Dentaires, CRM O-Rares, ERN CRANIO, Hôpitaux Universitaires de Strasbourg, Strasbourg, France

<sup>12</sup>Institut de Génétique et de Biologie Moléculaire and Cellulaire, Centre Européen de Recherche en Biologie et en Médecine, Université de Strasbourg, CNRS UMR7104, INSERM U1258, Illkirch, France

<sup>13</sup>Institut d'Etudes Avancées, Université de Strasbourg, USIAS, Strasbourg, France

**Correspondence**

Muriel de La Dure-Molla, Centre de Référence des Maladies Rares Orales et Dentaires, Service Odontologie Hôpital Rothschild, AP-HP, 5 rue Santerre, 75012, Paris, France  
 Email: [muriel.deladure-molla@aphp.fr](mailto:muriel.deladure-molla@aphp.fr)

**Funding information**

European Regional Development Fund (ERDF) of the European Union; Contrat Interface INSERM/AP-HP, Grant/Award Number: ANR-10-LABX-0030-INRT

**Abstract**

Dental anomalies occur frequently in a number of genetic disorders and act as major signs in diagnosing these disorders. We present definitions of the most common dental signs and propose a classification usable as a diagnostic tool by dentists, clinical geneticists, and other health care providers. The definitions are part of the series Elements of Morphology and have been established after careful discussions within an international group of experienced dentists and geneticists. The classification system was elaborated in the French collaborative network "TÉTECOU" and the affiliated

This is an open access article under the terms of the Creative Commons Attribution NonCommercial License, which permits use, distribution and reproduction in any medium, provided the original work is properly cited and is not used for commercial purposes.

© 2020 The Authors. *American Journal of Medical Genetics Part A* published by Wiley Periodicals, Inc.

O-Rares reference/competence centers. The classification includes isolated and syndromic disorders with oral and dental anomalies, to which causative genes and main extraoral signs and symptoms are added. A systematic literature analysis yielded 408 entities of which a causal gene has been identified in 79%. We classified dental disorders in eight groups: dental agenesis, supernumerary teeth, dental size and/or shape, enamel, dentin, dental eruption, periodontal and gingival, and tumor-like anomalies. We aim the classification to act as a shared reference for clinical and epidemiological studies. We welcome critical evaluations of the definitions and classification and will regularly update the classification for newly recognized conditions.

#### KEYWORDS

Anatomy and Histology, Classification, Craniofacial abnormalities, Rare diseases, Terminology, Tooth abnormalities

## 1 | INTRODUCTION

Tooth number, shape, size, structure, and/or position can be abnormal or altered. There may be delayed or absent tooth eruption. Alterations in periodontal, gingival tissue formation, and odontogenic tumors are also recorded. Teeth anomalies can occur isolated or form an integral part of syndromes. Incomplete penetrance and variability in expression may result in difficulties in diagnosing syndromes. The progress in our knowledge of causative genes and sequencing techniques has enabled diagnostic procedures using panels of genes all known to cause dental anomalies and recognize syndromic entities, which were initially identified as isolated (Prasad et al., 2016). Tooth development anomalies can be part of a large number of disorders, with variable genetic causes, in a variety of ways (Bloch-Zupan, Sedano, & Scully, 2012; Hall, 1994). Dental development is driven by a cascade of epithelial-mesenchymal interactions between oral ectoderm and cranial neural crest derived ectomesenchyme (Tucker & Sharpe, 2004). This process takes place from embryonic and fetal prenatal stages until adulthood, ending with the eruption and the completion of root development of the last third molar. Dental anomalies are morphologically diverse and appear at any time during dental development (Thesleff, 2014). Dental anomalies reflect specific disturbances of one or more stages of odontogenesis, roughly classified as tooth initiation, morphogenesis, cytodifferentiation, mineralization, and bone modeling occurring with eruption (Hennekam, Allanson, & Krantz, 2010).

No complete nosology of dental disorders is available, and only partial nosologies have been published describing specific pathologies such as amelogenesis imperfecta (Witkop Jr., 1988) or dentinogenesis imperfecta (de La Dure-Molla, Fournier, & Berdal, 2015). Here, we present our experience in the management of several thousand patients with dental manifestations as part of their rare disorders and offer an overview of established entities and their classification into isolated and syndromic dental disorders. The classification is only possible if defined terms are available to describe oral and dental findings. A standard terminology for lips, mouth, and oral region is available

(Carey et al., 2009). Here, we provide a definition for each dental sign using the strategy of the Elements of Morphology series (Allanson, Biesecker, Carey, & Hennekam, 2009). In the classification, the primary diagnostic entry is the dental sign(s), followed by the main other medical manifestations. We added the causative gene(s) and protein and cross-reference with the international nomenclatures OMIM and Orphanet (Rath et al., 2012). We aim to facilitate offering a globally usable nomenclature of dental signs and symptoms and facilitate interactions between oral health specialists and other health care providers.

## 2 | MATERIALS AND METHODS

Rare Disease Reference Centers and affiliated Competence Centers of the French Rare Disorders Healthcare Network named “TÊTECOU” constitutes a multidisciplinary group of experts, working on diagnosis and management of individuals with rare disorders of the head and neck, including dental defects. The group of experts constituted a working group to defining dental anomalies and proposed a nosology of genetic dental disorders. The results have been endorsed by an international panel of experts taking into account all observations.

### 2.1 | Defining dental anomalies

Existing terminology of dental anomalies was analyzed by obtaining data from several databases, nomenclatures, and ontologies (Supplementary Data Table S1): HPO (Human Phenotype Ontology (Groza et al., 2015), Orphanet (Rath et al., 2012), NEN9313:2015, D[4]phenodent (Bloch-Zupan, 2004), ICD10-ICD11, and the standard terminology of Elements of Morphology for the lips, mouth, and oral region (Carey et al., 2009). When worded differently, the present definitions supersede the ones from Carey et al., 2009. Data collected were formatted according to Elements of Morphology series (Allanson et al., 2009).

**TABLE 1** Nosology of rare dental disorders listing 408 different conditions (Issa et al., 2016), (Kantaputra et al., 2015), (Peled et al., 2016), (Laugel-Haushalter et al., 2018), (Tan et al., 2009), (Kim et al., 2013), (Smith et al., 2016), (Seymen et al., 2016), (Kim et al., 2018), (Parry et al., 2016), (Yang et al., 2016), (Xiong et al., 2017) (Bloch-Zupan et al., 2012; Hall, 1994), (Ferre et al., 2012), (Papapanou et al., 2018)

Group of dental anomaly/ name of disease	Phenotype MIM number	Orphanet number (ORPHA)	Inheritance	Gene/locus	Protein	Notes	Main manifestations
<b>Dental agenesis (hypodontia/oligodontia/anodontia)</b>							
<b>(1) Isolated</b>							
1 Incisors, lower central, absence of	147330	/	/	/	/	Three old report, underdiagnosis case	
2 Teeth, congenital absence of with taurodontia ans sparse hair	272980	2731	/	/	/		
3 Tooth agenesis, selective, X-linked 1; STHAGX1	313500	99798	XLD	EDA	Ectodysplasin A		
4 Tooth agenesis, selective, 1, with or without orofacial cleft; STHAG1	106600		AD	MSX1	Homeobox protein MSX-1		
5 Tooth agenesis, selective, 2; STHAG2	602639	/	AR	16q12.1			
6 Tooth agenesis, selective, 3; STHAG3	604625	99978	AD	PAX9	Paired box protein Pax-9		
7 Tooth agenesis, selective, 4; STHAG4	150400		AD	WNT10A	Protein WNT-10A		
8 Tooth agenesis, selective, 5; STHAG5	610926	99798	/	10q11.2-q21	/		
9 Tooth agenesis, selective, 7; STHAG7	616724	99798	AD	LRP6	Low-density lipoprotein receptor-related protein 6		
10 Oligodontia-colorectal cancer syndrome	608615	300576	AD	AXIN2	Axin-2		
11 Ectodermal dysplasia 10A, hypohidrotic/hair/hail type, autosomal dominant	129490	238468181	AD	EDAR	Ectodysplasin A receptor		
12 Ectodermal dysplasia 11A, hypohidrotic/hair/tooth type, autosomal dominant	614940		AD/AR	EDARADD	EDAR-associated death domain		
13 Ectodermal dysplasia 11B, hypohidrotic/hair/tooth type, autosomal recessive	614941	238468, 248	AD/AR	EDARADD	EDAR-associated death domain		
14 Ectodermal dysplasia wit natal teeth, Turnpenny type	601345	69083	/	/	/	One family	

(Continues)

TABLE 1 (Continued)

Group of dental anomaly/ name of disease	Phenotype MIM number	Orphanet number (ORPHA)	Inheritance	Gene/locus	Protein	Notes	Main manifestations
<b>(2) Skin disorders</b>							
<b>(2.1) Ectodermal dysplasia "classical"</b>							
15 Bök syndrome	112300	1262	/	/	/		Severe hyperhidrosis of the hands and feet, small hands, small nails
16 Dermoodontodysplasia	125640	1660	/	/	/	Two families, probable underdiagnosis	Abnormal development in two or more ectodermal structures (hair, nails, teeth, and sweat glands) without other systemic findings
17 Ectodermal dysplasia 1, hypohidrotic, X-linked	305100	238468, 181	XLR	EDA	Ectodysplasin A		
18 Ectodermal dysplasia 2, Clouston type	129500	189	AD	GJB6	Gap junction protein beta 6		
19 Ectodermal dysplasia 3, Witkop type	189500	2228	AD	MSX1	Homeobox protein MSX-1		
20 Ectodermal dysplasia 8, hair/tooth/nail type	602401	99672	AR	18q22.1-q22.3			
21 Ectodermal dysplasia 10B, hypohidrotic/hair/tooth type, autosomal recessive	224900	238468, 248	AR	EDAR	Ectodysplasin A receptor		
22 Ectodermal dysplasia 11A, hypohidrotic/hair/tooth type, autosomal dominant	614940	238468, 1810	AD/AR	EDARADD	EDAR-associated death domain		
23 Ectodermal dysplasia 11B, hypohidrotic/hair/tooth type, autosomal recessive	614941	238468, 248	AD/AR	EDARADD	EDAR-associated death domain		
24 Ectodermal dysplasia/short stature syndrome	616029	423454	AR	GRHL2	Grainyhead-like protein 2 homolog		
25 Ectodermal dysplasia	/	/	AR	KREMEN1	KREMEN1	Issa et al., 2016	
26 Ectodermal dysplasia	/	/	/	GREM2	GREMLIN-2	Kantaputra et al., 2015	
27 Ectodermal dysplasia	/	/	/	TSPEAR	TSPEAR	Peled et al., 2016	
28 Odontoonychodermal dysplasia	257980	2721	AD	WNT10A	Protein WNT-10A		
29 Schopf-Schulz-Passarge syndrome	224750	50944	AR	WNT10A	Protein WNT-10A		
30 Trichodontal dysplasia	601453	3351	AD	/	/	Four families, probable underdiagnosis	Space scalp and slow growing hair

(Continues)



**TABLE 1** (Continued)

Group of dental anomaly/ name of disease	Phenotype MIM number	Orphanet number (ORPHA)	Inheritance	Gene/locus	Protein	Notes	Main manifestations
31 Wolf-Hirschhorn syndrome	194190	280	AD	MSX1, del4p15.1-15.2	Homeobox protein MSX-1		Growth and developmental delay, facial dysmorphism (Greek warrior helmet profil), intellectual disability
<b>(2.2) Skin disorders with cleft/craniofacial disorders</b>							
32 Cleft lip/palate-ectodermal dysplasia syndrome, CLPED1	225060	1991, 3253	AR	NECTIN1(PVRL1)	Nectin cell adhesion molecule 1		Cleft lip and palate, sparse scalp hair, malformed protruding ears, partial syndactyly of the fingers and toes, hypohidrotic ectodermal dysplasia
33 Cranioectodermal dysplasia 1	218330	1515	AR	IFT122	Intraflagellar transport protein 122 homolog	Other name: Sensenbrenner syndrome	Sagittal craniosynostosis, short stature, sparse scalp hair, small nails, short hand, short limbs, small ans narrow thorax, joint laxity, chronic renal, and liver disease
34 Cranioectodermal dysplasia 2	613610	1515	AR	WDR35	WD repeat-containing protein 35		
35 Cranioectodermal dysplasia 3	614099	1515	AR	IFT43	Intraflagellar transport protein 43		
36 Cranioectodermal dysplasia 4	614378	1515	AR	WDR19	WD repeat-containing protein 19		
37 EEC syndrome-1	129900	1896	AD	7q11.2-q21.3	/		Anhidrotic ectodermal dysplasia, cleft lip, and palate
38 Orofacial cleft 8	129400	1991	AD	TP63	Tumor protein 63		Anhidrotic ectodermal dysplasia, cleft lip, and palate
39 Rapp-Hodgkin syndrome	129400	3022	AD	TP63	Tumor protein 63		Anhidrotic ectodermal dysplasia, cleft lip, and palate
<b>(2.3) Skin disorders with fingers disorders</b>							
40 ADULT syndrome	103285	978	AD	TP63	Tumor protein 63		Split of hands and feet, syndactyly of finger, small nail, breasts and nipples hypoplasia, intensive freckling, lacrimal duct atresia, frontal alopecia
41 Ectodermal dysplasia, ectrodactyly, and macular dystrophy	225280	1897	AR	CDH3	Cadherin 3		Ectodermal dysplasia, split of hand and foot, syndactyly, macular dystrophy
42 Ectrodactyly, ectodermal dysplasia, and cleft lip/palate syndrome 3	604292	1896	AD	TP63	Tumor protein 63		Split of hands and feet, ectodermal dysplasia, cleft lip/palate

(Continues)

TABLE 1 (Continued)

Group of dental anomaly/ name of disease	Phenotype MIM number	Orphanet number (ORPHA)	Inheritance	Gene/locus	Protein	Notes	Main manifestations
43 Ectodermal dysplasia-syndactyly syndrome 1	613573	247820	AR	NECTIN4(PVRL4)	Nectin cell adhesion molecule 4		Ectodermal dysplasia, syndactyly
44 Hay-Wells syndrome	106260	1071	AD	TP63	Tumor protein 63		Syndactyly, scalp infections, ankyloblepharon, cleft lip/palate
45 Limb-mammary syndrome	603543	69085	AD	TP63	Tumor protein 63		Severe hand/foot anomalies and hypoplasia/aplasia of the mammary gland and nipple
46 Odontotrichoungual-digital-palmar syndrome	601957	69082	AD	/	/	One family	Space scalp hair, syndactyly, deep transverse palmar creases, small nails
47 Uncombable hair, retinal pigmentary dystrophy, dental anomalies, and brachydactyly	191482	1264	AD	/	/	One family	Sparse scalp hair, juvenile cataracts, retinal pigmentary dystrophy, short metacarpal
<b>(2.4) Skin disorders with neurologic disorder</b>							
48 Incontinentia pigmenti	308300	464	XLD	IKBK/NEMO	NF-kappa-B essential modulator		Abnormalities of the skin along Blaschko's lines, space scalp hair, small nails, central nervous system anomalies
49 Ectodermal dysplasia, hypohidrotic, with immune deficiency	300291	98813	XLD, AD	IKBK/NEMO, NFKBIA	NF-kappa-B essential modulator		Hypohidrotic ectodermal dysplasia, immunodeficiency
<b>(2.5) Skin disorders with cardiopathology</b>							
50 Cardiomyopathy, dilated, with woolly hair and keratoderma	605676	65282	AR	DSP	Desmoplakin		Cardiomyopathy with woolly hair, keratoderma
51 Dilated cardiomyopathy with woolly hair, keratoderma, and tooth agenesis	615821		AD	DSP	Desmoplakin		
<b>(2.6) Skin disorders with skin blistering</b>							
52 Ectodermal dysplasia/skin fragility syndrome	604536	158668	AR	PKP1	Plakophilin 1		Skin fragility as blistering, ectodermal dysplasia, dystrophic nails, space scalp hair, palmo-plantar keratoderma
<b>(2.7) Others skin disorders syndrome</b>							
53 Acral-renal-ectodermal-dysplasia-lipoatrophic-diabetes (AREDYLD)	207780	1133	AR	/	/	Two families	Lipoatrophy, diabetes mellitus, facial dysmorphism, space scalp hair, renal disorder
54 Cerebellar ataxia and ectodermal dysplasia	212835	1174	/	/	/		Cerebellar ataxia and hypohidrotic ectodermal dysplasia

(Continues)

TABLE 1 (Continued)

Group of dental anomaly/ name of disease	Phenotype MIM number	Orphanet number (ORPHA)	Inheritance	Gene/locus	Protein	Notes	Main manifestations
55 Deafness, congenital, and onychohypostrophy, autosomal dominant, DDOD	124480	79499, 3231	AD	ATP6V1B2	Vacuolar V-ATPase protein		Congenital deafness, small nails, small terminal phalanges
56 Ectodermal dysplasia, trichodontonychia type	129510	1818	/	/	/		Ectodermal dysplasia, focal linear dermal hypoplasia of the tip of the nose, bilateral amastia and athelia, mild nerve hearing loss
57 Dermatoosteolysis, Kirghizian type	221810	1657	AR	/	/	One family	Recurrent skin ulceration, arthralgia, fever, fistulous osteolysis around joints, nail dystrophy, and keratitis with visual impairment or blindness
58 Piloantral dysplasia with refractive errors	262020	2892	/	/	/	One family	Ectodermal dysplasia with normal sweating and fingernails, scalp hypotrichosis, pili annulati, follicular hyperkeratosis of trunk and limbs, marked hyperopia
59 Progeroid short stature with pigmented nevi	176690	2959	AR	/	/		Premature aging, multiple pigmented nevi, lack of facial subcutaneous fat, microcephaly, short stature, sensorineural hearing loss, and intellectual disability
60 Scalp-ear-nipple syndrome	181270	2036	AD	KCTD1	BTB/POZ domain- containing protein KCTD1		Aplasia cutis congenita of the scalp, breast, and ears anomalies (absent pinnae, bilateral amastia), cataract
61 Short stature, onychohypostrophy, facial dysmorphism, and hypotrichosis	614813	314394	AR	POC1A	POC1 centriolar protein homolog A		Short stature, small nails, facial dysmorphism, sparse scalp hair, short hands, and feet
62 Waardenburg syndrome, type 1	193500	894, 3440	AD	PAX3	Paired-box protein Pax-3		Pigmentary abnormalities of the hair, skin, and eyes, congenital sensorineural hearing loss, wide nasal ridge
<b>(3) Eye diseases</b>							
63 Axenfeld-Rieger syndrome, type 1	180500	782	AD	PITX2	Pituitary homeobox 2		Abnormal development of the anterior segment of the eye, failure of involution of periumbilical skin

(Continues)

TABLE 1 (Continued)

Group of dental anomaly/ name of disease	Phenotype MIM number	Orphanet number (ORPHA)	Inheritance	Gene/locus	Protein	Notes	Main manifestations
64 Axenfeld-Rieger syndrome, type 2	601499		AD	13q14			
65 Axenfeld-Rieger syndrome, type 3, Rieger or Axenfeld anomalies	602482	98978, 91483, 782	AD	FOXC1	Forkhead box protein C1		
66 Blepharocheloidontic syndrome, BCDS	119580	1997	AD	/	/		Lower eyelid ectropion, upper eyelid distichiasis, euryblepharon, bilateral cleft lip, and palate
67 Chromosome 6pter-p24 deletion syndrome	612582	96125	IC	/	/	Deletion FOXC1	Developmental delay, hypotonia, brachycephaly, dolichocephaly, or frontal bossing
68 Telecanthus	187350	/	/	/	/	One family	Telecanthus
<b>(4) Bone diseases</b>							
69 Andersen syndrome	170390	37553	AD	KCNJ2	Inward rectifier potassium channel 2		Periodic paralysis, ventricular arrhythmias, and distinctive dysmorphic facial or skeletal features, hypoplastic kidney, valvular heart disease
70 Bloom syndrome	210900	125	AR	BLM	Bloom syndrome RecQ- like helicase		Growth deficiency, sun-sensitive, telangiectatic, hypo- and hyperpigmented skin, predisposition to malignancy
71 Coffin-Lowry syndrome	303600	192	XLD, IC	RPS6KA3	Ribosomal protein S6 kinase alpha-3		Intellectual disability, skeletal malformations, growth retardation, short stature, broad tapping fingers, hearing deficit, paroxysmal movement disorders, facial dysmorphism
72 Congenital myopathy with excess of muscle spindles (Costello syndrome)	218040	3071	IC, AD	HRAS	GTPase HRas		Coarse facies, short stature, distinctive hand posture and appearance, severe feeding difficulty, failure to thrive
73 Dental anomalies and short stature	601216	2899	AR	LTBP3	Latent transforming growth factor beta binding protein 3	Enamel anomaly	Short stature, platyspondyly, brachyolmia
74 Diastrophic dysplasia	222600	628	AR	SLC26A2	Sulfate transporter		Scoliosis, calcification of the cartilage, premature calcification of the costal cartilages

(Continues)

TABLE 1 (Continued)

Group of dental anomaly/ name of disease	Phenotype MIM number	Orphanet number (ORPHA)	Inheritance	Gene/locus	Protein	Notes	Main manifestations
75 Dysosteosclerosis	224300	1782	AR	SLC29A3	Equilibrative nucleoside transporter 3		Osteopetrosis, red-violet macular atrophy of skin, platyspondyly
76 Ellis-van Creveld syndrome	225500	289	AR	EVC1, EVC2	EVC ciliary complex subunit 1		Chondrodysplasia (short limbs, short ribs, postaxial polydactyly), ectodermal dysplasia
77 Johanson-Blizzard syndrome	243800	2315	AR	UBR1	E3 ubiquitin-protein ligase UBR1		Growth deficiency, intellectual disability, facial dysmorphism, pancreatic insufficiency
78 Kabuki syndrome	147920	2322	AD	KMT2D	Histone-lysine N-methyltransferase 2D		Intellectual disability, postnatal dwarfism, facial dysmorphism, short fifth fingers, radiographic abnormalities of the vertebrae, hip joints, recurrent otitis
79 Kabuki syndrome 2	300867	/	XLD	KDM6A	Lysine-specific methyltransferase 6A		
80 Rothmund-Thomson syndrome	268400	2909	AR	RECQL4	ATP-dependent DNA helicase Q4		Skin atrophy, telangiectasia, hypopigmentation, congenital skeletal abnormalities, short stature, premature aging, increased risk of malignant disease, sparse scalp hair, juvenile cataract
81 Sotos syndrome 1, SOTOS1	117550	821	AD	NSD1, del19p13.2	Histone-lysine N-methyltransferase, H3 lysine-36 and H4 lysine-20 specific		Excessively rapid growth, acromegalic features, nonprogressive cerebral disorder with intellectual disability, facial dysmorphism
82 Weyers acrocentric dysostosis	193530	952	AD	EVC1, EVC2	EVC ciliary complex subunit 1		Nail dystrophy, postaxial polydactyly, mild short stature
<b>(5) Endocrine and gynecological diseases</b>							
83 Brachymetapody, anodontia, hypotrichosis, albinoidism	211370	2713	/	/	/		Short stature with particular shortening of the metacarpals and metatarsals, sparse scalp hair, albinoidism, multiple ocular abnormalities
84 Hypogonadotropic hypogonadism 1 with or without anosmia (Kallmann syndrome 1)	308700	432, 478	XL	ANOS1 (KAL1)	Anosmin 1		Absent or incomplete sexual maturation, low levels of circulating gonadotropins and testosterone, abnormalities of the hypothalamic-pituitary axis

(Continues)

TABLE 1 (Continued)

Group of dental anomaly/ name of disease	Phenotype MIM number	Orphanet number (ORPHA)	Inheritance	Gene/locus	Protein	Notes	Main manifestations
85 Hypogonadotropic hypogonadism 2 with or without anosmia	147950	432, 478	AD	FGFR1	Fibroblast growth factor receptor 1		
86 Hypogonadotropic hypogonadism 3 with or without anosmia	244200		AD	PROKR2	Prokineticin receptor 2		
87 Hypogonadotropic hypogonadism 4 with or without anosmia	610628		AD	PROK2	Prokineticin 2		
88 Opitz GBBB syndrome, type II	145410	2745, 306588	AD	SPECC1L	Cytospin-A		Laryngotracheoesophageal cleft, cleft of lip and palate, genitourinary defects, intellectual disability, developmental delay
89 Ulnar-mammary syndrome	181450	3138	AD	TBX3	T-box transcription factor TBX3		Posterior limb deficiencies or duplications, apocrine/mammary gland hypoplasia and/or dysfunction, delayed puberty in males, genital anomalies
<b>(6) Cranio-facial anomalies</b>							
90 Acrofacial dysostosis, Palagonia type	601829	1787	XL	/	/	One family	Acrofacial dysostosis, short stature, facial dysmorphism
91 Alagille syndrome	118450	52, 261600, 261619	AD	JAG1	JAGGED-1		Paucity of intrahepatic bile ducts, cholestasis, cardiac disease, skeletal abnormalities, ocular abnormalities, facial dysmorphism
92 Apert syndrome	101200	87	AD	FGFR2	Fibroblast growth factor receptor 2		Craniosynostosis, midface hypoplasia, syndactyly of the hands and feet with a tendency to fusion of bony structures
93 Branchiooculofacial syndrome	113620	1297	AD	TFAP2A	Transcription factor AP-2-alpha		Branchial cleft sinus defects, ocular anomalies (microphthalmia, lacrimal duct obstruction), facial dysmorphism, conductive hearing loss
94 Carpenter syndrome	201000	65759	AR	RAB23	Ras-related protein Rab-23		Acrocephaly, variable synostosis, short fingers, syndactyly, congenital heart defects, growth retardation, intellectual disability, hypogenitalism, obesity

(Continues)

TABLE 1 (Continued)

Group of dental anomaly/ name of disease	Phenotype MIM number	Orphanet number (ORPHA)	Inheritance	Gene/locus	Protein	Notes	Main manifestations
95 Carpenter syndrome 2	614976		AR	MEGF8	Multiple epidermal growth factor-like domains protein 8		Multisuture craniosynostosis, polysyndactyly of the hands and feet, abnormal left-right patterning, obesity, umbilical hernia, cryptorchidism, congenital heart disease
96 Char syndrome	169100	46627	AD	TFAP2B	Transcription factor AP2 beta		Patent ductus arteriosus with facial dysmorphism, short fifth fingers
97 Cleft palate with ankyloglossia	303400	324601	XL	TBX22	T-box transcription factor TBX22		Cleft palate with or without ankyloglossia
98 Cleft palate deafness and oligodontia	216300	2010	/	/	/	One family	Cleft soft palate, bilateral conductive deafness, short halluces
99 Holoprosencephaly 1	236100	2162	IC,AD	21q22.3	/		Malformation of the human forebrain
100 Holoprosencephaly 2	157170		IC,AD	SIX3	Homeobox protein SIX3		Lip and anterior cleft palate, hypotelorism, microcephaly, intellectual disability, scoliosis, chronic constipation
101 Holoprosencephaly 3	142945		AD	SHH	Sonic hedgehog protein		
102 Holoprosencephaly 4	142946		AD	TGIF1	Transforming growth factor beta induced factor 1		
103 Holoprosencephaly 5	609637		AD	ZIC2	Zinc finger protein ZIC 2		Alobar and semi-lobar holoprosencephaly
104 Holoprosencephaly 7	610828	AD	PTCH1	Protein patched homolog 1		Semi-lobar	holoprosencephaly
105 Holoprosencephaly 9	610829	AD	GLI2	Zinc finger protein GLI2		Brain developmental defects, with or without overt forebrain cleavage abnormalities	
106 Orofaciodigital syndrome I	311200	2750	XLD	OFD1	Oral-facial-digital syndrome 1 protein		Facial dysmorphism, fingers anomalies, alopecia

(Continues)

TABLE 1 (Continued)

	Group of dental anomaly/ name of disease	Phenotype MIM number	Orphanet number (ORPHA)	Inheritance	Gene/locus	Protein	Notes	Main manifestations
107	Sener syndrome	606156	/	/	/	/		Facial dysmorphism, thin hair, and dystrophic nails, mild developmental delayed
108	Single median maxillary central incisor	147250	2162, 280200, 2286	AD	SHH	Sonic Hedgehog protein		Severe to mild intellectual disability, congenital heart disease, cleft lip, and/or palate, facial dysmorphism, and less frequently hypopituitarism, hypotelorism, convergent strabismus, oesophageal and duodenal atresia, cervical hemivertebrae, cervical dermoid, hypothyroidism, scoliosis, absent kidney, micropenis, and ambiguous genitalia
109	Teebi-Shaltout syndrome	272950	3291	/	/	/		Slow hair growth, scaphocephaly with prominent forehead, bitemporal depression, camptodactyly, caudal appendage with sacral dimple
110	Treacher Collins syndrome 1	154500	861	AD, AR	TCOF1, POLR1D, POLR1C	Treacle protein, RNA polymerase I subunit C, subunit D		Antimongoloid eyes, coloboma of the lid, micrognathia, microtia, cleft palate, hypoplastic zygomatic arches, macrostomia, ears anomaly/conductive hearing loss
111	Van der Woude syndrome	119300	888	AD	IRF6	Intriferon regulatory factor 6		Pits and/or sinuses of the lower lip, and cleft lip and/or cleft palate
112	Van der Woude syndrome 2	606713	/	AD	GRHL3	Grainyhead-like protein 3 homolog		
113	Williams-Beuren syndrome	194050	904	AD	7q11.23	/		Supravalvular aortic stenosis (SVAS), intellectual disability, pulmonary artery stenosis, distinctive facial features
<b>(7) Cancers and tumors</b>								
114	Oligodontia-colorectal cancer syndrome	114500	300576	AD	AXIN2	Axin-2		Colorectal neoplasia
<b>(8) Intellectual disabilities</b>								
115	Down syndrome	190685	870	Isolated cases	/	/		Intellectual disability and facial dysmorphism, Risk of periodontal attachment loss

(Continues)



**TABLE 1** (Continued)

Group of dental anomaly/ name of disease	Phenotype MIM number	Orphanet number (ORPHA)	Inheritance	Gene/locus	Protein	Notes	Main manifestations
116 Glass syndrome	612313	251019	AD	SATB2	DNA-binding protein SATB2		Intellectual disability, facial dysmorphism, joint laxity, arachnodactyly
117 Hypoparathyroidism- retardation-dysmorphism syndrome	241410	2323	AR	TBCE	Tubulin specific chaperone E	Other name: Sanjad- Sakati syndrome	Growth and intellectual disability, facial dysmorphism, hypoparathyroidism
118 Larger deletion of several genes on chromosome 17q21.31	/	/	/	/	/	Tan et al., 2009, see also Koolen De Vries syndrome (MIM 610443)	Moderate to severe intellectual disability, hypotonia, friendly demeanor, highly distinctive facial features
119 Leukodystrophy, hypomyelinating, 7, with or without oligodontia and/or hypogonadotropic hypogonadism	607694	77295, 447893, 137639, 447896	AR	POLR3A	DNA-directed RNA polymerase III subunit RPC1		Neurodegenerative disorder, progressive motor decline, (spasticity, ataxia, tremor), cerebellar signs, mild cognitive regression
120 Leukodystrophy, hypomyelinating, 8, with or without oligodontia and/or hypogonadotropic hypogonadism	614381	88637	AR	POLR3B	DNA-directed RNA polymerase III subunit RPC2		Cerebellar ataxia and mild intellectual disabilities associated with diffuse hypomyelination apparent on brain MRI
121 Tetramalic deficiencies, ectodermal dysplasia, deformed ears, and others abnormalities	273400	2723	/	/	/		Malformations of all four extremities, small nails, ear anomalies, sparse scalp hair, hyperhidrosis, nasolacrymal duct obstruction
<b>Supernumerary teeth</b>							
<b>(1) Isolated</b>							
122 Teeth, supernumerary	187100	/	/	/	/	Two families, probable underdiagnosis	
123 Teeth, supernumerary	/	/	AR	CACNA1S	Calcium channel voltage- dependent, L-type, alpha 1S subunit	Laugel-Haushalter et al., 2018	
<b>(2) Eye diseases</b>							
124 Nance-Horan syndrome	302350	627	XLD	NHS	Nance-Horan syndrome protein	With screwdriver shape incisor, and molar cusp anomaly	Congenital cataracts, facial dysmorphism, intellectual disability

(Continues)

TABLE 1 (Continued)

Group of dental anomaly/ name of disease	Phenotype MIM number	Orphanet number (ORPHA)	Inheritance	Gene/locus	Protein	Notes	Main manifestations
125 Opitz GBBB syndrome, type I	300000	2745, 306597	WLR	MID1	E3 ubiquitin-protein ligase Midline-1		Hypertelorism, hypospadias, cleft lip/palate, laryngotracheoesophageal abnormalities, imperforate anus, developmental delay, cardiac defects
<b>(3) Bone diseases</b>							
126 Brachydactyly, type B1	113000	93383	AD	ROR2	Tyrosine-protein kinase transmembrane receptor ROR2		Severe malformations of the hands and feet (short fingers, absence of nails)
127 Cleidocranial dysplasia	119600	1452	AD	RUNX2	RUNT-related transcription factor 2		Open skull sutures with bulging calvaria, hypoplasia or aplasia of the clavicles, wide pubic symphysis, short middle phalanx of the fifth fingers, vertebral malformation
Cleidocranial dysplasia, forme fruste, dental anomalies only	119600		AD	RUNX2	RUNT-related transcription factor 2		
Cleidocranial dysplasia, forme fruste, with brachydactyly	119600		AD	RUNX2	RUNT-related transcription factor 2		
128 Craniosynostosis and dental anomalies	614188	284149	AR	IL11RA	Interleukine 11 receptor antagonist		Craniosynostosis, maxillary hypoplasia, syndactyly, clinodactyly
129 Odontomas dysphagia syndrome	164330	2724	/	/		One family	Hypertrophy of the smooth muscles of the esophagus, severe dysphagia
130 Robinow syndrome, autosomal recessive	268310	97360, 1507	AR	ROR2	Tyrosine-protein kinase transmembrane receptor ROR2		Facial dysmorphism (frontal bossing, hypertelorism, and broad nose), short-limbed dwarfism, vertebral segmentation, short stature, clinodactyly, short hand, genital hypoplasia
131 Robinow syndrome, autosomal dominant 1	180700	97360, 3107	AD	WNT5A	Protein Wnt-5a		
132 Robinow syndrome, autosomal dominant 3	616894	97360, 3107	AD	DVL3	Segment polarity protein disheveled homolog		

(Continues)

**TABLE 1** (Continued)

Group of dental anomaly/ name of disease	Phenotype MIM number	Orphanet number (ORPHA)	Inheritance	Gene/locus	Protein	Notes	Main manifestations
133 Trichorhinophalangeal syndrome, type I	190350	77258	AD	TRPS1	Zing finger transcription factor TRPS1		Sparse scalp hair, broad nasal tip, long flat philtrum, thin upper vermilion border, protruding ears, skeletal abnormalities (cone-shaped epiphyses at the phalanges, hip malformations), short stature
134 Trichorhinophalangeal syndrome, type III	190351		AD	TRPS1	Zing finger transcription factor TRPS1		Space scalp hair, convex nasal ridge, long upper lip, short metacarpal phalanges
<b>(4) Cancer and tumor</b>							
135 Gardner syndrome	175100	733, 220460, 247806, 79665, 99818	AD	APC	Adenomatous polyposis coli protein		Adenomatous polyps of the colon and rectum, predisposition to cancer
<b>(5) Natal teeth</b>							
136 Natal teeth-intestinal pseudooobstruction-patent ductus syndrome	243185	1654	/	/	/	One family	Patent ductus arteriosus, intestinal pseudooobstruction evident from birth
137 Steatocystoma multiplex- natal teeth syndrome	184510	3184	/	/	/	One family	Multiple steatocystomas
138 Beare-Stevenson cutis gyrate syndrome	123790	1555	AD	FGFR2	Fibroblast growth factor receptor 2		Craniosynostosis, ear defects, cutis gyrate, acanthosis nigricans, anogenital anomalies, skin tags, prominent umbilical stump
139 Mohr syndrome	252100	2751	/	/	/		Poly-, syn-, and brachydactyly, lobate tongue with papilliform protuberances, angular form of the alveolar process of the mandible, supernumerary sutures in the skull, an episodic neuromuscular disturbance
<b>Dental morphology anomalies (size and shape)</b>							
<b>(1) Microdontia</b>							
<b>(1.1) Isolated</b>							
140 Dentin dysplasia, type I, with microdontia and misshapen teeth	125400	314721, 1653	AR	SMOC2	Secreted modular calcium binding protein 2		
141 Taurodontism, microdontia, and dens invaginatus	313490	/	/	/	/	One family	
<b>(1.2) Syndromic</b>							

(Continues)

TABLE 1 (Continued)

Group of dental anomaly/ name of disease	Phenotype MIM number	Orphanet number (ORPHA)	Inheritance	Gene/locus	Protein	Notes	Main manifestations
142 Cartilage-hair hypoplasia	250250	175	AR	RMRP	Mitochondrial RNA-processing endoribonuclease		Short-limbed dwarfism, slow growing hair, short stature, short hand, metaphyseal lesions
143 Craniofacial dysmorphism, skeletal anomalies, and intellectual disability syndrome	213980	1394	AR	TMCO1	Calcium load-activated calcium channel		Facial dysmorphism, multiple malformations of the vertebrae and ribs, and intellectual disability
144 Deafness, congenital with inner ear agenesis, microtia, and microdontia	610706	90024	AR	FGF3	Fibroblast growth factor 3		Congenital deafness with inner ear agenesis, microtia
145 Filippi syndrome	272440	3255	AR	CKAP2L	Cytoskeleton associated protein 2 like		Short stature, microcephaly, syndactyly, intellectual disability, and facial dysmorphism
146 Genitopatellar syndrome	606170	85201	AD	KAT6B	Histone acetyltransferase KAT6B		Fusion of the proximal or distal interphalangeal joints (arthrogryposis of hips and knees), patellar aplasia
147 Gorlin-Chaudhry-Moos syndrome, GCMS	233500	2095	/	/	/		Stocky body build, hypertrichosis, craniostynosis, conductive hearing loss, normal intelligence, hyperopia, facial dysmorphism, hypoplastic distal phalanges, umbilical hernia, and genital hypoplasia
148 Lenz-Majewski hyperostotic dwarfism	151050	2658	AD	PTDSS1	Phosphatidylserine synthase 1		Intellectual disability, facial dysmorphism, loose/atrophic skin, distal limb anomalies, short hand, hyperostotic dwarfism
149 Ohdo syndrome	249620	2728	/	/	/		Intellectual disability, congenital heart disease, blepharophimosis, blepharoptosis, hearing impairment
150 Microcephalic osteodysplastic primordial dwarfism, type II (MOPD II)	210720	2637	AR	PCNT	Pericentrin		Intrauterine growth retardation, severe proportionate short stature, and microcephalic dwarfism
151 Microcephaly, macrotia, and intellectual disability	602555	/	/	/	/	One family	Microcephaly, intellectual disability, huge ears with very large lobules, median frenulum of the upper lip, ptosis, bilateral ureterohydronephrosis secondary to vesicoureteral reflux

(Continues)

**TABLE 1** (Continued)

Group of dental anomaly/ name of disease	Phenotype MIM number	Orphanet number (ORPHA)	Inheritance	Gene/locus	Protein	Notes	Main manifestations
152 Multiple congenital anomalies-hypotonia-seizures syndrome 2	300868	300496	XLR	PIGA	Phosphatidylinositol N-acetylglucosaminyl transferase subunit A		Facial dysmorphism, neonatal hypotonia, myoclonic seizures, and variable congenital anomalies involving the central nervous, cardiac, urinary systems
153 Rossell-Guilenetti syndrome	225000	/	/	/	/	One family	Anhidrosis, hypotrichosis, samll nails, cleft lip and palate, deformity of the fingers and toes, malformation in the genitourinary system
154 Seckel syndrome 1	210600	808	AR	ATR	Serine/threonine-protein kinase ATR		Intrauterine growth retardation, dwarfism, microcephaly with intellectual disability, facial dysmorphism
155 Smith-Lemli-Opitz syndrome	270400	818	AR	DHCR7	7-dehydrocholesterol reductase		Multiple congenital malformation (cardiovascular, genitointestinal), intellectual disability, autistic traits, growth retardation
156 Symphalangism, distal, with microdontia, dental pulp stones, and narrowed zygomatic arch	606895	/	/	/	/	One family	Fusion of the proximal or distal interphalangeal joints
157 Turner syndrome	/	/	/	/	/		Short stature, ovarain failure
<b>(2) Macrodonitia</b>							
158 KBG syndrome	148050	2332	AD	ANKRD11	Ankyrin repeat domain containing protein 11		Macrodonitia of the upper central incisors, facial dysmorphism, short stature, skeletal anomalies, and neurologic involvement that includes global developmental delay, seizures, and intellectual disability
159 Microphthalmia, syndromic 2	300166	568, 2712	XLD	BCOR	BCL6 corepressor		Congenital cataract, microphthalmia, atrial septal defect
160 Otodontal dysplasia chromosome deletion syndrome	166750	99806, 2791	AD	FGF3, FADD	Fibroblast growth factor 3, FAS-associated death domain protein		Sensorineural hearing loss, ocular coloboma, facial dysmorphism
161 Surmumerary X Klinefelter syndrome	/	484	/	/	/	With taurodontism	Hypogonadism, intellectual disability, genital anomalies

(Continues)

TABLE 1 (Continued)

Group of dental anomaly/ name of disease	Phenotype MIM number	Orphanet number (ORPHA)	Inheritance	Gene/locus	Protein	Notes	Main manifestations
<b>(3) Talon cusp</b>							
162 Rubinstein-Taybi syndrome	180849	783, 353277	AD	CREBBP, EP300	CREB binding protein; P300		Intellectual disability, postnatal growth deficiency, microcephaly, short and broad thumbs and halluces, facial dysmorphism
163 Temtamy preaxial brachydactyly syndrome	605282	363417	AR	CHSY1	Chondroitin sulfate synthase 1	One patient with hypodontia	Intellectual disability, sensorineural deafness, growth retardation, broad fingers
<b>(4) Taurodontism</b>							
164 Ackerman syndrome	200970	2561	/	/	/	One family	Juvenile glaucoma
<b>(5) Others shape disorder</b>							
165 Microphthalmia, syndromic 3	206900	77298	AD	SOX2	Transcription factor SOX-2		Microphthalmia (with or without defects of the optic nerve, optic chiasm, and optic tract), brain anomalies, seizures, motor disability, neurocognitive delays, sensorineural hearing loss, esophageal atresia
166 Ablepharon-macrostomia syndrome	200110	920	AD	TWIST2	Twist-related protein 2		Ectodermal dysplasia, ablepharon, macrostomia, microtia, redundant skin, sparse scalp hair, variable abnormalities of the nipples, genitalia, syndactyly of hands and feet, normal intellectual and motor development, growth retardation
167 Schimke immunosseous dysplasia	242900	1830	AR	SMARCA1	SWI/SNF-related matrix-associated actin-dependent regulator of chromatin subfamily A-like protein 1	Bulbous dental crown, thin and short root	Combined immunodeficiency with associated or syndromic features: Spondyloepiphyseal dysplasia with a peculiar clinical phenotype, short stature, facial dysmorphism, numerous lentigines, a slowly progressive immune defect, and an immune-complex nephritis which leads to death at about age 8 years
168 Molar-incisor malformation and ciliary dysfunction	/	/	AR	TCTEX1D2	TCTEX1D2 protein		Congenital heart defects, laterality defects

(Continues)

**TABLE 1** (Continued)

Group of dental anomaly/ name of disease	Phenotype MIM number	Orphanet number (ORPHA)	Inheritance	Gene/locus	Protein	Notes	Main manifestations
<b>Enamel anomalies (affecting temporary and permanent teeth)</b>							
<b>(1) Isolated</b>							
169 Amelogenesis imperfecta, type IA	104530	88661, 100031	AD	LAMB3	Laminin beta 3		
170 Amelogenesis imperfecta, type IB	104500		AD	ENAM	Enamelin		
171 Amelogenesis imperfecta, type IC	204650		AR	ENAM	Enamelin		
172 Amelogenesis imperfecta, type IF	616270		AR	AMBN	Ameloblastin		
173 Amelogenesis imperfecta, type IH	616221	88661, 100031, 100032	AR	ITGB6	Integrin beta 6		
174 Amelogenesis imperfecta, hypoplastic/ hypomaturation type 1E	301200	88661, 100033	XLD	AMELX	Amelogenin		
175 Amelogenesis imperfecta, hypoplastic/ hypomaturation, X- linked 2	301201	88661, 100031	XL	/	/		
176 Amelogenesis imperfecta, type IIA1	204700	88661, 100033	AR	KLK4	Kallikrein-related peptidase 4		
177 Amelogenesis imperfecta, type IIA2	612529		AR	MMP20	Matrix metalloproteinase 20		
178 Amelogenesis imperfecta, hypomaturation type IIA3	613211		AR	WDR72	WD repeat-containing protein 72		
179 AIH, hypomature type, IIA4	614832		AR	C4orf26	Uncharacterized protein C4orf26		
180 Amelogenesis imperfecta, type IIA5	615887		AR	SLC24A4	Sodium/potassium/ calcium exchanger 4		
181 Amelogenesis imperfecta, type III	130900	88661, 100032	AD	FAM83H	Protein FAM83H		
182 Amelogenesis imperfecta, type IV	104510	88661, 100034	AD	DLX3	Homeobox protein DLX- 3	With taurodontism	
183 Amelogenesis imperfecta	/	/	/	ARHGAP6	Rho GTPase-activating protein 6		
184 Amelogenesis imperfecta	/	/	AD	LAMA3	Laminin alpha 3	Kim et al., 2013	
185 Amelogenesis imperfecta	/	/	AD	AMTN	Amelotin	Smith et al., 2016	
186 Amelogenesis imperfecta	/	/	AR	ACPT	Acid phosphatase testicular	Seymen et al., 2016	

(Continues)

TABLE 1 (Continued)

Group of dental anomaly/ name of disease	Phenotype MIM number	Orphanet number (ORPHA)	Inheritance	Gene/locus	Protein	Notes	Main manifestations
187 Amelogenesis imperfecta	/	/	AR	GPR68	Proton sequencing G protein-coupled receptor	Parry et al., 2016	
188 Epithelial recurrent erosion dystrophy	122400	293381	AD	COL17A1	Collagen 17 alpha 1		
189 Amelogenesis imperfecta	/	/	AR	RELT	Tumor necrosis factor receptor superfamily member 19 like	Kim et al., 2018	
<b>(2) Skin disorders</b>							
190 Amelonychohypohidrotic syndrome	104570	1028	/	/	/	One family, probable undiagnosis	Onycholysis with subungual hyperkeratosis, hypohidrosis
191 Arthrogyposis and ectodermal dysplasia	601701	3354	/	/	/		Trichodysplasia, dry skin with scaling, hyperchromic spots on the limbs, hyperkeratosis, small nails, short of stature, kyphoscoliosis, facial dysmorphism, ocular anomalies
192 Cutaneous telangiectasia and cancer syndrome, familial	614564	313846	AD	ATR	Serine/threonine-protein kinase ATR		Cutaneous telangiectasia, mild developmental anomalies of hair and nails, predisposition to cancer (predominantly oropharyngeal)
193 Ectodermal dysplasia-syndactyly syndrome 2	613576	247827	AR	7p21.2-p14.3	/	One family	Cutaneous syndactyly, sparse scalp hair, palmoplantar keratoderma, hyperhidrosis
194 Ectodermal dysplasia, hypohidrotic, with hypothyroidism and agenesis of the corpus callosum	225040	1812	/	/	/	Probable contiguous to MIM 225050	Severe intellectual disability, hypohidrotic ectodermal dysplasia, primary hypothyroidism, agenesis of the corpus callosum
195 Epidermolysis bullosa, generalized atrophic benign	226650	79402, 79405, 251393, 89840	AR	LAMA3	Laminin alpha 3		Blistering of the skin
196 Epidermolysis bullosa, junctional, Herlitz type	226700	79404	AR	LAMA3	Laminin alpha 3		
197 Epidermolysis bullosa, junctional, Herlitz type	226700		AR	LAMB3	Laminin beta 3		
198 Epidermolysis bullosa, junctional, non-Herlitz type	226650	79402, 79405, 251393, 89840	AR	LAMB3	Laminin beta 3		

(Continues)



**TABLE 1** (Continued)

Group of dental anomaly/ name of disease	Phenotype MIM number	Orphanet number (ORPHA)	Inheritance	Gene/locus	Protein	Notes	Main manifestations
199 Epidermolysis bullosa, junctional, Herlitz type	226700	79404	AR	LAMC2	Laminin gamma 2		
200 Epidermolysis bullosa, junctional, non-Herlitz type	226650	79402, 79405, 251393, 89840	AR	LAMC2	Laminin gamma 2		
201 Epidermolysis bullosa, junctional, non-Herlitz type	226650		AR	ITGB4	Integrin beta 4		
202 Epidermolysis bullosa of hands and feet	131800	79400	AD	ITGB4	Integrin beta 4		
203 Epidermolysis bullosa, junctional with pyloric atresia	226730	79403	AR	ITGB4	Integrin beta 4		
204 Epidermolysis bullosa, junctional with pyloric atresia	226730		AR	ITGA6	Integrin alpha 6		
205 Epidermolysis bullosa, junctional, localisata variant Epidermolysis bullosa, junctional, non-Herlitz type	226650	79402, 79405, 251393, 89840	AR	COL17A1	Collagen 17 alpha 1		
206 Epidermolysis bullosa, late-onset localized junctional with intellectual disability	226440	231556	/	/	/		Late-onset epidermolysis bullosa localized to the anterior aspect of the legs, small nails, intellectual disability
207 Ichthyosis, leukocyte vacuoles, alopecia, and sclerosing cholangitis	607626	59303	AR	CLDN1	Claudin 1		Space scalp hair, scarring alopecia, sclerosing cholangitis, leukocyte vacuolization, hepatic disease
208 IFAP syndrome with or without BRESHECK syndrome	308205	85284, 2273	XLR	MBTPS2	Membrane-bound transcription factor site-2 protease		Ichthyosis follicularis, alopecia, photophobia
209 Immunodeficiency 9	612782	169090, 317428	AR	ORAI1	Calcium release-activated calcium channel protein 1		Combined immunodeficiency with associated or syndromic features: recurrent infections, myopathy, autoimmunity, ectodermal dysplasia
210 Keratosis follicularis spinulosa decalvans, autosomal dominant; KFSD	612843	2340	/	/	/		Follicular hyperkeratosis, progressive cicatricial alopecia, photophobia, corneal dystrophy, facial erythema

(Continues)

TABLE 1 (Continued)

Group of dental anomaly/ name of disease	Phenotype MIM number	Orphanet number (ORPHA)	Inheritance	Gene/locus	Protein	Notes	Main manifestations
211 Laryngochochocutaneous syndrome	245660	2407	AR	LAMA3	Laminin alpha 3		Hoarseness, dystrophic changes in the nails, and chronic bleeding, crusted lesions of the skin of the face, respiratory obstruction
212 LADD syndrome	149730	2363	AD	FGFR3	Fibroblast growth factor receptor 3		Anomalies of lacrimal glands and ducts, salivary glands and ducts, ears, distal limb segments, hearing loss, fingers malformation
213 LADD syndrome	149730		AD	FGF10	Fibroblast growth factor 10		
214 LADD syndrome	149730		AD	FGFR2	Fibroblast growth factor receptor 2		
215 Naegeli-Franceschetti- Jadassohn syndrome	161000	69087	AD	KRT14	Keratin 14		Reticular cutaneous pigmentation, hypohidrosis, moderate hyperkeratosis of the palms and soles, absence of fingerprints
216 Schimmelpemning- Feuerstein-Mims syndrome, somatic mosaic	163200	2612	/	NRAS	GTPase NRas		Sebaceous nevi (often on the face), variable ipsilateral abnormalities of the central nervous system, ocular anomalies, skeletal defects
217 Schimmelpemning- Feuerstein-Mims syndrome, somatic mosaic	163200		Isolated cases	HRAS	GTPase HRas		
218 Schimmelpemning- Feuerstein-Mims syndrome, somatic mosaic	163200		Isolated cases	KRAS	GTPase KRas		
219 Shaheen syndrome	615328	363523	AR	COG6	Conserved oligomeric Golgi complex subunit 6		Severe intellectual disability, hypohidrosis, hyperkeratosis of the palms and soles, mild microcephaly
220 Trichodontonychia dysplasia with bone deficiency	275450	3355	/	/	/	One family	Ectodermal dysplasia, supernumerary nipples, nevus pigmentosus, bone deficiency in the frontoparietal region
221 Tuberous sclerosis-1	191100	805	AD	TSC1	Hamartin		Hamartomas in multiple organ systems (brain, skin, heart, kidneys, lung)
222 Tuberous sclerosis-2	613254		AD	TSC2	Tuberin		

(Continues)

TABLE 1 (Continued)

Group of dental anomaly/ name of disease	Phenotype MIM number	Orphanet number (ORPHA)	Inheritance	Gene/locus	Protein	Notes	Main manifestations
<b>(3) Eye diseases</b>							
223 Jallili syndrome	217080	1873	AR	CNNM4	Metal transporter CNNM4		Cone-rod dystrophy of the retina
224 Microphthalmia with linear skin defects	309801	2556	XLD	Xp22			Microphthalmia and linear skin defects
225 Microphthalmia, dermal aplasia, and sclerocornea	309801		XLD	Xp22			
226 Microphthalmia, syndromic 1, MCOPS1	309800	568	XL	NAA10	N-Alpha- acetyltransferase 10		Microphthalmia or anophthalmia, defects in the skeletal and genitourinary systems, ear, digits anomalies
<b>(4) Bone diseases</b>							
227 Alopecia-contractura dwarfis intellectual disability syndroms	203550	1005	/	/	/		Short stature, kyphoscoliosis, bilateral dislocation of the hips, contracture of multiple joints present from birth, facial dysmorphism, ichthyosis, ectrodactyly, intellectual disability, photophobia
228 Cockayne syndrome, type A	216400	191, 90321, 90322, 90324	AR	ERCC8	DNA excision repair protein ERCC-8		Slow growth and development, cachectic dwarfism, cutaneous photosensitivity, thin, dry hair, a progeroid appearance, progressive pigmentary retinopathy, sensorineural hearing loss
229 Focal dermal hypoplasia	305600	2092	XLD	PORCN	Porcupine		Atrophy and linear pigmentation of the skin, herniation of fat through the dermal defects, multiple papillomas of the mucous membranes or skin, digits anomaly, ocular anomaly, intellectual disability
230 Hallermann-Streiff syndrome, HSS	234100	2108	/	/	/	Natal teeth	Short stature, "bird-like" face, congenital cataracts, and microphthalmia, hypotrichosis
231 Hamamy syndrome	611174	314555	AR	IRX5	Iroquois homeobox 5		Hypertelorism with midface prominence, myopia, intellectual disability, bone fragility
232 Kenny-Caffey syndrome, type 1	244460	93324, 2333	AR	TBCE	Tubulin specific chaperone E	See also Sanjad Sakati syndrome	Seizure anomaly, cortical thickening, medullary stenosis

(Continues)

TABLE 1 (Continued)

Group of dental anomaly/ name of disease	Phenotype MIM number	Orphanet number (ORPHA)	Inheritance	Gene/locus	Protein	Notes	Main manifestations
233 McCune-Albright syndrome	174800	562	/	GNAS1	Protein ALEX		Bone skeleton, skin, and endocrine system anomalies
234 Mesomelia synostosis syndrome	600383	2496	Isolated cases	8q13 del	/		Acral synostoses combined with ptosis, hypertelorism, palatal abnormality, congenital heart disease, and ureteral anomalies
235 Metaphyseal dysplasia with maxillary hypoplasia with or without brachydactyly	156510	2504	AD	RUNX2	Runt-related transcription factor 2		Bone anomalies (metaphyseal flaring of long bones), enlargement of the medial halves of the clavicles, maxillary hypoplasia, short hand, short stature, facial dysmorphology
236 Mucopolysaccharidosis 1h	607014	579	AR	IDUA	Alpha-L-Iduronidase		Coarse facies, corneal clouding, intellectual disability, hernias, dysostosis multiplex, hepatosplenomegaly, axial hypotonia
237 Mucopolysaccharidosis IVA (Morquio A)	253000	582, 309297	AR	GALNS	N-Acetylgalactosamine-6-sulfatase		Short stature, skeletal dysplasia, dental anomalies, corneal clouding
238 Multiple joint dislocations, short stature, craniofacial dysmorphism, with or without congenital heart defects	245600	284139	AR	B3GAT3	Galactosylgalactosylxylosylprotein 3-beta-glucuronosyl transferase 3		Multiple joint dislocations, short stature, craniofacial dysmorphism with or without congenital heart defects
239 Oculodentodigital dysplasia, ODDD	164200	2710	AD	GJA1	Connexin 43		Wide nasal bridge with underdeveloped ala nasi, broad columella, prominent epicanthus, microphthalmia, microcornea, syndactyly, clinodactyly
240 Oculodentodigital dysplasia, autosomal recessive	257850	2710	AR	GJA1	Connexin 43		
241 Prader-Willi syndrome	176270	739	Isolated cases	SNRPN	Small nuclear ribonucleoprotein-associated protein N		Diminished fetal activity, obesity, muscular hypotonia, intellectual disability, short stature, hypogonadotropic hypogonadism, small hands and feet

(Continues)

**TABLE 1** (Continued)

Group of dental anomaly/ name of disease	Phenotype MIM number	Orphanet number (ORPHA)	Inheritance	Gene/locus	Protein	Notes	Main manifestations
242 Prader-Willi syndrome	176270		Isolated cases	NDN	Necdin		
243 Proteus syndrome, somatic	176920	744	Sporadic mosaic	AKT1	RAC-alpha serine/ threonine-protein kinase	With gingival overgrowth	Asymmetric and disproportionate overgrowth of body parts, connective tissue nevi, epidermal nevi, dysregulated adipose tissue, vascular malformations
244 Pseudohypoparathyroidism Ia	103580	79443	AD	GNAS	Protein ALEX		Short stature, obesity, ocular disorder, osteoporosis, hypocalcemia, hyperphosphatemia, elevated PTH, short fingers, intellectual disability
245 Pycnodysostosis	265800	763	AR	CTSK	Cathepsin K		Deformity of the skull, acroosteolysis, osteosclerosis, fragility of bone
246 Raine syndrome	259775	1832	AR	FAM20C	Extracellular serine/ threonine protein kinase FAM20C		Neonatal osteosclerotic bone dysplasia, usually death within the first few weeks of life
247 Rickets, vitamin D-resistant, type IIA	277440	93160	AR	VDR	Vitamin D receptor		Hypocalcemia, secondary hyperparathyroidism, osteomalacia, and osteitis fibrosa cystica, normal serum 25- hydroxyvitamin D, markedly increased serum 1,25- dihydroxyvitamin D
248 Trichodontosseous syndrome	190320	3352	AD	DLX3	Distal less homeobox 3	With taurodontism	Strikingly curly hair, mild increase in bone density
249 Skeletal dysplasia with multiple dislocations	/	/	AD	SLC10A7	SLC10A7		Short stature, joints dislocations, craniofacial dysmorphism
250 XFE progeroid syndrome, XFEPS	610965	/	AR	ERCC4	DNA repair endonuclease XPF		Dwarfism, cachexia, and microcephaly
<b>(5) Endocrine and gynecological diseases</b>							
251 Autoimmune polyendocrinopathy syndrome, type I (APECED)	240300	3453	AR, AD	AIRE	Autoimmune regulator		The presence of two of three major clinical symptoms: Addison disease and/or hypoparathyroidism and/or chronic mucocutaneous candidiasis-disease of immune dysregulation; chronic mucocutaneous candidiasis, polyendocrinopathy

(Continues)

TABLE 1 (Continued)

Group of dental anomaly/ name of disease	Phenotype MIM number	Orphanet number (ORPHA)	Inheritance	Gene/locus	Protein	Notes	Main manifestations
<b>(6) Renal diseases</b>							
252 Arthrogyposis, renal dysfunction, and cholestasis 1	208085	2697	AR	VPS33B, VIPAR	Vacuolar protein sorting-associated protein 33B, VPS33B interacting protein		(hypoparathyroidism, hypothyroidism, adrenal insufficiency, diabetes, gonadal dysfunction and other endocrine abnormalities), autoimmunity (enteropathy, alopecia areata...), enamel hypoplasia
253 Enamel renal syndrome, amelogenesis imperfecta, type IG	204690	1031, 171836	AR	FAM20A	Pseudokinase FAM20A		Multiplex congenita with jaundice and renal dysfunction
254 Hypomagnesemia 5, renal, with ocular involvement	248190	2196	AR	CLDN19	Claudin-19		Renal magnesium wasting with hypercalcaemia, progressive renal failure, ocular anomaly
255 Hypomagnesemia 3, renal	248250	31043	AR	CLDN16	Claudin-16		Hypomagnesemia with hypercalcaemia and nephrocalcinosis, progressive renal disorder characterized by excessive urinary Ca <sup>2+</sup> and Mg <sup>2+</sup> excretion
256 Pseudohypoadosteronism, type IIA	145260	757, 88938	AD	1q31-q42	/		Hyperkalemia despite normal renal glomerular filtration, hypertension
257 Renal cysts and diabetes syndrome	137920	93111	AD	HNF1B	Hepatocyte nuclear factor 1-beta		Renal cysts and diabetes
<b>(7) Intellectual disabilities</b>							
258 Chromosome 17q11.2 deletion syndrome, 1.4 Mb	613675	97685, 139474, 636	AD	17q11.2 deletion	/	Deletion includes the NF1 gene	Neurofibromas, mild facial dysmorphism, intellectual disability, and/or learning disabilities
259 Epileptic encephalopathy, early infantile, 25	615905	442835	AR	SLC13A5		Solute carrier family 13 member 5	Spasticity, ataxia, choreoathetosis
260 Krabbe disease	245200	487	AR	GALC	Galactocerebrosidase		Extreme irritability, spasticity, and developmental delay (severe motor and mental deterioration)

(Continues)

TABLE 1 (Continued)

Group of dental anomaly/ name of disease	Phenotype MIM number	Orphanet number (ORPHA)	Inheritance	Gene/locus	Protein	Notes	Main manifestations
261 Krabbe disease, atypical	611722		AR	PSAP	Prosaposin		
262 Smith-Magenis syndrome	182290	819	IC, AD	RAI1	Retinoic acid-induced protein 1		Intellectual disability, hypotonia, speech delay, small ears, conductive hearing loss, esotropia
263 Syndrome de Kohlschütter-Tönz	226750	1946	AR	ROGD1	Protein rogdi homolog		Severe global developmental delay, early-onset intractable seizures, spasticity, intellectual disability
<b>(8) Ear, nose, and throat disorders</b>							
264 External auditory canal, bilateral atresia of, with congenital vertical talus	133705	3023	/	/	/		Bilateral symmetric subtotal atresia of the external auditory canal
265 Heimler syndrome 1	234580	3220	AR	PEX1	Peroxisome biogenesis factor 1		Sensorineural hearing loss, nails anomalies
266 Heimler syndrome 2	616617		AR	PEX6	Peroxisome biogenesis factor 6		
267 Usher syndrome, type 1B	276900	/	AR	MYO7A	Unconventional myosin-VIIa		Sensorineural hearing deficiencies at birth and later development of progressive retinitis pigmentosa (blindness in adult)
268 Usher syndrome, type 2A	276901	/	AR	USH2A, PDZD7	Usherin, PDZ domain containing 7		
269 Usher syndrome, type 2C, GPR98/PDZD7 digenic	605472	886, 231178	AR, DD	ADGRV1	G protein-coupled receptor 98		
270 Usher syndrome, type IIC, GPR98/PDZD7 digenic	605472		AR, DD	PDZD7	PDZ domain containing 7		
271 Usher syndrome, type 3A	276902	231183	AR	CLRN1	Clarin 1		
<b>(9) Immunological diseases</b>							
272 Immunodeficiency 10	612783	169090, 317430	AR	STIM1	Stromal interaction molecule 1		Combined immunodeficiency with associated or syndromic features: recurrent infections, myopathy, partial iris hypoplasia, autoimmunity, ectodermal dysplasia

(Continues)

TABLE 1 (Continued)

Group of dental anomaly/ name of disease	Phenotype MIM number	Orphanet number (ORPHA)	Inheritance	Gene/locus	Protein	Notes	Main manifestations
<b>(10) Heart defects</b>							
273 DiGeorge/velocardiofacial syndrome or chromosome 22q11.2 deletion syndrome	188400, 192430	567	AD	Large deletion (3 Mb) in chromosome 22			Combined immunodeficiency with associated or syndromic features; immune deficiency due to thymic aplasia/hypoplasia, conotruncal cardiac malformation, velopalatal insufficiency, facial dysmorphism, intellectual disability, enamel hypoplasia
<b>Dentin anomalies (affecting temporary and permanent teeth)</b>							
<b>(1) Isolated</b>							
274 Deafness, autosomal dominant 36, with dentinogenesis	605594	166260	AD	DSPP	Dentin sialophosphoprotein		
275 Dentin dysplasia type I	/	1653, 99789	AD	VPS4B, SSUH2	Vacuolar protein sorting 4 homolog B, SSUH2	Yang et al., 2016; Xiong et al., 2017	
276 Dentin dysplasia, type II	125420	1653	AD	DSPP	Dentin sialophosphoprotein		
277 Dentinogenesis imperfecta, shields type II	125490	166260	AD	DSPP	Dentin sialophosphoprotein		
278 Dentinogenesis imperfecta, shields type III	125500	166265	AD	DSPP	Dentin sialophosphoprotein		
<b>(2) Eye diseases</b>							
279 Brittle cornea syndrome 1	229200	90354	AR	ZNF469	Zinc finger protein 469		Blue sclerae, corneal rupture after minor trauma, keratoconus or keratoglobus, hyperelasticity of the skin, hypermobility of the joints
<b>(3) Bone diseases</b>							
280 Bruck syndrome 1	259450	2771	AR	FKBP10	Peptidyl-prolyl cis-trans isomerase FKBP10		Congenital contractures with pterygia, onset of fractures in infancy or early childhood, postnatal short stature, severe limb deformity, and progressive scoliosis

(Continues)



TABLE 1 (Continued)

Group of dental anomaly/ name of disease	Phenotype MIM number	Orphanet number (ORPHA)	Inheritance	Gene/locus	Protein	Notes	Main manifestations
281 Caffey disease	114000	1310	AD	COL1A1	Collagen type 1 alpha 1		Inflammatory in nature, with fever and hot, tender swelling of involved bones (mandible, ribs)
282 Cortical defects, wormian bones, and dentinogenesis imperfecta	604922	166277	/	/	/		Short, thick arms and fingers, a broad and vonxev nasal bridge, multiple fractures
283 Dentin dysplasia with sclerotic bones	125440	99792	/	/	/		
284 Ehlers-Danlos syndrome, classic	130000	287	AD	COL1A1	Collagen type 1 alpha 1	Early loss of tooth	Skin hyperextensibility, articular hypermobility, tissue fragility
285 Ehlers-Danlos syndrome, Arthrochalasia	130060	99875, 99876, 1899	AD	COL1A1	Collagen type 1 alpha 1		Hip dislocation and extreme joint laxity with recurrent joint subluxations and minimal skin involvement
286 Ehlers-Danlos syndrome, cardiac-valvular	225320	230851	AR	COL1A2	Collagen type 1 alpha 2		Bone fragility with normal sclera
287 Ehlers-Danlos syndrome, Arthrochalasia	130060	99875, 99876, 1899	AD	COL1A2	Collagen type 1 alpha 2		Hip dislocation and extreme joint laxity with recurrent joint subluxations and minimal skin involvement
288 Fanconi renotubular syndrome 2	613388	3337	AD	SLC34A1	Sodium-dependent phosphate transport protein 2A		Severe rickets and osteopenia, marked hypercalciuria without renal tubular acidosis
289 Hypophosphatemic rickets with hypercalciuria	241530	157215	AR	SLC34A3	Sodium-dependent phosphate transport protein 2C		Hypophosphatemia secondary to renal phosphate wasting, radiographic and/or histologic evidence of rickets, limb deformities, muscle weakness, bone pain
290 Hypophosphatemic rickets, X-linked dominant	307800	89936	XLD	PHEX	Phosphate-regulating neutral endopeptidase		Rickets with bone deformities, short stature, hypophosphatemia, low renal phosphate reabsorption, normal serum calcium level with hypocalciuria, normal or low serum level of vitamin D (1,25 [OH]2D3, or calcitriol), normal serum level of PTH, and increased activity of serum alkaline phosphatases

(Continues)

TABLE 1 (Continued)

Group of dental anomaly/ name of disease	Phenotype MIM number	Orphanet number (ORPHA)	Inheritance	Gene/locus	Protein	Notes	Main manifestations
291 Hypophosphatemic rickets, autosomal dominant	193100	89937	AD	FGF23	Fibroblast growth factor 23		Rickets with isolated renal phosphate wasting, hypophosphatemia, inappropriately normal 1,25- dihydroxyvitamin D3 (calcitriol) levels
292 Hypophosphatemic rickets, AR	241520	289176	AR	DMP1	Dentin matrix acidic phosphoprotein 1		Rickets hypophosphatemia with elevated FGF23
293 Hypophosphatemic rickets, autosomal recessive, 2	613312		/	ENNPP1	Ectonucleotide pyrophosphatase/ phosphodiesterase family member 1		Rickets hypophosphatemia
294 Hypophosphatemic rickets and hyperparathyroidism	612089	/	AD	/	/		Hypophosphatemic rickets and hyperparathyroidism
295 McCune-Albright syndrome, somatic, mosaic	174800	562	/	GNAS1	Protein ALEX		Bone skeleton, skin, and endocrine system anomalies
296 Nephrolithiasis/osteoporosis, hypophosphatemic, 2	612287	244305	AD	SLC9A3R1	Na(+)/H(+) exchange regulatory cofactor NHE-RF1		Hypophosphatemia and decreased renal phosphate resorption
297 Osteogenesis imperfecta, type I	166200	666, 216796	AD	COL1A1	Collagen type 1 alpha 1		Bone fragility and blue sclerae
298 Osteogenesis imperfecta, type II	166210	666, 216804	AD	COL1A1	Collagen type 1 alpha 1		Perinatal fractures, severe bowing of long bones, undermineralization, and death in the perinatal period due to respiratory insufficiency
299 Osteogenesis imperfecta, type III	259420	666, 216812	AD	COL1A1	Collagen type 1 alpha 1		Bone fragility with progressive deformity, with normal sclera
300 Osteogenesis imperfecta, type IV	166220	666, 216820	AD	COL1A1	Collagen type 1 alpha 1		Bone fragility with progressive deformity, with normal sclera
301 Osteogenesis imperfecta, type II	166210	666, 216804	AD	COL1A2	Collagen type 1 alpha 2		Perinatal fractures, severe bowing of long bones, undermineralization, and death in the perinatal period due to respiratory insufficiency
302 Osteogenesis imperfecta, type III	259420	666, 216812	AD	COL1A2	Collagen type 1 alpha 2		Bone fragility with progressive deformity, with normal sclera
303 Osteogenesis imperfecta, type IV	166220	666, 216820	AD	COL1A2	Collagen type 1 alpha 2		Bone fragility with progressive deformity, with normal sclera

(Continues)

TABLE 1 (Continued)

Group of dental anomaly/ name of disease	Phenotype MIM number	Orphanet number (ORPHA)	Inheritance	Gene/locus	Protein	Notes	Main manifestations
304 Odontochondrodysplasia (Goldblatt syndrome)	184260	166272	AR	TRIP11	Thyroid hormone receptor interactor 11	Natal teeth	Spondylometaphyseal dysplasia associated with joint laxity
305 Tumoral calcinosis, hyperphosphatemic, familial	211900	306661, 53715	AR	GALNT3	Polypeptide N-acetylgalactosam inyltransferase 3		Progressive deposition of basic calcium phosphate crystals in periarticular spaces, soft tissues, and sometimes bone
306 Tumoral calcinosis, hyperphosphatemic, familial	211900		AR	FGF23	Fibroblast growth factor 23		
307 Tumoral calcinosis, hyperphosphatemic	211900		AR	KL	Klotho		
308 Vitamin D-dependent rickets, type I	264700	289157	AR	CYP27B1	25-hydroxyvitamin D-1 alpha hydroxylase, mitochondrial	Enamel anomaly	Intestinal malabsorption of calcium, hypocalcemia, secondary hyperparathyroidism, increased renal clearance of phosphorus, and hypophosphatemia
<b>Dental eruption/position anomalies</b>							
<b>(1) Delayed eruption</b>							
<b>(1.1) Isolated</b>							
309 Failure of tooth eruption, primary	125350	412206	AD	PTHRI	Parathyroid hormone receptor 1		
<b>(1.2) Syndromic</b>							
310 Barber-Say syndrome	209885	1231	AD	TWIST2	Twist-related protein 2		Severe hypertrichosis, skin abnormalities (hyperlaxity and redundancy), facial dysmorphism, including macrostomia, eyelid deformities, ocular telecanthus, abnormal and low-set ears, bulbous nasal tip with hypoplastic alae nasi, low frontal hairline
311 Chondrodysplasia, Blomstrand type	215045	50945	AR	PTHRI	Parathyroid hormone receptor 1		Short limbs, polyhydramnios, hydrops fetalis, facial anomalies, increased bone density, advanced skeletal maturation
312 CODAS syndrome	600373	1458	AR	LONP1	Lon protease homolog, mitochondrial		Developmental delay, craniofacial anomalies, cataracts, ptosis, median nasal groove, hearing loss, short stature, delayed epiphyseal ossification, metaphyseal hip dysplasia, vertebral coronal clefts

(Continues)

TABLE 1 (Continued)

Group of dental anomaly/ name of disease	Phenotype MIM number	Orphanet number (ORPHA)	Inheritance	Gene/locus	Protein	Notes	Main manifestations
313 Eiken syndrome	600002	79106	AR	PTHRI	Parathyroid hormone receptor 1		Retarded ossification
314 Metaphyseal chondrodysplasia, Murk Jansen type	156400	33067	AD	PTHRI	Parathyroid hormone receptor 1		Short stature, short bowed limbs, clinodactyly, prominent upper face, small mandible, hypercalcemia and hypophosphatemia
315 Premature aging syndrome, Penttinen type	601812	363665	AD	PDGFRB	Platelet-derived growth factor receptor beta		Lipoatrophy, epidermal and dermal atrophy, hypertrophic lesions that resemble scars, thin hair, proptosis, underdeveloped cheekbones, marked acroosteolysis
316 Sclerosteosis 1	269500	3152	AR	SOST	Sclerostin		Progressive skeletal overgrowth, syndactyly
317 SHORT syndrome	269880	3163	AD	PIK3R1, IGF1R	Phosphatidylinositol 3-kinase regulatory subunit alpha, insulin growth factor 1 receptor		S = stature; H = hyperextensibility of joints or hernia (inguinal) or both; O = ocular depression; R = Rieger anomaly; T = teething delay
318 Singleton-Merten syndrome 1	182250	85191	AD	IFIH1	Interferon-induced helicase C domain-containing protein 1		Calcifications of the aorta and aortic and mitral valves, osteoporosis
319 Waardenburg syndrome, type 2E, with or without neurologic involvement	611584	3440, 895	AD	SOX10	Transcription factor SOX-10		Pigmentary abnormalities of the hair, skin, and eyes, congenital sensorineural hearing loss
320 Wrinkly skin syndrome	278250	357058, 2834	AR	ATP6VOA2	V-type proton ATPase 116 kDa subunit a isoform 2		Wrinkled skin of the hands, hypotony
<b>(2) Ectopic eruption</b>							
<b>(2.1) Isolated</b>							
321 Malposition of teeth with or without hypodontia/ oligodontia	189490	/	/	/	/		
<b>(3) Failure of eruption</b>							
<b>(3.1) Isolated</b>							
322 Impacted teeth, multiple	308280	/	/	/	/		Probable underdiagnosed syndrome

(Continues)

TABLE 1 (Continued)

Group of dental anomaly/ name of disease	Phenotype MIM number	Orphanet number (ORPHA)	Inheritance	Gene/locus	Protein	Notes	Main manifestations
323 Permanent molars, secondary retention of	157950	/	/	/	/		
<b>(3.2) Syndromic</b>							
324 GAPO syndrome	230740	2067	AR	ANTXR1	Anthrax toxin receptor 1		Growth retardation, alopecia, progressive optic atrophy, facial dysmorphism
325 Osteopetrosis, autosomal dominant 1	607634	2783	AD	LRP5	Low-density lipoprotein receptor-related protein 5		Increased bone density due to impaired bone resorption by osteoclasts
326 Osteopetrosis, autosomal dominant 2	166600	53	AD, AR	CLCN7	H(+)/Cl(-) exchange transporter 7		Sclerosis, predominantly involving the spine, the pelvis, and the skull base. Fragility of bones
327 Osteopetrosis, autosomal recessive 1	259700	667	AR	TCIRG1	V-type proton ATPase 116 kDa subunit a isoform 3		Macrocephaly and frontal bossing, respiratory problems, increase bone density
328 Osteopetrosis, autosomal recessive 3, with renal tubular acidosis	259730	2785	AR	CA2	Carbonic anhydrase II		Short stature, bone fracture, intellectual disability, dental malocclusion
329 Osteopetrosis, autosomal recessive 2	259710	667	AR	TNFSF11	Tumor necrosis factor ligand superfamily member 11		Genu valgum, anemia, hepatosplenomegaly, and tendency to fracture and mandibular osteomyelitis
330 Osteopetrosis, autosomal recessive 4	611490	667	AR	CLCN7	H(+)/Cl(-) exchange transporter 7		Increase bone density
331 Osteopetrosis, autosomal recessive 5	259720	85179	AR	OSTM1	Osteopetrosis associated transmembrane protein 1		Increase bone density
332 Osteopetrosis, autosomal recessive 6	611497	210210	AR	PLEKHM1	Pleckstrin homology domain-containing family M		Increase bone density
333 Osteopetrosis, autosomal recessive 7	612301	178389	AR	TNFRSF11A	Tumor necrosis factor receptor superfamily member 11A	One family	Severe genu valgum
334 Glycogen storage disease Ia (von Gierke disease)	232200		AR	G6PC	Glucose-6-phosphatase		Growth retardation, delayed puberty, lactic acidemia, hyperlipidemia, hyperuricemia, hepatic adenomas
335 Glycogen storage disease III	232400		AR	AGL	Glycogen debrancher enzyme		Hepatosplenomegaly, hypoglycemia and growth retardation, muscle weakness

(Continues)

TABLE 1 (Continued)

Group of dental anomaly/ name of disease	Phenotype MIM number	Orphanet number (ORPHA)	Inheritance	Gene/locus	Protein	Notes	Main manifestations
336 Glycogen storage disease Ia	306000		XLR	PHKA2	Alpha-2 subunit of hepatic phosphorylase kinase		Hepatomegaly, hypoglycemia and growth retardation, muscle weakness in infancy. Adults are asymptomatic
<b>(4) Premature loss of teeth</b>							
337 Hajdu-Cheney syndrome	102500	955	AD	NOTCH2	Neurogenic locus notch homolog protein 2		Facial dysmorphism, bowing of the long bones, vertebral anomalies, acro-osteolysis of phalanges of hand and feet, short stature
338 Hypophosphatasia, adult	146300	247676, 436, 247685	AR, AD	ALPL	Alkaline phosphatase, tissue-nonspecific isozyme		Mild bone fragility, osteomalacia, pseudofracture, history of rickets
339 Hypophosphatasia, childhood	241510	247667, 436	AR	ALPL	Alkaline phosphatase, tissue-nonspecific isozyme		Defective bone mineralization and biochemically, short stature, skeletal deformities, motor impairment, fatigue easily
340 Hypophosphatasia, infantile	241500	436, 247651, 247623	AR	ALPL	Alkaline phosphatase, tissue-nonspecific isozyme		Defective bone mineralization and biochemically before 6 month, rickets, failure to thrive, hypotonia
341 Mandibuloacral dysplasia	248370	2457, 90153	AR	LMNA	Lamin		Growth retardation, facial dysmorphism, skeletal abnormalities (progressive osteolysis of the distal phalanges and clavicles), pigmentary skin changes
342 Mandibuloacral dysplasia with type B lipodystrophy	608612	2457, 90154	AR	ZMPSTE24	CAAX prenyl protease 1 homolog		Growth retardation, facial dysmorphism, progressive acral osteolysis, mottled or patchy pigmentation, skin atrophy, and partial or generalized lipodystrophy
343 Odontohypophosphatasia	146300	247676, 436, 247685	AR, AD	ALPL	Alkaline phosphatase, tissue-nonspecific isozyme		Mild bone fragility
344 Osteolysis, familial expansile	174810	85195	AD	TNFRSF11A	Tumor necrosis factor receptor superfamily member 11A (RANK)		Bone remodeling with osteolytic lesions, early hearing loss, osteopenia

(Continues)

**TABLE 1** (Continued)

Group of dental anomaly/ name of disease	Phenotype MIM number	Orphanet number (ORPHA)	Inheritance	Gene/locus	Protein	Notes	Main manifestations
345 Singleton-Merten dysplasia/ syndrome	182250	85191	AD	IFIH1 (MDA5)	Interferon-induced helicase C domain containing protein 1		Auto-inflammatory disorder; progressive calcification of the thoracic aorta with stenosis, osteoporosis and expansion of the marrow cavities in hand bones, generalized muscle weakness and atrophy, chronic psoriasisiform skin eruptions, delayed primary tooth exfoliation and permanent tooth eruption, truncated tooth root formation, early-onset periodontal disease, severe root and alveolar bone resorption, abnormal mineralization
346 Odontomicronychial dysplasia	601319	1811	AR	/	/	One family	Short stature, slow growing, nail alteration
<b>(5) Lack of root resorption/no exfoliation</b>							
347 Hyper-IgE syndrome (HIES) (Job syndrome)	147060	2314	AD	STAT3	Signal transducer and activator of transcription 3		Combined immunodeficiency with associated or syndromic features: chronic eczema, recurrent staphylococcal infections, pulmonary aspergillus, mucocutaneous candidiasis, hyperextensible joints, increased serum IgE, hyper eosinophilia, bone fracture, scoliosis, facial dysmorphism (facial asymmetry, prominent forehead, deep-set eyes, broad nasal bridge, fleshy nasal tip, prognathism), reduced resorption of primary tooth roots leading to prolonged retention of primary teeth and delayed eruption of permanent teeth
348 Hyper-IgE recurrent infection syndrome, autosomal recessive	243700	217390	AR	DOCK8	Dedicator of cytokinesis protein 8	Old description, may not associate with dental features	Chronic eczema, recurrent staphylococcal infections, increased serum IgE, eosinophilia, facial dysmorphism

(Continues)

TABLE 1 (Continued)

Group of dental anomaly/ name of disease	Phenotype MIM number	Orphanet number (ORPHA)	Inheritance	Gene/locus	Protein	Notes	Main manifestations
<b>Periodontal and gingival anomalies</b>							
<b>(1) Gingival overgrowth/enlargement</b>							
<b>(1.1) Isolated</b>							
349 Fibromatosis, gingival, 1	135300	2024	AD	SOS1	Son of sevenless homolog 1		
350 Fibromatosis, gingival, 2	605544		/	/	/		
351 Fibromatosis, gingival, 3	609955		/	/	/		
352 Fibromatosis, gingival, 4	611010		/	/	/		
<b>(1.2) Syndromic</b>							
353 Ehlers-Danlos syndrome, Dermatosparaxis	225410	1901	AR	ADAMTS2	A disintegrin and metalloproteinase with thrombospondin motifs 2	Oligodontia, dentin defect	Severe joint hyperextensibility and mild stretchability and bruisability of the skin
354 Ehlers-Danlos syndrome, vascular	130050	286	AD	COL3A1	Collagen 3	Papyraceous aspect of the gingiva (Ferre et al., 2012)	Joint and skin laxity, proneness to spontaneous rupture of bowel and large arteries
355 Epileptic encephalopathy, early infantile, 31	616346	2382, 442835	AD	DNM1	Dynamain 1	Three patients	Epileptic encephalopathy
356 Hyaline fibromatosis syndrome	228600	2028	AR	ANTXR2	Anthrax toxin receptor 2		Abnormal growth of hyalinized fibrous tissue usually affecting subcutaneous regions on the scalp, ears, neck, face, hands, and feet
357 Histiocytosis-lymphadenopathy plus syndrome	602782	168569, 158014	AR	SLC29A3	Equilibrative nucleoside transporter 3		Histiocytosis and lymphadenopathy with or without cutaneous, cardiac, and/or endocrine features, joint contractures, and/or deafness
358 Frank-ter Haar syndrome	249420	1266	AR	SH3PXD2B	SH3 and PX domain-containing protein 2B		Brachycephaly, wide fontanels, prominent forehead, hypertelorism, prominent eyes, macrocornea with or without glaucoma, full cheeks, small chin, bowing of the long bones, flexion deformity of the fingers
359 Hypertrichosis terminalis, generalized, with or without gingival hyperplasia	135400	2026	AR	17q24.2-q24.3 microdeletion or microduplication	/	ABCA5 gene concerned	Hypertrichosis, hirsutism

(Continues)



TABLE 1 (Continued)

Group of dental anomaly/ name of disease	Phenotype MIM number	Orphanet number (ORPHA)	Inheritance	Gene/locus	Protein	Notes	Main manifestations
360 Hypertrichosis universalis congenita, Ambras type	145701	1023, 2222	AD	8q22	/		Hypertrichosis
361 Hypertrichosis, congenital generalized	307150	2222, 79495	XLD	/	/		Hypertrichosis
362 Macrocephaly, alopecia, cutis laxa, and scoliosis	613075	217335	AR	RIN2	Ras and Rab interactor 2		Macrocephaly, alopecia, cutis laxa, scoliosis, sagging skin
363 Myofibromatosis, infantile, 1	228550	2591	AD	PDGFRB	Platelet-derived growth factor receptor B		Subcutaneous or soft tissue nodules of the skin of the head, neck, and trunk, skeletal and muscular lesions
364 Ramon syndrome	266270	3019	/	/	/		Cherubism, epilepsy, intellectual disability, hypertrichosis, stunted growth
365 Robinow syndrome, autosomal dominant 1	180700	3107, 97360	AD	WNT5A	Protein Wnt-5a		Fetal face, mesomelic limb shortening, hypoplastic external genitalia in males, renal and vertebral anomalies
366 Robinow syndrome, autosomal dominant 2	616331		AD	DVL1	Segment polarity protein disheveled homolog DVL-1		Osteosclerosis, facial features, mesomelic dwarfism, macrocephaly, genital hypoplasia, brachydactyly
367 Rutherford syndrome	180900	2709	/	/	/		Corneal dystrophy, inconstat intellectual disability
368 Fibromatosis, gingival, with hypertrichosis and intellectual disability	605400	/	/	/	/		Intellectual disability, epilepsy, short fingers, hirsutism, bulbous short nose
369 Fibromatosis, gingival wit distinctive facies	228560	2025	/	/	/	One family	Macrocephaly, bushy eyebrows with synophrys, hypertelorism, flattened nasal bridge and hypoplastic nares, cupid-bow mouth
370 Fibromatosis gingival with progressive deafness syndrome	135550	2027	/	/	/		Progressive sensorineural hearing loss
371 Acroosteolysis dominant type (Hadju Cheney syndrome)	102400, 102500	955	AD	NOTCH2	Neurogenic locus notch homolog protein 2		Acroosteolysis of distal phalanges, cranio facial dysmorphism, hypertelorism, telacanthus, micrognathia, bone anomalies, early loss of teeth

(Continues)

TABLE 1 (Continued)

Group of dental anomaly/ name of disease	Phenotype MIM number	Orphanet number (ORPHA)	Inheritance	Gene/locus	Protein	Notes	Main manifestations
372 Zimmermann-Laband syndrome 1	135500	3473	AD	KCNH1	Potassium voltage-gated channel subfamily H member 1		Dysplastic or absent nails, the absence of the distal phalanges, scoliosis, hepatosplenomegaly, hirsutism, abnormalities of the cartilage of the nose and/or ears
<b>(2) Periodontal disease</b>							
<b>(2.1) Isolated</b>							
373 Periodontitis, chronic	260950	/	/	/	/	The terms chronic, juvenile and aggressive are no more used in the new classification of periodontal disease. They are included in only one term which is periodontitis. Papapanou et al., 2018	
374 Periodontitis 1, juvenile	170650	/	AR	CTSC	Cathepsin C		
375 Periodontitis, aggressive 2	608526	/	/	/	/		
<b>(2.2) Syndromic</b>							
376 Dyskeratosis congenita, X- linked	305000	1775, 3322	XLR	DKC1	H/ACA ribonucleoprotein complex subunit 4		Combined immunodeficiency with associated or syndromic features: triad of dysplastic nails, lacy reticular pigmentation and skin atrophy (neck and upper chest) + oral leukoplakia/ increased risk for progressive bone marrow failure and risk to develop myelodysplastic syndrome or acute myelogenous leukemia / increased risk for solid tumors (squamous cell carcinoma of head and neck, anogenital cancer) / developmental delay, short stature, microcephaly, blepharitis, periodontal disease, taurodontism, decreased teeth/ root ratio, esophageal stenosis, liver disease, urethral stenosis, osteoporosis, avascular necrosis of femur and/or humerus, premature hair graying/alopecia, or abnormal eyelashes

(Continues)

**TABLE 1** (Continued)

Group of dental anomaly/ name of disease	Phenotype MIM number	Orphanet number (ORPHA)	Inheritance	Gene/locus	Protein	Notes	Main manifestations
377 Dyskeratosis congenita, autosomal recessive 1	224230	1775	AR	NOP10	H/ACA ribonucleoprotein complex subunit 3		
378 Dyskeratosis congenita, autosomal dominant 1	127550	1775	AD	TERC	Non coding RNA		
379 Dyskeratosis congenita, autosomal dominant 2, autosomal recessive 4	613989	1775	AD, AR	TERT	Telomerase reverse transcriptase		
380 Ehlers-Danlos syndrome, periodontal	130080	75392	AD	C1R	Complement C1r subcomponent isoform 2		Joint hypermobility and skin abnormalities
381 Ehlers-Danlos syndrome, periodontal	617174	75392	AD	C1S	Complement C1s subcomponent isoform 2		Joint hypermobility and skin abnormalities
382 Haim-Munk syndrome	245010	2342	AR	CTSC	Cathepsin C		Palmoplantar keratoderma, severe early-onset periodontitis with early tooth loss, arachnodactyly, acroosteolysis, atrophic changes of the nails, radiographic deformity of the fingers, onychogryposis, pes planus, increased susceptibility to infections. Mutations in the same gene cause the clinically related disorder Papillon-Lefèvre syndrome.
383 Hermansky-Pudlak syndrome 2	608233	183678	AR	AP3B1	AP-3 complex subunit beta-1		Platelet defects and oculocutaneous albinism
384 Hypotrichosis, osteolysis, periodontitis-palmoplantar keratoderma syndrome	607658	307936	/	/	/		Hypotrichosis, striate palmoplantar keratoderma, onychogryphosis, acroosteolysis, psoriasis-like skin lesions
385 Kindler syndrome	173650	306539	AR	FERMT1	Fermitin family homolog 1 (kindlin1 gene)		Epidemolysis bullosa: congenital blistering, skin atrophy, photosensitivity, skin fragility, and scaling
386 Leukocyte adhesion deficiency type 1 (LAD1)	116920	99842	AR	ITGB2	Integrin beta 2 (CD18)		Congenital defect of phagocyte function: recurrent, life- threatening bacterial infections (skin, mouth, respiratory tract), delayed umbilical cord separation, severe periodontitis with early tooth loss, lack of pus formation and wound healing

(Continues)

TABLE 1 (Continued)

Group of dental anomaly/ name of disease	Phenotype MIM number	Orphanet number (ORPHA)	Inheritance	Gene/locus	Protein	Notes	Main manifestations
387 Leukocyte adhesion deficiency type 2 (congenital disorder of glycosylation type Iib, LAD2)	266265	99843	AR	SLC35C1	Solute carrier family 35, member C1 (GDP- fucose transporter 1)		Congenital defect of phagocyte function: mild LAD type 1 features with severe growth retardation, severe intellectual deficit, Bombay (hh) blood group, facial dysmorphism (depressed nasal bridge)
388 Leukocyte adhesion deficiency type 3 (LAD3)	612840	99844	AR	FERMT3	Fermitin family member 3		Congenital defect of phagocyte function: LAD type 1 phenotype with severe bleeding disorder
389 Severe congenital neutropenia type 1, autosomal dominant (SCN1)	202700	486	AD	ELANE	Neutrophil elastase		Congenital defects of phagocyte number: Severe congenital neutropenia, severe recurrent bacterial infections, increased risk of myelodysplastic syndrome and leukemia, severe periodontitis with early tooth loss, oral ulcers
390 Severe congenital neutropenia type 3, autosomal recessive (Kostmann syndrome, SCN3)	610738	99749	AR	HAX1	HCLS1-associated protein X1		Congenital defects of phagocyte number: Severe congenital neutropenia, severe recurrent bacterial infections, increased risk of myelodysplastic syndrome and leukemia, severe periodontitis with early tooth loss, oral ulcers, cognitive and neurological defects
391 Glycogen storage disease due to glucose-6-phosphatase deficiency type Ib	232220	79259	AR	SLC37A4	Glucose 6-phosphate translocase		Recurrent infections and neutropenia, higher prevalence of severe periodontitis
392 Neutropenia, chronic familial	162700	/	/	/	/		Severe congenital neutropenia
393 Chronic granulomatous disease	306400, 233700, 233690, 2333710, 613960	379	AR, XL	CYBA, CYBB, NCF1, NCF2, NCF4			Primary immunodeficiency, recurrent bacterial and fungal infections, development of granulomas
394 Plasminogen deficiency	217090	722	AR	PLG	Plasminogen		Impaired extracellular fibrinolysis, pseudomembranes on mucosae during wound healing
395 Cohen syndrome	216550	193	AR	VPS13B	Vacuolar protein sorting 13B		Microcephaly, characteristic facial features, hypotonia, non- progressive intellectual deficit, myopia and retinal dystrophy, neutropenia and truncal obesity

(Continues)

**TABLE 1** (Continued)

Group of dental anomaly/ name of disease	Phenotype MIM number	Orphanet number (ORPHA)	Inheritance	Gene/locus	Protein	Notes	Main manifestations
396 Chediak-Higashi syndrome	214500	167	AR	LYST	Lysosomal trafficking regulator		Disease of immune dysregulation: partial oculocutaneous albinism, severe immunodeficiency (recurrent bacterial infections), hemophagocytic lymphohistiocytosis, increased bleeding tendency, neurological dysfunction, lymphoproliferative disorder, <b>severe periodontal disease</b>
397 Hereditary angioedema	106100, 610618	91378		SERPINC1	C1 inhibitor		Subcutaneous or submucosal edemas
398 Pachyonychia congenita 1	167200	2309	AD	KRT16, KRT6A, KRT6B, KRT6C	Keratin 16 et 6		Hypertrophic nail dystrophy, painful and highly debilitating plantar keratoderma, oral leukokeratosis, epidermal cysts
399 Pachyonychia congenita 2	167210		AD	KRT17	Keratin 17		
400 Papillon-Lefevre syndrome	245000	678	AR	CTSC	Cathepsin C		Congenital defect of phagocyte function: ectodermal dysplasia with palmoplantar keratoderma, <b>severe early-onset periodontitis with early tooth loss</b> , increased susceptibility to cutaneous and systemic infections
<b>Tumor-like anomalies</b>							
401 Basal cell nevus syndrome	109400	377	AD	PTCH2	Protein patched homolog 2		Multiple nevoid basal-cell epitheliomas, jaw cysts, and bifid rib
402 Basal cell nevus syndrome	109400		AD	PTCH1	Protein patched homolog 1		
403 Basal cell nevus syndrome	109400		AD	SUFU	Suppressor of fused homolog		
404 Cherubism	118400	184	AD	SH3BP2	SH3 domain-binding protein 2		Multilocular cystic changes in the mandible and maxilla
405 Ercephalocraniocutaneous lipomatosis	613001	2396	IC	FGFR1, KRAS	Fibroblast growth factor receptor 1, GTPase Kras		Nevus psiloliparus, a well-demarcated, alopecic fatty tissue nevus on the scalp

(Continues)

TABLE 1 (Continued)

Group of dental anomaly/ name of disease	Phenotype MIM number	Orphanet number (ORPHA)	Inheritance	Gene/locus	Protein	Notes	Main manifestations
406 Hypomelanosis of Ito	300337	435	/	/	/		Skin lesions, eyes, musculoskeletal, central nervous systems anomalies
407 Lipomatosis, multiple	151900	199276	/	/	/		Numerous encapsulated lipomas on the trunk and extremities
408 Schwartz-Jampel syndrome, type 1	255800	800	AR	HSPG2	Basement membrane-specific heparan sulfate proteoglycan core protein		Short stature, myotonic myopathy, dystrophy of epiphyseal cartilages, joint contractures, blepharophimosis, unusual pinnae, myopia, pigeon breast

## 2.2 | Nosology of genetic dental disorders

The oral rare disease expert group established a classification of dental disorders based on personal clinical observations collected across the national network and literature data. OMIM, Orphanet, and PubMed (Canese & Weis, 2002) were searched up to December 2018. The PubMed search was performed using as search terms: “dental agenesis,” “supernumerary tooth,” “microdontia,” “macrodontia,” “enamel dysplasia,” “dentin dysplasia,” “dental eruption anomaly,” “gingival overgrowth,” “periodontal disease,” and “dental disorder.” Only English-language publications were accepted. Developmental defects were recorded and grouped in eight clusters of dental disorders (dental agenesis, supernumerary teeth, morphology dental anomaly [size and shape], enamel anomaly, dentin anomaly, anomaly of dental eruption, periodontal and gingival anomalies, and tumor-like disorders). In each group, pathologies were subdivided into “isolated” or “syndromic.” Syndromes were classified by their main clinical medical features (skin, eye, bone, endocrine organs, kidneys, cranio-facial, cancer, and intellectual disability). If dental anomalies were insufficiently described in OMIM, original articles were analyzed. The classification includes the name of the pathology, OMIM codes, Orpha numbers, gene(s) involved, protein(s), and the other main medical manifestations (Table 1). Notes were added if complementary information was needed. If OMIM and/or Orphanet number was not available, essential references were added.

The criteria for including a disorder were:

1. The presence of dental anomalies (Supplementary Data Table S1)
2. Published in a peer-reviewed journal, in one or more of three dedicated textbooks (Bloch-Zupan et al., 2012; Hall, 1994; Hennekam et al., 2010) and/or listed in OMIM and/or Orphanet database; unpublished observations were not included.
3. Either a proven molecular genetic basis (variants; linkage analyses) or internationally accepted clinical entities due to distinctive clinical manifestations observed in multiple individuals.

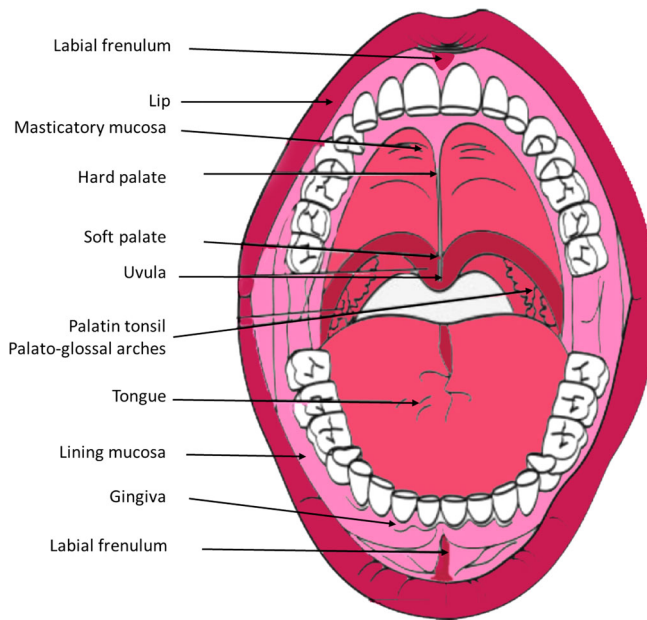
## 3 | RESULTS

### 3.1 | Defining dental anomalies

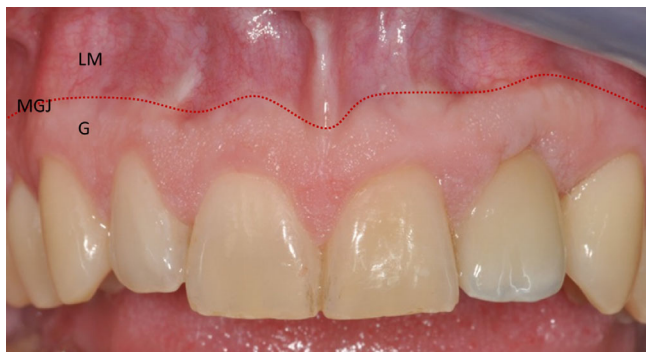#### 3.1.1 | Anatomy of teeth and oral mucosa

##### General

The oral region includes the maxillae, the mandible, muscles, glands, and other structures related to the oral functions. The oral cavity belongs to the oral region and is the space bounded superiorly by the palate, laterally by the cheeks, anteriorly by the lips, inferiorly by the floor of the mouth, and posteriorly limited by the uvula and the palato-glossal arches and communicates with the oropharynx. The oral cavity contains oral mucosa, tongue, teeth, periodontium, and alveolar processes surrounding dental roots (Figure 1).



**FIGURE 1** The oral cavity and its mean structures (modified from Carey et al., 2009) [Color figure can be viewed at [wileyonlinelibrary.com](http://wileyonlinelibrary.com)]



**FIGURE 2** The normal oral mucosa around teeth (G gingiva, LM lining mucosa, MGJ mucogingival junction) [Color figure can be viewed at [wileyonlinelibrary.com](http://wileyonlinelibrary.com)]

### Anatomy

**Oral Mucosa.** The oral mucosa has been defined before as epithelium covering the inner aspect of the oral cavity (Carey et al., 2009). This refers only to the lining epithelium. The oral mucosa is composed of two layers: the epithelium and associated connective tissue, separated by a basal membrane. There are three types of oral mucosa: lining, masticatory, and specialized. Lining mucosa covers the oral cavity except for the dorsal surface of the tongue, hard palate, and teeth bearing area (namely gingiva). The epithelium is non-keratinized, and its connective tissue is not tightly bound but quite mobile. Lining mucosa is separated from gingiva by the mucogingival junction (Figure 2). Masticatory mucosa comprises gingiva and covers hard palate, its epithelium is keratinized, and the connective tissue is strongly linked to underlying structures, mainly bone. The dorsal surface of the tongue is covered by a specialized mucosa, which contains papillae (filiform, fungiform, and circumvallate) and taste buds.

**Tooth.** Teeth are organs usually attached in a row to each jaw and include various hard and soft tissues (enamel, dentin, pulp, and cementum) (Figure 3) (Nanci, 2012). Their anatomical overall shape is adapted to their functions. Anatomically, teeth can be divided into the crown and the root by the cervical margin. The crown is the part of the tooth that is visible in the oral cavity. The root is surrounded by the periodontium. The dentin pulp complex constitutes the main structure of the tooth, covered by enamel in the crown and cementum in the root.

**Dentition.** Humans have two dentitions: a deciduous (primary) dentition and a permanent (secondary) dentition, which replaces the former one. The shape and position of teeth follow a specific pattern. Deciduous dentition accounts for 20 teeth (two incisors, one canine, and two molars per quadrant), whereas permanent dentition accounts for 32 teeth (two incisors, one canine, two premolars, three molars per quadrant). The first teeth erupt at around 6 months of age and the last one at around 18 years old. Dental development, patterning, and eruption timing and sequence have been described in detail elsewhere (Lunt & Law, 1974; McDonald, Avery, & Dean, 2004).

A numeration system designs human deciduous and permanent teeth according to their type and location following the FDI two digits ("FDI Director calls on more countries to adopt the FDI two-digit tooth-numbering system," 1988) and ISO 3950:2016 (Dentistry - Designation system for teeth and areas of the oral cavity) recommendations (Figure 4).

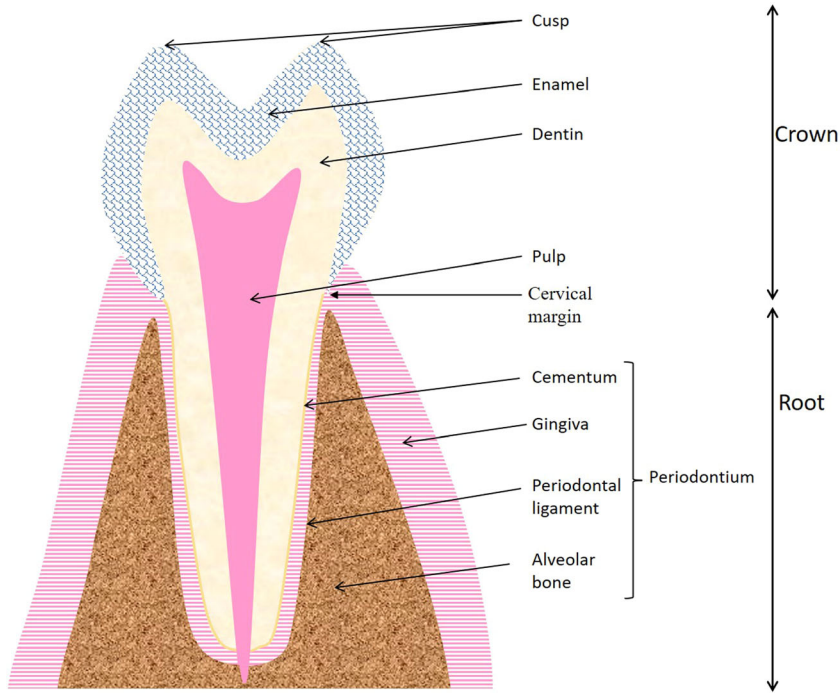
**Incisor.** Teeth located in the anterior part of the arches of maxilla and mandible. The typical crown shape is approximately rectangular. They have a single root. Two incisors (one central and one lateral from the midline) exist per quadrant (Figure 4).

**Canine.** Teeth located between the incisors and the molars in deciduous teeth and between the incisors and the premolars in permanent teeth. The typical crown shape is pointed. They have a single root. One canine exists per quadrant (Figure 4).

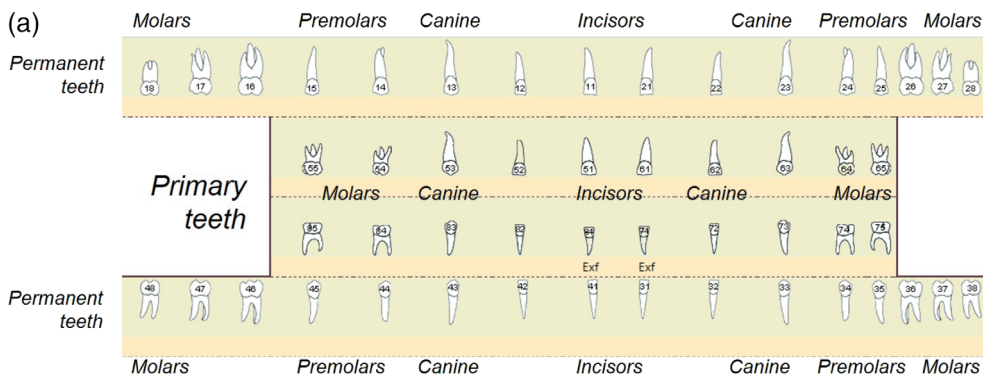
**Premolar.** Teeth located between the canines and the molars in the permanent dentition. Two premolars exist per quadrant. The occlusal surface of the crown is composed of two cusps (one labial and one lingual). They have one or two roots (Figure 4).

**Molar.** Teeth located in the posterior part of the dental arches of maxilla and mandible. In the deciduous dentition, two molars exist which will be replaced by premolars. In the permanent dentition, three molars exist appearing at around 6 years of age for the first permanent molars, 12 years of age for the second permanent molars and at adulthood for the third permanent molars (or wisdom teeth). The typical shape is with multiple cusps and multiple roots. Maxillary molars have two vestibular cusps and one lingual cusp. Mandibular molars have three vestibular cusps and two lingual cusps (Figure 4). Maxillary molars have three roots, two vestibular, and one palatal. Mandibular molars have two roots, one mesial, and one distal. Their shape and size may vary according to sex, ethnicity, and geography.





**FIGURE 3** Major anatomical landmarks of the teeth (see text) [Color figure can be viewed at wileyonlinelibrary.com]



(b)

Arch	Tooth	Sexe	-2 SD	MD diameter	+2 SD	SD
Maxilla	Central Incisor	M	7,89	<b>8,79</b>	9,69	0,45
		F	7,72	<b>8,54</b>	9,36	0,41
	Lateral Incisor	M	5,2	<b>6,32</b>	7,44	0,56
		F	5,85	<b>6,21</b>	6,57	0,18
	Canine	M	6,77	<b>7,53</b>	8,29	0,38
		F	6,17	<b>7,35</b>	8,53	0,59
	First Premolar	M	6,14	<b>6,78</b>	7,42	0,32
		F	5,65	<b>6,59</b>	7,53	0,47
	Second Premolar	M	5,56	<b>6,54</b>	7,52	0,49
		F	5,43	<b>6,41</b>	7,39	0,49
First Molar	M	9,81	<b>10,69</b>	11,57	0,44	
	F	9,6	<b>10,64</b>	11,68	0,52	
Second Molar	M	9,06	<b>9,6</b>	10,14	0,27	
	F	8,8	<b>9,4</b>	9,9	0,27	
Mandible	Central Incisor	M	4,96	<b>5,58</b>	6,2	0,31
		F	4,6	<b>5,56</b>	6,52	0,48
	Lateral Incisor	M	5,32	<b>6,2</b>	7,08	0,44
		F	5,55	<b>6,17</b>	6,79	0,31
	Canine	M	6,2	<b>6,96</b>	7,72	0,38
		F	6,17	<b>6,91</b>	7,65	0,37
	First Premolar	M	5,69	<b>6,79</b>	7,89	0,55
		F	5,93	<b>6,77</b>	7,61	0,42
	Second Premolar	M	5,85	<b>6,81</b>	7,77	0,48
		F	5,86	<b>6,78</b>	7,7	0,46
First Molar	M	10,04	<b>11,36</b>	12,68	0,66	
	F	10,43	<b>11,21</b>	11,99	0,39	
Second Molar	M	9,12	<b>9,5</b>	9,88	0,19	
	F	8,9	<b>9,3</b>	9,6	0,19	

**FIGURE 4** (a) Teeth in the dental arches, th odontogram is from D[4]/phenodent database. (b) This table represents the normal mesiodistal and standard deviation (M=Male; F= Female) [Color figure can be viewed at wileyonlinelibrary.com]



**Enamel.** Hard acellular structure covering tooth crown. Enamel is the most mineralized material (98%) in the human body, secreted by ameloblasts. Ameloblasts disappear as the tooth erupts within the oral cavity. Enamel is able to neither regenerate nor repair. Enamel is translucent and appears to have a color that varies from white to light yellow depending of the color of the dentin. The surface is smooth and glossy (Figure 3).

**Dentin.** Dentin is a mineralized connective tissue forming the dental crown and root. Dentin is a vital tissue, less mineralized than enamel, and has the capacity to repair. Odontoblasts are the dentin forming cells and are located in the dental pulp periphery just below dentin. Odontoblasts extend a long cytoplasmic process radially from the pulp to the dentino-enamel and dentino-cemental junctions inside canaliculi; these are called dentin tubuli (Figure 3).

**Dental pulp.** Soft connective tissue occupying the inner portion of the tooth, both in the crown (pulp chambers) and the root canals covered by dentin. The dental pulp consists of fibroblasts, odontoblasts, undifferentiated ectomesenchymal cells, macrophages and other immunocompetent cells, blood vessels, and nervous fibers (Figure 3).

**Cementum.** Mineralized connective tissue covering the dental root. The cementum allows anchoring of the fibers of the periodontal ligament. Cementum is secreted by cementoblasts, which may be, later on, embedded in the cementum. Cementum can be acellular (along the two third coronal portion of the root) and cellular (in the apical and interradicular part of the root) (Figure 3).

**Cusp.** Eminence of the occlusal surface of a tooth. Canines possess a single cusp, premolars two (bicuspid), and molars three to five cusps (Figures 3 and 4).

**Mamelons.** Small tubercles on the incisal edge when the incisors erupt. Mamelons typically disappear or decrease in size as they get worn away by mastication (Figure 5).

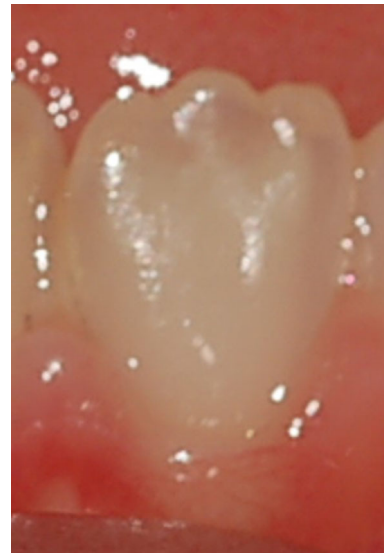**Periodontium.** The periodontium encompasses the cementum, periodontal ligament, alveolar bone, and gingiva (Figure 3).

**Periodontal ligament.** Connective tissue attaching the tooth root to the alveolar bone of the maxillae or mandible (Figure 3).

**Gingiva.** Gingiva or gum is the part of the oral mucosa covering the teeth bearing area of the jaw (alveolar processes). Attached gingiva, free gingiva, and marginal gingiva (Figure 1).

#### Measurements of the teeth

Measure of teeth was reported giving mean value for mesiodistal diameters, labio- or bucco-lingual diameter, length of root, and length of crown. The size of tooth varies across ethnic groups (Black, 1890; Lavelle, 1972) (Figure 4).



**FIGURE 5** Normal mamelons in a mandibular incisor [Color figure can be viewed at [wileyonlinelibrary.com](http://wileyonlinelibrary.com)]

## 4 | DEFINITIONS

### 4.1 | Tooth, anomaly

#### 4.1.1 | Definition

Alteration in the number, shape, size, or structure, in the chronology of eruption or the alignment in the dental arch, of a single tooth or multiple teeth. *Objective or subjective.*

#### 4.1.2 | Comments

An anomaly can be explained as a malformation, a dysplasia, a deformation or disruption, and classifying a dental anomaly as such helps in understanding etiology and pathogenesis (Hennekam et al., 2013). Teeth anomalies can affect the tooth crown, tooth root, or both. For root anomalies, diagnosis requires typically radiographic examinations as well.

**Replaces:** Dental defect

**Synonym:** Dental anomaly

Dental anomaly: see **Tooth, anomaly**.

### 4.2 | Tooth, missing

#### 4.2.1 | Definition

Apparent absence of one or more teeth during the visual inspection of the oral cavity. *Objective.*

#### 4.2.2 | Comment

The tooth may appear to be absent due to a disturbed eruption, failure to develop, or loss of teeth. Age-related physiological sequential eruption should be taken into account during evaluations.

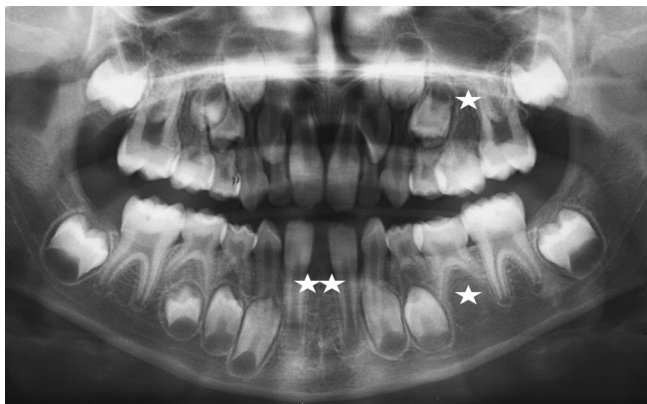**Synonym:** Tooth, reduced number

Tooth, reduced number: see **Tooth, missing**.

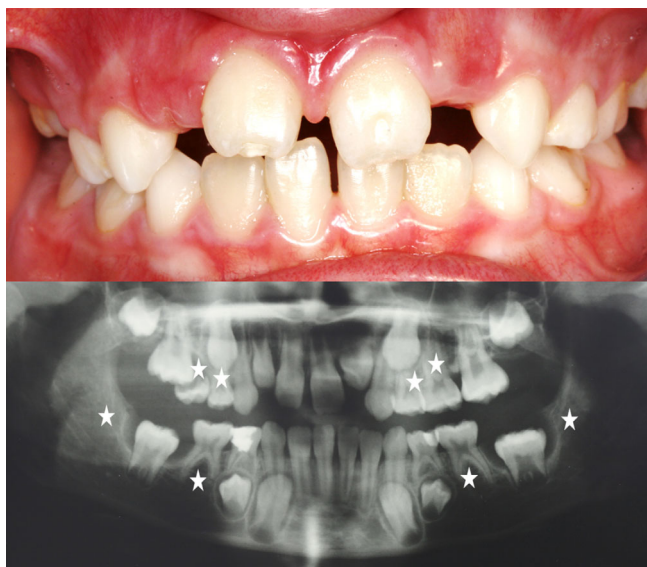### 4.3 | Teeth, agenesis

#### 4.3.1 | Definition

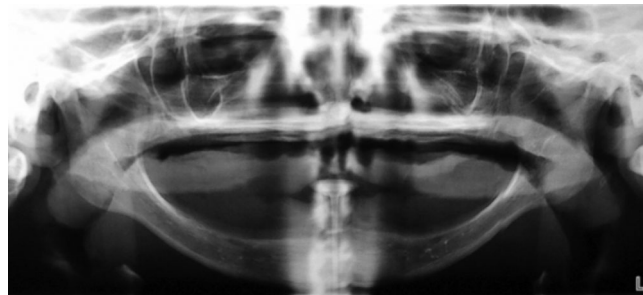
The absence of one or more teeth from the normal series by a failure to develop (Figures 6–8). *Objective*.



**FIGURE 6** Hypodontia—panoramic radiography of a 7 years old child showing four dental agenesis (see the stars second left maxillary premolar, mandibular central incisors, mandibular second left premolar). Deciduous and permanent molars are taurodont. Maxillary central incisor presents a screwdriver shape anomaly



**FIGURE 7** Oligodontia—patient with oligodontia (missing 12 permanent teeth see the stars: maxillary first and second premolars, mandibular second premolars, second molars, and four wisdom teeth). Abnormalities of tooth shape and tooth structure (enamel hypoplasia) are also seen on upper permanent central incisors [Color figure can be viewed at [wileyonlinelibrary.com](http://wileyonlinelibrary.com)]



**FIGURE 8** Anodontia—complete absence of all deciduous and permanent teeth in an ectodermal dysplasia patient showing severe decrease of alveolar bone

#### 4.3.2 | Comments

Teeth agenesis needs to be confirmed by X-rays. Teeth agenesis encompasses **hypodontia**, **oligodontia**, and **anodontia**. The total number and the type of teeth missing should be added to the description, using the FDI nomenclature. The clinical absence of a tooth due to a disturbed eruption should not be termed teeth agenesis but a **missing tooth**.

**Synonym:** Dental agenesis

Dental agenesis: see **Teeth, agenesis**.

### 4.4 | Hypodontia

#### 4.4.1 | Definition

The absence of five or less teeth from the normal series by a failure to develop (Figure 6). *Objective*.

#### 4.4.2 | Comments

Hypodontia needs to be confirmed by X-rays. The total number and the type of missing teeth should be added to the description, using the FDI nomenclature (“FDI Director calls on more countries to adopt the FDI two-digit tooth-numbering system,” 1988; Peck & Peck, 1993). The terms **hypodontia** and **oligodontia** have been used interchangeably in literature but these define two different clinical entities. Hypodontia has been used to define exclusively the absence of permanent teeth and excluding third molars, but the absence of any deciduous and permanent teeth, including third molars, should be called hypodontia as well. Hypodontia in the permanent dentition (other than third molars) affects 2–8% of the general population (Polder, Van't Hof, Van der Linden, & Kuijpers-Jagtman, 2004). The permanent dentition is more often concerned but when it affects the deciduous dentition, the permanent dentition is usually also affected (Polder et al., 2004). Third molars agenesis occurs in up to 10–30% within the general population. Hypodontia of a permanent tooth is often associated with persistence of the deciduous predecessor and may be associated with other dental anomalies such as **delayed eruption**, **infraocclusion** of deciduous molars (if premolars are involved), **microdontia**, ectopic tooth eruption, **short roots**, **taurodontism**, tooth

rotation, or **enamel hypocalcification**. These signs should be assessed and coded separately. The clinical absence of a tooth due to a disturbed eruption should not be termed teeth agenesis but a **missing tooth**.

## 4.5 | Oligodontia

### 4.5.1 | Definition

The absence of six or more teeth from the normal series by a failure to develop. (Figure 7). *Objective*.

### 4.5.2 | Comments

Oligodontia needs to be confirmed by X-rays. The number and the type of teeth missing should be added to the description using the FDI nomenclature (Peck & Peck, 1993) ("FDI Director calls on more countries to adopt the FDI two-digit tooth-numbering system," 1988). The terms **oligodontia** and **hypodontia** have been used interchangeably in literature, but these define two different clinical entities if considering the number of missing teeth. Maxillary lateral incisor and second premolar are more commonly part of oligodontia (Fournier et al., 2018), maxillary second premolars, mandibular incisor, and maxillary and mandibular first premolars, and second molars are less frequently absent. Canines, maxillary central incisor, and first molars are the more conserved teeth. Agenesis of a permanent tooth is often associated with persistence of the deciduous predecessor and may be associated with other dental anomalies such as **delayed eruption**, **infraocclusion** of deciduous molars (if premolars are involved), **microdontia**, ectopic teeth, **short roots**, **taurodontism**, tooth rotation, or **enamel hypocalcification**. These signs should be assessed and coded separately. Isolated oligodontia affects 0.1% of the population (Polder et al., 2004). The clinical absence of a tooth due to a disturbed eruption should not be termed teeth agenesis but a **missing tooth**.

## 4.6 | Anodontia

### 4.6.1 | Definition

The absence of all teeth from the normal series by a failure to develop. (Figure 8). *Objective*.

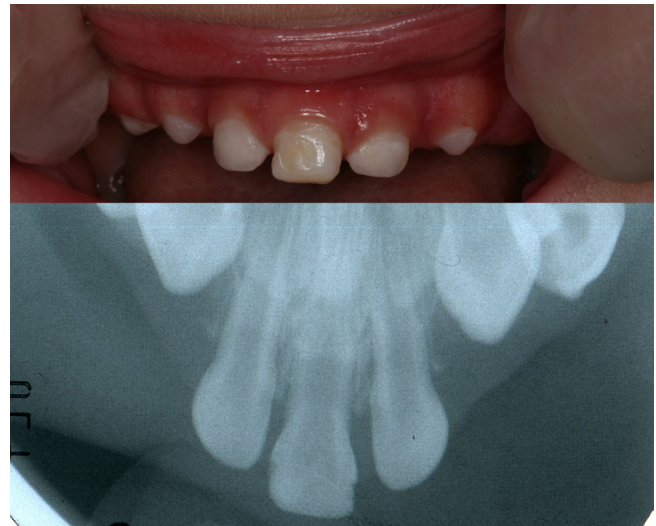
### 4.6.2 | Comments

Anodontia needs to be confirmed by X-rays. True anodontia is an extremely rare condition.

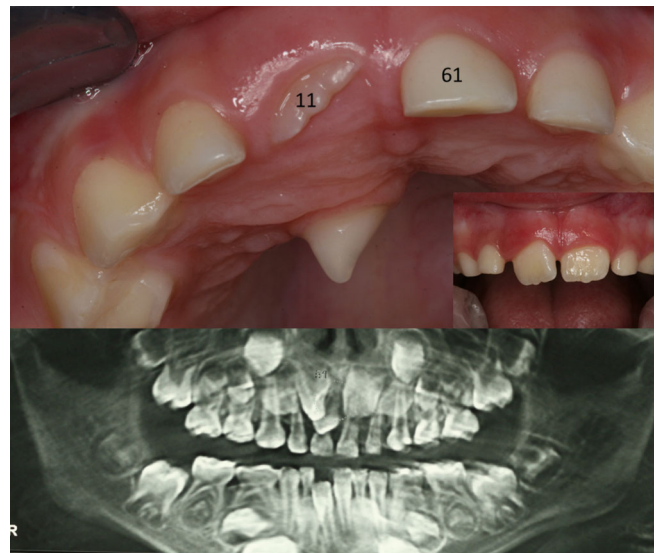
## 4.7 | Solitary median maxillary central incisor

### 4.7.1 | Definition

A single maxillary central incisor positioned in the midline with morphological symmetry of the crown and bordered by lateral incisors (Figure 9). *Objective*.



**FIGURE 9** Solitary median maxillary central incisor: clinical aspect and radiograph [Color figure can be viewed at [wileyonlinelibrary.com](http://wileyonlinelibrary.com)]



**FIGURE 10** Mesiodens—a palatally erupted mesiodens between the upper central incisors (11 upper central right permanent and 61 upper central left deciduous incisors). After avulsion of the supernumerary tooth, the two permanent upper central incisors come in the right position [Color figure can be viewed at [wileyonlinelibrary.com](http://wileyonlinelibrary.com)]

### 4.7.2 | Comments

The tooth differs from a normal central incisor in the symmetric formation of the crown. The tooth is present in both deciduous and permanent dentition. Solitary/single median maxillary central incisor syndrome (SMMCI) indicates the presence of a single median maxillary central incisor together with other midline defects of development (Hall, 2006). A single maxillary central incisor not positioned in the midline indicates agenesis of the contralateral central incisor and can be differentiated furthermore by the morphology of the crown. A diagnosis of a solitary median maxillary central incisor typically requires X-rays examinations.



Hyperdontia: see *Tooth, supernumerary*.

## 4.8 | Mesiodens

### 4.8.1 | Definition

A supernumerary tooth between the maxillary central incisors (Figure 10). *Objective*.

### 4.8.2 | Comments

Mesiodens is the most common supernumerary tooth. Typically, they are small. They are usually conical in shape but may have heterogeneous forms. Mesiodens may remain unerupted and cause failure of a permanent incisor to erupt. Mesiodens may develop in an inverted position (flipped 180°).

Tooth, extra: see *Tooth, supernumerary*.

Tooth, increased number: see *Tooth, supernumerary*.

## 4.9 | Tooth, supernumerary

### 4.9.1 | Definition

The presence of one or more teeth additional to the normal number (Figure 11). *Objective*.

### 4.9.2 | Comments

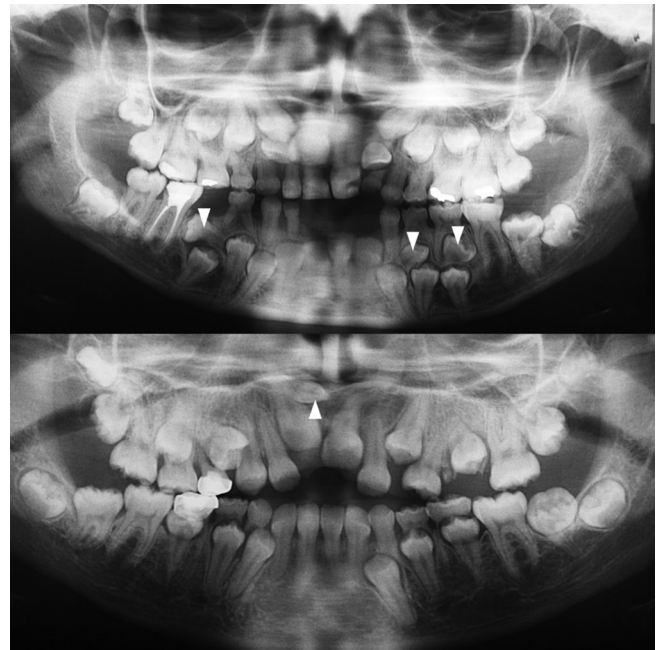
Age-related physiological sequential eruption should be taken into account during evaluation. The type and the location of the additional tooth/teeth should be added to the description. Supernumerary teeth are uncommon (in 0.21% of deciduous dentitions and in 0.9% of permanent dentitions) (Lagana et al., 2017), and often abnormal positioning of a normal number of teeth is wrongly classified as supernumerary teeth. Supernumerary teeth are most frequent in the upper maxilla, and typically, a single additional tooth is present. We discourage the use of distodens, distomolars (an extra fourth molar posterior to the third molar), paramolars (supernumerary tooth in the molar region) but rather to mention the presence of the supernumerary tooth mesial to or distal to a tooth from the normal series. Diagnosing a supernumerary tooth may require radiographic examination. A supernumerary tooth present between the maxillary central incisors is called *mesiodens*.

**Synonym:** Tooth, extra teeth; Hyperdontia; Tooth, increased number

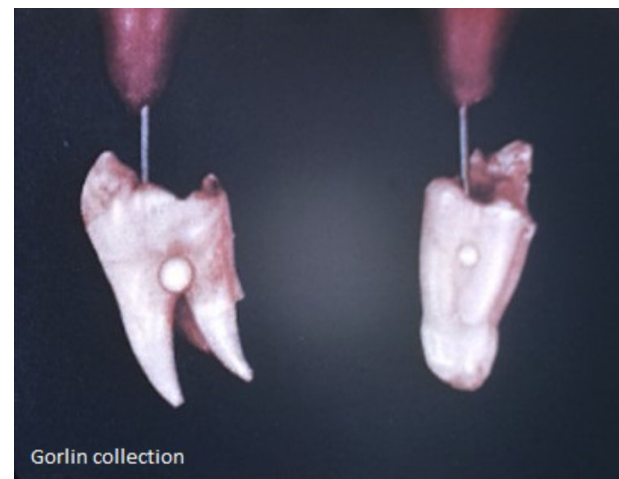## 4.10 | Enamel, pearls

### 4.10.1 | Definition

Small nodules of enamel on the root of a tooth (Figure 12). *Subjective*.



**FIGURE 11** Supernumerary teeth (arrow head) in sisters (upper panel multiple mandibular premolars are visible on the panoramic radiograph; lower panel the supernumerary tooth is seen in the upper incisor area)



**FIGURE 12** Enamel pearls [Color figure can be viewed at [wileyonlinelibrary.com](http://wileyonlinelibrary.com)]

### 4.10.2 | Comments

Enamel pearls can typically not be seen on X-rays but need direct visualization. The pearls can be present on the surface of the dentine or cement of deciduous teeth, with a frequency of 33% (Arys & Dourov, 1987) or on the roots of maxillary molars, with a frequency of 1.2% (Chrcanovic, Abreu, & Custodio, 2010).

## 4.11 | Cusps, supernumerary

### 4.11.1 | Definition

Additional cusps of a dental crown. (Figure 13). *Objective*.

### 4.11.2 | Comments

Supernumerary cusps can occur on any tooth with cusps. They are frequently seen in patients with other dental anomalies (Herrera-Atoche et al., 2017). Prevalence varies by geographical region (Yamunadevi et al., 2015). A tubercle on the lingual surface of the maxillary first permanent molar is sometimes referred to as a Carabelli cusp (Carabelli, 1844) (Poornima, Kirthiga, Sasalwad, & Nagaveni, 2016; Tinoco, Lima, Delwing, Franceschini Jr., & Daruge Jr., 2016). A supernumerary cusp on the lingual or palatal side of anterior teeth is called *Talon cusp*, and an additional cusp on the occlusal surface of a premolar is called *Leung cusp*.

**Replaces term:** Tuberculum paramolare

**Synonym:** Cusp, extra; Cusp, additional cusp; Mulberry molar  
Cingulum, prominent: see *Talon cusp*.

Cusp, additional: see *Cusp, supernumerary*.

Cusp, extra: see *Cusp, supernumerary*.

Dens evaginatus: see *Leung cusp*.

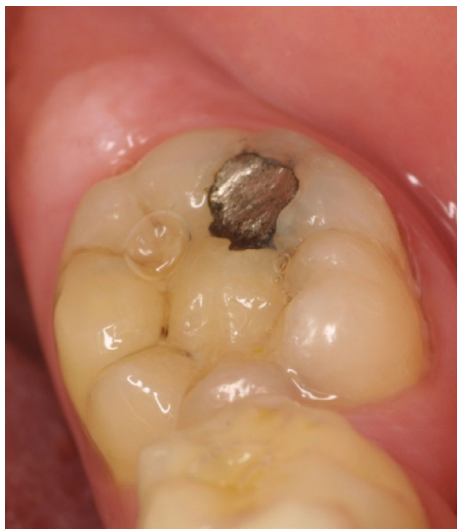Dens evaginatus: see *Talon cusp*.

Eagle talon: see *Talon cusp*.

## 4.12 | Leung cusp

### 4.12.1 | Definition

An additional cusp located in the middle of the occlusal surface. *Objective*.



**FIGURE 13** Supernumerary cusps—additional cusps or mulberry permanent mandibular [Color figure can be viewed at [wileyonlinelibrary.com](http://wileyonlinelibrary.com)]

### 4.12.2 | Comments

A Leung cusp is present on premolars only. In X-rays examination, a pulp extension may be seen inside the cusp.

**Synonym:** Dens evaginatus

Mulberry molar: see *Cusps, supernumerary*.

## 4.13 | Tooth, natal

### 4.13.1 | Definition

A tooth present at birth or erupting within the first month of life (Figure 14). *Objective*.

### 4.13.2 | Comments

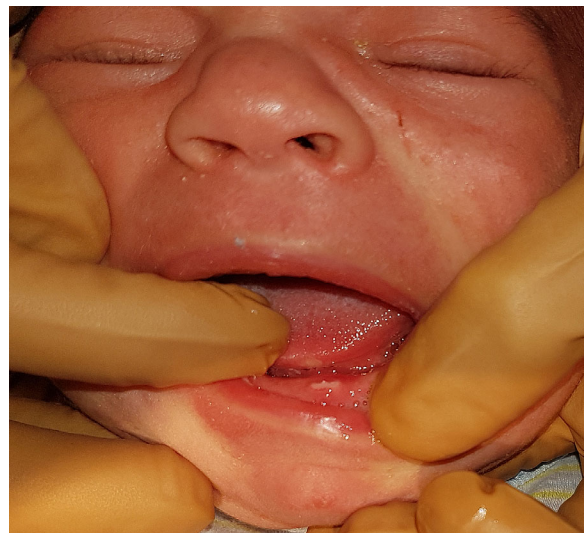A tooth erupting between the second and fourth month is called a neonatal tooth. A natal tooth is uncommon, the prevalence at birth is 1/2000 to 1/3500 birth. In 85%, the erupted tooth is the deciduous lower incisors, and in 5%, it concerns upper incisors or molars, and in 10%, it involves supernumerary teeth (Mhaske et al., 2013). Natal teeth are particularly common among some native (First Nation) groups of North America (Carey et al., 2009). Natal teeth are usually mobile and lack root formation.

## 4.14 | Microdontia

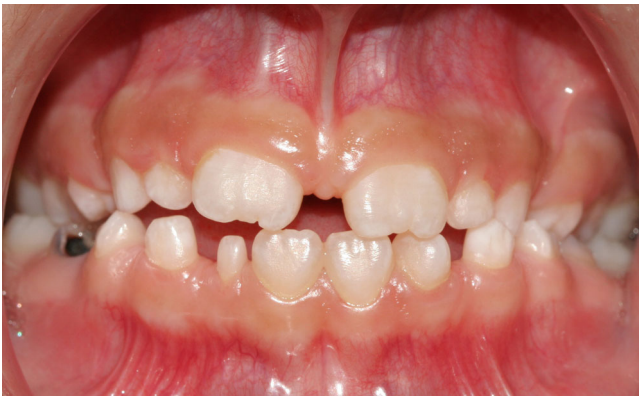### 4.14.1 | Definition

Mesiodistal tooth diameter (width) more than 2 SD below mean. *Objective*.

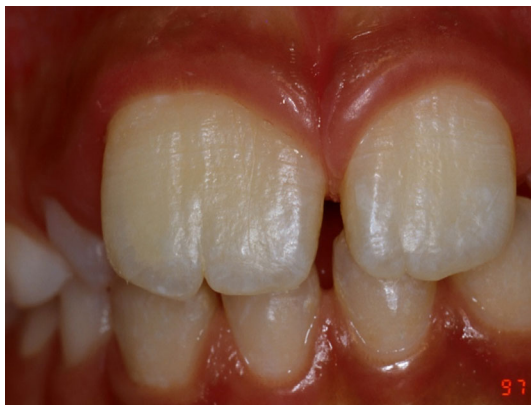OR apparently decreased maximum width of tooth (Figure 15). *Subjective*.



**FIGURE 14** Natal tooth in a newborn [Color figure can be viewed at [wileyonlinelibrary.com](http://wileyonlinelibrary.com)]



**FIGURE 15** Microdontia—intraoral photograph of generalized microdontia of permanent teeth and especially of the deciduous mandibular lateral incisor [Color figure can be viewed at [wileyonlinelibrary.com](http://wileyonlinelibrary.com)]



**FIGURE 16** Macrodontia—large upper right central incisor (double teeth due to fusion in the permanent dentition between the central and the lateral incisor). The right maxillary central incisor presents also a notch of the incisal edge [Color figure can be viewed at [wileyonlinelibrary.com](http://wileyonlinelibrary.com)]

#### 4.14.2 | Comments

Standard references for means and standard deviations by gender are available (Figure 4) (Black, 1890; Lavelle, 1972). Microdontia may affect a single tooth or the entire dentition, which is indicated as localized or generalized microdontia. The most common tooth involved is the lateral incisor. Microdontia goes often along with *hypodontia* and *oligodontia*, which should then be assessed and scored separately. Microdontia is typically genetically determined but environmental factors may be also implicated (Jeong, Kim, Song, Sung, & Kim, 2015).

**Replaces term:** Microdont; Tooth hypoplasia; Tooth hypotrophy

**Synonym:** Tooth, small; Tooth, underdeveloped

### 4.15 | Macrodonia

#### 4.15.1 | Definition

Mesiodistal tooth diameter (width) more than 2 SD above mean.  
*Objective.*

OR apparently increased maximum width of the tooth (Figure 16).  
*Subjective.*

#### 4.15.2 | Comments

The standard reference for means and standard deviations by gender is available (Figure 4) (Black, 1890; Lavelle, 1972). Macrodonia is uncommon, may affect a single or multiple teeth, and is rarely present in all teeth. A large tooth may also result from fusion of two teeth (*Double teeth*).

**Replaces term:** Megadont; Macrodon; Tooth hyperplasia; Tooth hypertrophy

**Synonym:** Tooth, large; Megalodontia; Globodontia

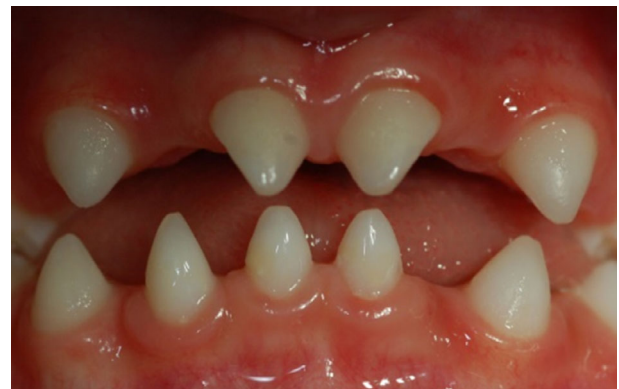Tooth, large: see *Macrodonia*.

Megalodontia: see *Macrodonia*.

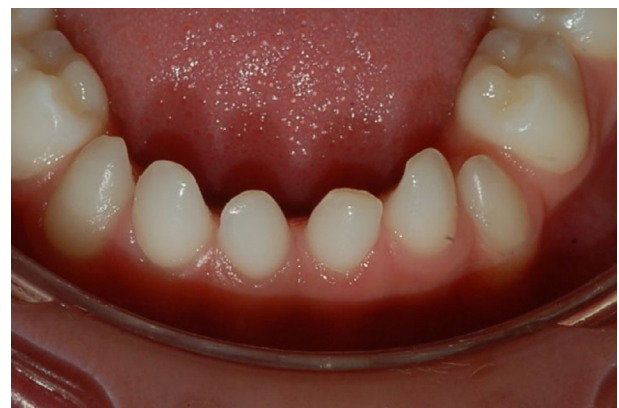### 4.16 | Tooth, conical

#### 4.16.1 | Definition

A tooth with a sharply pointed crown or incisal edge (Figure 17).  
*Subjective.*

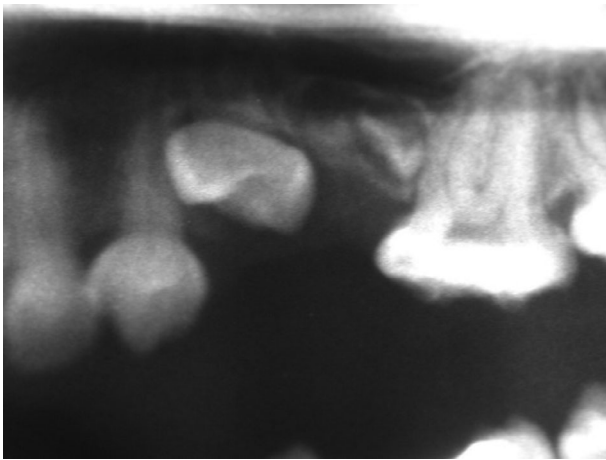

**FIGURE 17** Conical teeth [Color figure can be viewed at [wileyonlinelibrary.com](http://wileyonlinelibrary.com)]

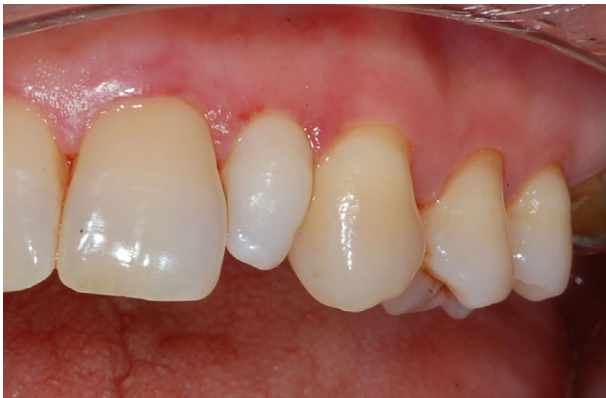

**FIGURE 18** Barrel shaped mandibular incisors [Color figure can be viewed at [wileyonlinelibrary.com](http://wileyonlinelibrary.com)]





**FIGURE 19** Bulbous crown in dentinogenesis imperfecta affecting teeth



**FIGURE 20** Peg-shaped maxillary lateral incisor [Color figure can be viewed at [wileyonlinelibrary.com](http://wileyonlinelibrary.com)]

#### 4.16.2 | Comments

A conical shape of a tooth occurs in incisors and canines only. Conical teeth may occur isolated or associated with other dental anomalies, such as *hypodontia* and *oligodontia* (Tallon-Walton et al., 2010); this should be assessed and coded separately.

**Replaces term:** Pointed teeth

**Synonym:** Conoid teeth

Tooth, conoid: see **Tooth, conical**.

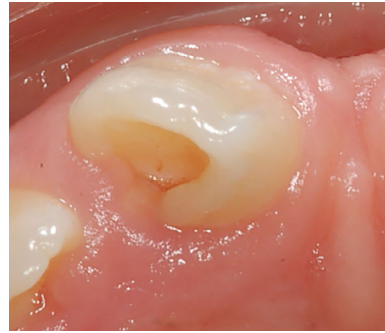
#### 4.17 | Tooth, barrel-shaped

##### 4.17.1 | Definition

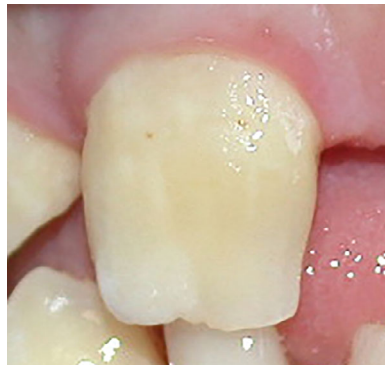A tooth crown with convex mesial and distal surfaces (Figure 18). *Subjective*.

##### 4.17.2 | Comments

A barrel shape of a tooth occurs in incisors and canines only. The incisal edge is not pointed. Barrel-shaped teeth are frequently observed



**FIGURE 21** Shovel-shaped maxillary central incisor [Color figure can be viewed at [wileyonlinelibrary.com](http://wileyonlinelibrary.com)]



**FIGURE 22** Tapered maxillary central incisor [Color figure can be viewed at [wileyonlinelibrary.com](http://wileyonlinelibrary.com)]

in association with *hypodontia* and *oligodontia* (Kantaputra, Kaewgahya, Jotikasthira, & Kantaputra, 2014); this should be assessed and coded separately.

#### 4.18 | Tooth, bulbous

##### 4.18.1 | Definition

A tooth crown with a marked cervical area constriction. *Subjective*.

##### 4.18.2 | Comments

It is mostly seen in molars (Figure 19). The diagnosis bulbous crown needs to be confirmed by X-rays.

#### 4.19 | Tooth, peg-shaped

##### 4.19.1 | Definition

A tooth crown with its mesial and distal sides converging or tapering toward the incisal edge causing severe reduction of mesiodistal diameter (Figure 20). *Subjective*.

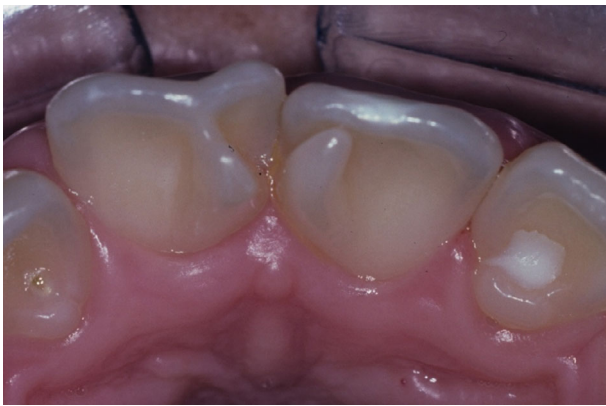#### 4.19.2 | Comments

A peg shape appearance of a tooth occurs in lateral incisors only (Bot & Salmon, 1977). A peg-shaped tooth is a *microdont* tooth and may occur isolated or associated with other dental anomalies, such as *hypodontia* and *oligodontia* (Reston et al., 2014; Tallon-Walton et al., 2014); this should be assessed and coded separately.

### 4.20 | Tooth, shovel

#### 4.20.1 | Definition

A tooth with a crown with marked lingual or palatal marginal ridges causing scooped lingual or palatal surfaces (Figure 21). *Subjective*.



**FIGURE 23** Talon cusps on both central incisor and invagination at the cingulum site on lateral incisors [Color figure can be viewed at wileyonlinelibrary.com]

#### 4.20.2 | Comments

A shovel shape typically occurs in central upper incisors. Shovel-shaped teeth may occur isolated or associated with other dental anomalies.

### 4.21 | Tooth, tapered

#### 4.21.1 | Definition

A tooth with a crown that narrows from proximal toward the incisal edge (Figure 22). *Subjective*.

#### 4.21.2 | Comments

Tapering of teeth typically involves incisors (Axelsson, 2005).

**Synonym:** Tooth, screwdriver-shaped

### 4.22 | Talon cusp

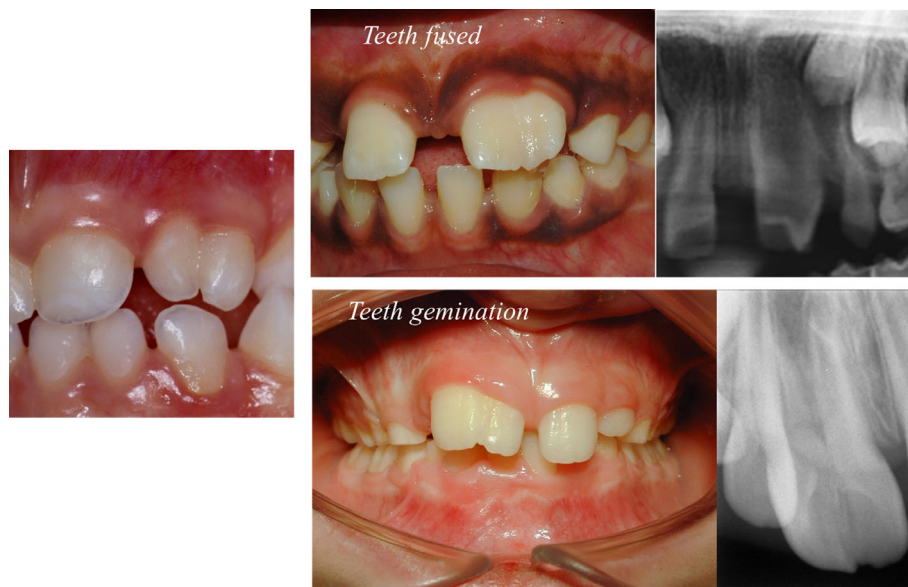
#### 4.22.1 | Definition

A supernumerary cusp on the palatal or lingual side of the maxillary and mandibular anterior teeth (Figure 23). *Subjective*.

#### 4.22.2 | Comments

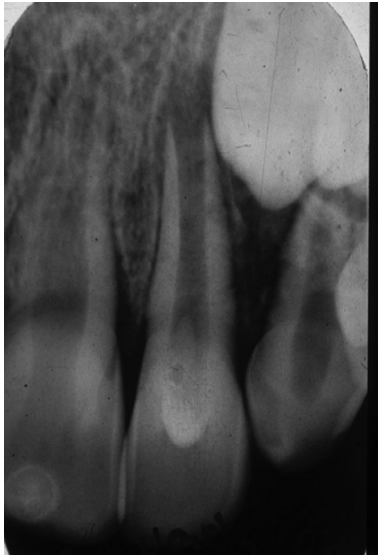A talon cusp is found in 1% to 6% of the general population with a large difference in incidence depending on ethnicity. It is uncertain whether it arises as an extra cusp or also as an overdevelopment of an existing cusp. It is rare in the deciduous dentition. Typically, a talon cusp extends at least half the distance from the cement–enamel junction to the incisal edge in the palatal or labial surface. It contains enamel, dentin and/or pulp (Kasat, Singh, Saluja, & Ladda, 2014; Malineni, Panampally, Chen, & Tian, 2014).

**Replaces term:** Eagle talon; Dens evaginatus; Cingulum, prominent

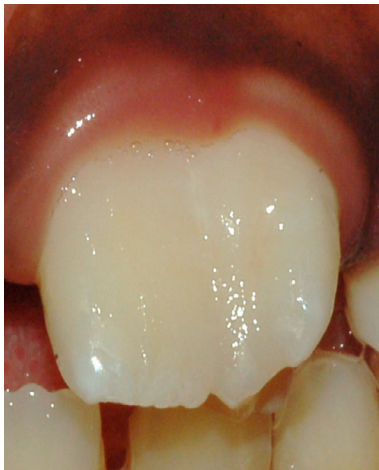

**FIGURE 24** Double teeth in the deciduous dentition. Teeth fused: Fusion of the central incisor with the lateral incisor. Radiograph exhibit the absence of the lateral incisor. Teeth gemination: Tooth germination of right maxillary incisor—clinical aspect and radiograph. Gemination concerned the crown and the beginning of the root. The lateral incisor is present, so the patient has a normal number of teeth [Color figure can be viewed at wileyonlinelibrary.com]





**FIGURE 25** Dens in dente on the left lateral maxillary permanent incisor



**FIGURE 26** Notched shape of permanent central incisors [Color figure can be viewed at [wileyonlinelibrary.com](http://wileyonlinelibrary.com)]

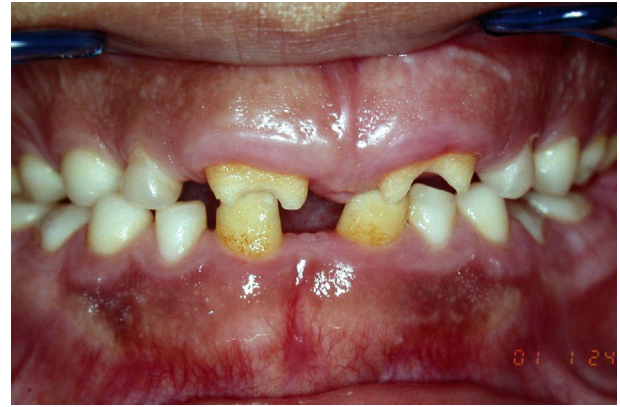## 4.23 | Teeth, double

### 4.23.1 | Definition

Fusion of two adjacent teeth (Figure 24). *Objective.*

### 4.23.2 | Comments

The fusion can be complete or be limited to the crown or the root. Typically, incisors and canines form double teeth. Double teeth are more common in the deciduous dentition (0.14–3%) and rare in the permanent dentition (0.2%). Double teeth encompasses fusion, concrescence, and gemination of teeth, which some authors describe with the “twinning” (Hunasgi, Koneru, Manvikar, Vanishree, & Amrutha, 2017). The fusion involves two adjacent, normal teeth. Seemingly, the



**FIGURE 27** Semi lunar shape of the incisal edge of the maxillary central incisor in an enamel renal syndrome [Color figure can be viewed at [wileyonlinelibrary.com](http://wileyonlinelibrary.com)]

patient misses a tooth. Concrescence is a condition where the roots are joined only by cementum. The gemination appears when two teeth are developing from one tooth bud leading to a supernumerary tooth formation fused with the normal tooth germ. The patient has a normal number of teeth.

**Replaces term:** Twinning tooth

**Synonym:** Teeth gemination; Teeth fused

Teeth, fused: see **Teeth, double**.

Teeth, gemination: see **Teeth, double**.

## 4.24 | Dens in dente

### 4.24.1 | Definition

Invagination of part of the crown of a tooth inside the crown (Figure 25). *Subjective.*

### 4.24.2 | Comments

Dens in dente results from an invagination of the enamel organ into the dental papilla, extending into the root before initiation of mineralization. The incidence varies from 0.25 to 10% (Hulsmann, 1997). The permanent maxillary lateral incisors are the most frequently involved teeth (6–10% of affected teeth), but it can occur in any tooth type. It occurs more frequently in the permanent dentition and in maxillary teeth. The diagnosis dens in dente needs to be confirmed by X-rays.

**Synonym:** Dens invaginatus

## 4.25 | Tooth, notched

### 4.25.1 | Definition

A tooth with a notch of the incisal edge (Figure 26). *Subjective.*

#### 4.25.2 | Comments

This notch may indicate a **double tooth** formation. A notched tooth should not be confused with *mamelons*.

#### 4.26 | Tooth, semi-lunar

##### 4.26.1 | Definition

An incisor with a half-moon shape incisal edge (Figure 27). *Subjective*.

##### 4.26.2 | Comments

If a notch occupies most of incisal edge, it has been indicated as semi-lunar teeth or crescent-shaped.

**Synonym:** Tooth, crescent-shape; Tooth, semi-circular; Hutchinson incisor

#### 4.27 | Root, anomaly

##### 4.27.1 | Definition

Alteration of the number, shape or the size of roots. *Objective*.

##### 4.27.2 | Comments

Size of roots encompasses their thickness and length. A root may be abnormally short or long.

**Replaces term:** Root dystrophy; Root dysplasia

#### 4.28 | Radiculomegaly

##### 4.28.1 | Definition

Tooth root length more than 2 SD above mean. *Objective*.

OR apparently increased tooth root length 5 (Figure 28). *Subjective*.

##### 4.28.2 | Comments

Standard references for means and standard deviations by gender are available (Black, 1890; Lavelle, 1972). It may concern one or multiple teeth. The diagnosis radiculomegaly needs to be confirmed by X-rays.

**Synonym:** Rhizomegaly

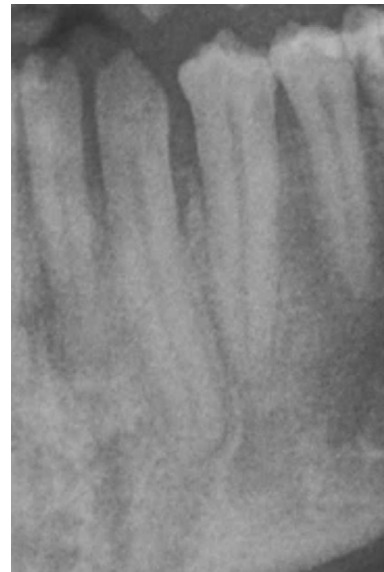Rhizomegaly: see **Radiculomegaly**.

#### 4.29 | Root, short

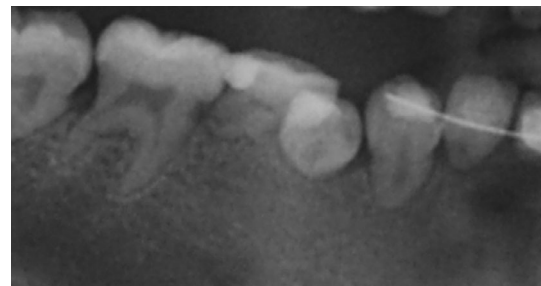##### 4.29.1 | Definition

Tooth root length more than 2 SD below mean. *Objective*.

OR apparently decreased tooth root length (Figure 29). *Subjective*.



**FIGURE 28** Radiculomegaly



**FIGURE 29** Short root in a dentinogenesis imperfecta tooth

##### 4.29.2 | Comments

Standard references for means and standard deviations by gender are available (Black, 1890; Lavelle, 1972). It may concern one or multiple teeth. The diagnosis of short roots needs to be confirmed by X-rays.

**Replaces term:** Root dwarfism; root hypoplasia; root hypotrophy

**Synonym:** Rhizomicry; Root, underdeveloped

Root, underdeveloped: see **Root, short**.

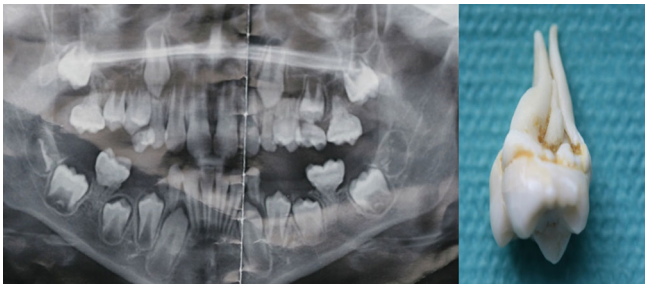
#### 4.30 | Molar incisor malformation

##### 4.30.1 | Definition

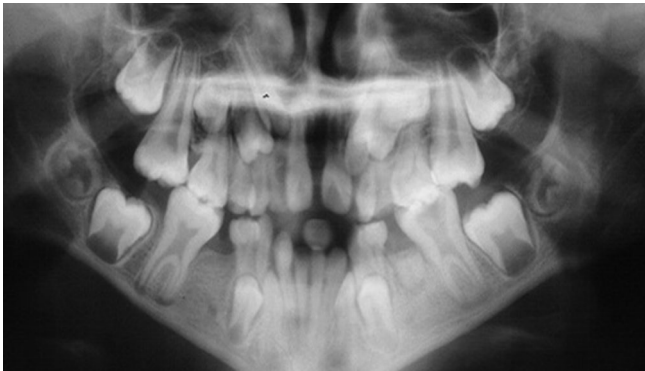
This is a bundled term as molar incisor malformation (MIM) and is composed of normal crown with marked cervical constriction, thin, narrow **short roots** which is a combination of signs that occurs in deciduous and permanent molars. Each of these signs should be assessed and scored separately. *Subjective*.

##### 4.30.2 | Comments

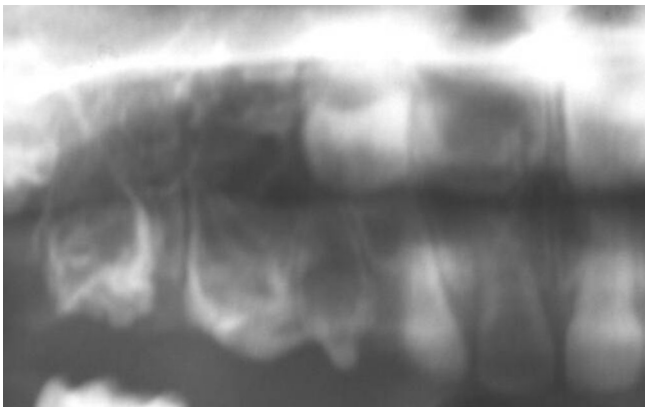MIM affects one or more roots of deciduous second molars and permanent first molars (Figure 30) (Brusevold, Bie, Baumgartner, Das, &



**FIGURE 30** Molar-incisor-malformation: first permanent molar with short, thin root or rootless teeth [Color figure can be viewed at [wileyonlinelibrary.com](http://wileyonlinelibrary.com)]



**FIGURE 31** Taurodontic molars



**FIGURE 32** Regional odontodysplasia in the upper right quadrant

Espelid, 2017; McCreedy, Robbins, Newell, & Mallya, 2016). Permanent maxillary central incisors may also be affected. The diagnosis requires clinical and radiographic examinations.

#### 4.31 | Taurodontia

##### 4.31.1 | Definition

A crown body–root ratio equal or larger than 1:1. *Objective.*

Or elongated pulp chambers and apical displacement of the bifurcation or trifurcation of the roots (Figure 31). *Subjective.*

##### 4.31.2 | Comments

Taurodontia causes a molar shape that is visible on radiographs. Taurodontic teeth display proportionately *short roots* and enlarged pulp chambers. Normal values for crown body–root ratio are available (Seow & Lai, 1989).

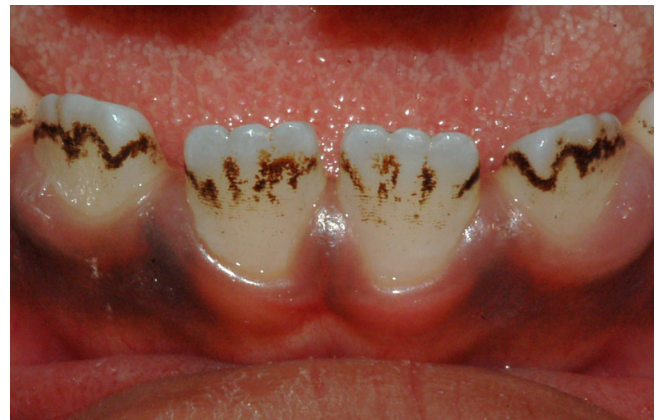#### 4.32 | Odontodysplasia

##### 4.32.1 | Definition

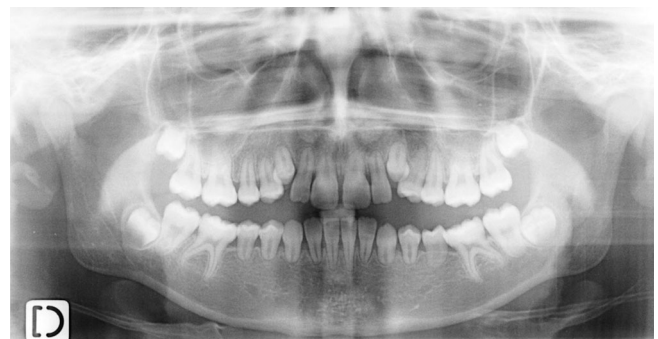A tooth with enamel and dentin hypomineralization anomalies causing marked reduction in radio-opacity (Figure 32). *Subjective.*

##### 4.32.2 | Comments

The diagnosis odontodysplasia requires clinical and radiological exams, in which unusually large pulp chambers and large pulp room chambers with thin enamel and dentin are visible. It may affect either a single tooth or several teeth. The term regional odontodysplasia is used if several teeth are affected. It affects the deciduous and permanent dentitions in the maxilla, the mandible or both, although the maxilla is more frequently involved.



**FIGURE 33** Extrinsic coloration on the surface of permanent incisors [Color figure can be viewed at [wileyonlinelibrary.com](http://wileyonlinelibrary.com)]



**FIGURE 34** Dentin dysplasia [Color figure can be viewed at [wileyonlinelibrary.com](http://wileyonlinelibrary.com)]



Replaces term: Tooth, shell; Tooth, ghost teeth; Tooth, dystrophy

**4.34.2 | Comments**

The application of color science within dentistry has permitted the measurement of tooth color in an objective way (Joiner & Luo, 2017).

A tooth may show a variety of abnormal colors such as yellow, brown, gray, green color, and red. This should be assessed and added to the

**4.33 | Anomaly, dental structure**

**4.33.1 | Definition**

Anomaly in the structure of mineralized tissues of a tooth (Figures 34–39). *Subjective.*

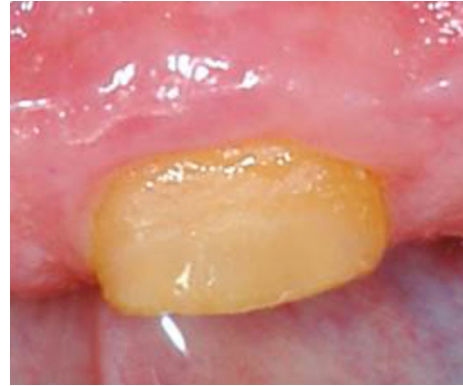**4.33.2 | Comments**

This is a bundled term with which anomalies of enamel and/or dentin and/or cement are indicated. The affected dental structure should be assessed and coded separately.

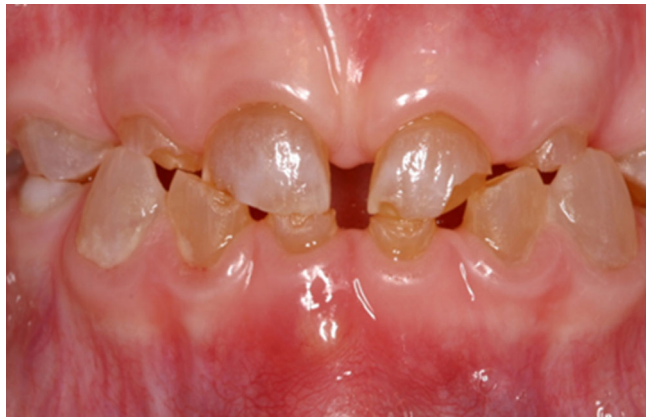**4.34 | Anomaly, dental color**

**4.34.1 | Definition**

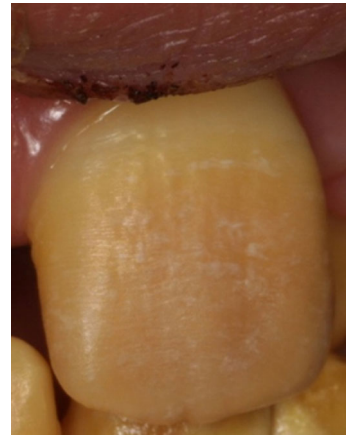
Discoloration of teeth (Figure 33). *Subjective.*



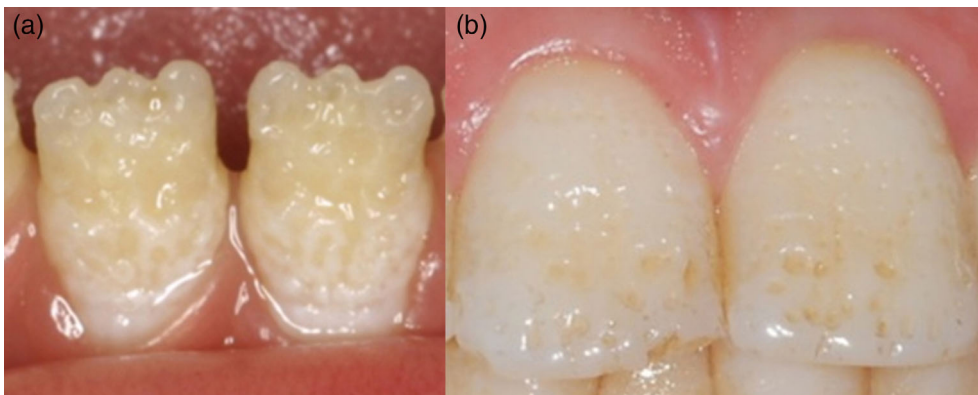
**FIGURE 37** Enamel agenesis [Color figure can be viewed at [wileyonlinelibrary.com](http://wileyonlinelibrary.com)]



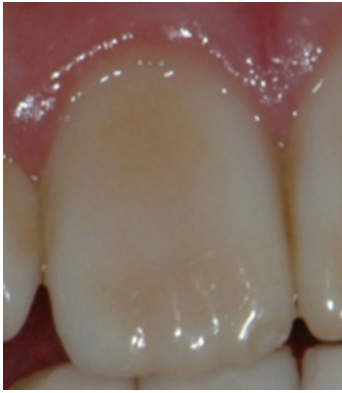**FIGURE 35** Dentinogenesis imperfecta in the permanent dentition [Color figure can be viewed at [wileyonlinelibrary.com](http://wileyonlinelibrary.com)]



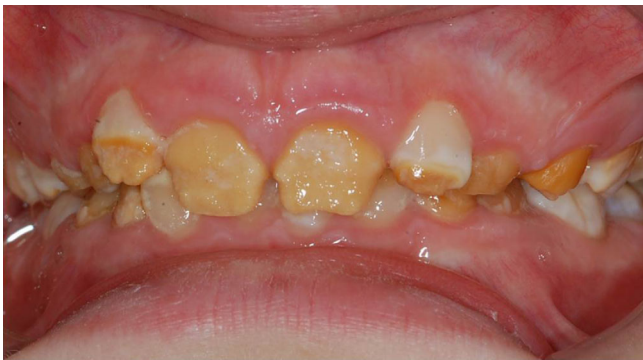**FIGURE 38** Enamel hypomineralization [Color figure can be viewed at [wileyonlinelibrary.com](http://wileyonlinelibrary.com)]



**FIGURE 36** Enamel hypoplasia with pitting of the mandibular central incisors (a) and the maxillary central incisors (b) [Color figure can be viewed at [wileyonlinelibrary.com](http://wileyonlinelibrary.com)]



**FIGURE 39** Enamel hypomaturity [Color figure can be viewed at [wileyonlinelibrary.com](http://wileyonlinelibrary.com)]



**FIGURE 40** Amelogenesis imperfecta with enamel chipping on the maxillary lateral incisor [Color figure can be viewed at [wileyonlinelibrary.com](http://wileyonlinelibrary.com)]

description of a discolored tooth. Discoloration of teeth may be due to extrinsic discoloration (stains that develop on the outer surface of a tooth, Figure 33) or intrinsic discoloration (stains that arise from an endogenous material incorporated into the enamel or dentin and cannot be removed by prophylaxis). It may be also a consequence of dental structure anomaly.

## 4.35 | Dentin anomaly

### 4.35.1 | Definition

Structural anomaly of dentin at macroscopic or microscopic level (Figures 34 and 35). *Subjective*.

### 4.35.2 | Comments

Dentin anomalies are known only to occur in genetically determined disorders. The structure of dentin is very similar to that of bone, and skeletal dysplasia frequently shows dentin anomalies as well.

**Replaces term:** Dentin dysplasia; Dentin dystrophy; Dentinogenesis imperfecta

**Synonym:** Dentin defect

Dentin defect: see *Dentin anomaly*.

## 4.36 | Dentin dysplasia

### 4.36.1 | Definition

This is a bundled term as dentin dysplasia is composed of *short roots* with pointed ends and *taurodontism* and *intrapulpal calcifications* (Figure 34). *Subjective*.

### 4.36.2 | Comments

This term designates a genetic condition, and an Element of Morphology rendering its utilization sometimes confusing. The condition is characterized by multiple dental anomalies that affect both deciduous and permanent dentitions. It can exist in isolation or be associated with other signs and symptoms of various syndromes.

## 4.37 | Dentinogenesis imperfecta

### 4.37.1 | Definition

This is a bundled term as dentinogenesis imperfecta and is composed of *crown discoloration*, *bulbous crown*, *short roots*, *intra-pulpal calcification*, which is a combination of signs that occurs in several disorders in deciduous and permanent teeth. Each of these signs should be assessed and scored separately (Figure 35).

### 4.37.2 | Comments

This term designates a genetic condition, and an Element of Morphology rendering its utilization sometimes confusing. The condition is characterized by multiple dental anomalies that affect both deciduous and permanent dentitions. It can exist in isolation or be associated with other signs and symptoms of various syndromes. Dentinogenesis imperfecta shows variable expression with mild, moderate, and severe forms that correspond respectively to earlier dentin dysplasia type II, dentinogenesis imperfecta type II, and dentinogenesis imperfecta type III of the Shield classification, allelic to dentine sialophosphoprotein defects (de La Dure-Molla et al., 2015).

## 4.38 | Enamel dysplasia

### 4.38.1 | Definition

Alteration of color, shape, surface, and/or structure of enamel (Figures 36–40). *Subjective*.

### 4.38.2 | Comments

Enamel dysplasia may reflect qualitative or quantitative alteration of enamel structure. Enamel dysplasia encompasses *enamel hypoplasia*, *enamel agenesis*, *enamel hypomineralization*, *enamel hypomaturity*, and *amelogenesis imperfecta*.

**Synonym:** Enamel anomaly; Enamel defect

## 4.39 | Enamel, hypoplasia

### 4.39.1 | Definition

A quantitative defect in enamel formation (Figure 36). *Subjective.*

### 4.39.2 | Comments

Enamel hypoplasia can be caused by genetic or environmental factors. It may occur in both deciduous and permanent dentitions, although more often in the permanent dentition. Enamel hypoplasia may concern a single tooth, several teeth, or the complete dentition and may affect part or the complete surface of the tooth. Enamel hypoplasia regroups different clinical aspects: localized hypoplasia, generalized hypoplasia, enamel pits, enamel striae, and grooves defects. The term should be used to describe a quantitative defect of enamel. Enamel hypotrophy cannot be used as hypotrophy indicates loss of cells, whereas enamel is an acellular structure and thus not a tissue.

**Replaces term:** enamel hypotrophy

**Synonym:** Enamel, thin; Enamel, pitted; Enamel, underdeveloped

## 4.40 | Enamel, agenesis

### 4.40.1 | Definition

Complete or almost complete absence of enamel (Figure 37). *Subjective.*

### 4.40.2 | Comments

Enamel agenesis can indicate a total absence of enamel or the presence of a very thin enamel layer that is difficult to visualize during clinical examination. It may need microscopic studies to determine whether any enamel is still present. It can be present isolated and as part of rare syndromic entities (de La Dure-Molla et al., 2015; Huckert et al., 2015).

Enamel, hypocalcification: see *Enamel, hypomineralization.*

## 4.41 | Enamel, hypomineralization

### 4.41.1 | Definition

Enamel with a brown discoloration and brittle aspect. (Figure 38). *Subjective.*

### 4.41.2 | Comments

Enamel hypomineralization can be caused by genetic or environmental factors. It may occur in both deciduous and permanent dentitions, although more often in the permanent dentition. It may concern a single tooth, several teeth, or the complete dentition and may affect part or the complete surface of the tooth. Enamel hypomineralization is a qualitative defect of enamel, in which the enamel can be rough and softer. Affected teeth may be sensitive. Enamel hypomineralization can be part of molar incisor hypomineralization (hypomineralisation of systemic origin of one to four permanent first molars, frequently

associated with affected incisors) (Weerheijm, 2003) and of hypomineralized second primary molars (or deciduous molar hypomineralisation, which indicates idiopathic hypomineralization of one to four second deciduous molars) (Negre-Barber, Montiel-Company, Boronat-Catala, Catala-Pizarro, & Almerich-Silla, 2016).

**Synonym:** Enamel, hypocalcification

## 4.42 | Enamel, hypomature

### 4.42.1 | Definition

Enamel with a white or brown discoloration without hypoplasia (Figure 39). *Subjective.*

### 4.42.2 | Comments

Enamel maturation is a process through which enamel matrix proteins are removed to allow full growth of the enamel hydroxyapatite crystals. Hypomature enamel can be caused by genetic or environmental factors. It may occur in both deciduous and permanent dentitions, although more often in the permanent dentition. Hypomature enamel may concern a single tooth, several teeth, or the complete dentition and may affect part or the complete surface of the tooth. The enamel is usually hard, colored but not translucent. It is a qualitative defect of enamel.

**Synonym:** Enamel opacity

Enamel opacity: see *Enamel, hypomature.*

Enamel, pitted: see *Enamel hypoplasia.*

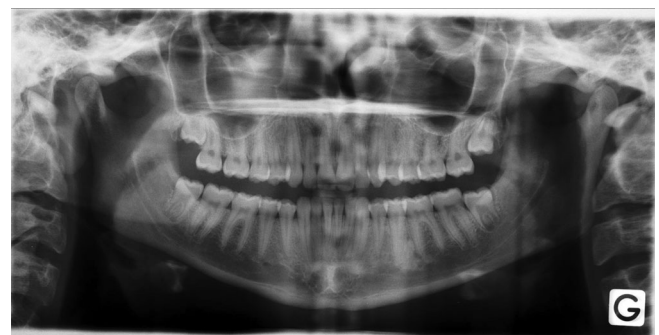Enamel, thin: see *Enamel hypoplasia.*

Enamel underdevelopment: see *Enamel hypoplasia.*

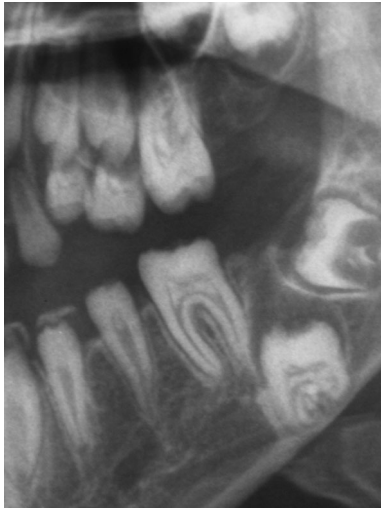## 4.43 | Amelogenesis imperfecta

### 4.43.1 | Definition

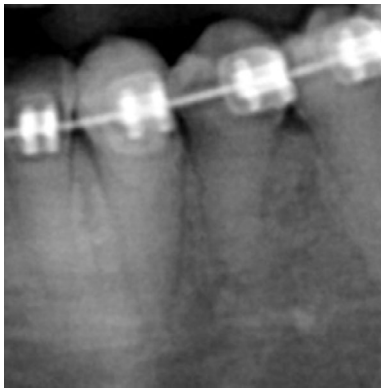
This is a bundled term as amelogenesis imperfecta and is composed of *crown discoloration* and/or *enamel dysplasia* (Figure 40). *Subjective.*



**FIGURE 41** Cementum hyperplasia at the root of the mandibular left second premolar



**FIGURE 42** Pulp calcification within the pulp chamber of the molar and the second premolar



**FIGURE 43** Pulp obliteration in dentinogenesis imperfecta

#### 4.43.2 | Comments

Amelogenesis imperfecta generally affects all elements and both deciduous and permanent teeth. The term designates both a genetic condition, and an Element of Morphology rendering its utilization sometimes confusing. It describes enamel defects (*hypoplasia*, *hypomineralization*, *hypomaturation*) that usually affect (but not always) both deciduous and permanent dentitions.

#### 4.44 | Cementum, hypoplasia

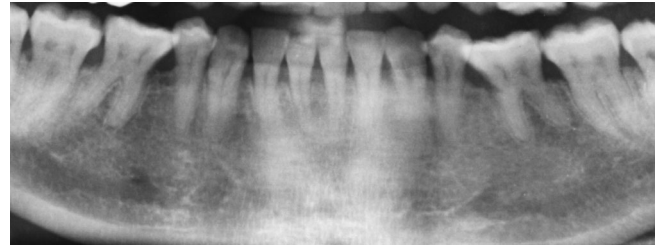
##### 4.44.1 | Definition

The decrease or absence of cementum. *Subjective*.

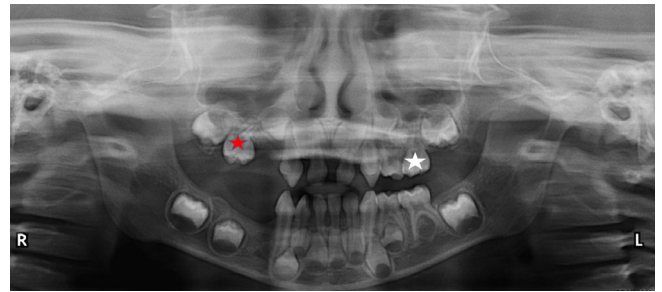
##### 4.44.2 | Comments

The cementum anchors the periodontal ligament attachment fiber between the tooth root and the alveolar bone. Its absence leads to early loss of teeth.

**Replaces term:** Cementum aplasia



**FIGURE 44** Pulp thistle tube shaped of mandibular teeth



**FIGURE 45** Delayed eruption of the second deciduous maxillary right molar (red star) in an oligodontia patient. See the counterlateral second primary left upper deciduous molar (white star) in occlusion [Color figure can be viewed at [wileyonlinelibrary.com](http://wileyonlinelibrary.com)]

Cementum, overdeveloped: see *Cementum, overgrowth*.

#### 4.45 | Cementum, overgrowth

##### 4.45.1 | Definition

Excess of cementum on the tooth root surface (Figure 41). *Subjective*.

##### 4.45.2 | Comments

The excessive buildup of normal cementum (calcified tissue) on the roots of one or more teeth is an idiopathic, non-neoplastic condition. Cementum overgrowth may be either hyperplasia or hypertrophy of the cement; these terms can only be used if histological evidence of hypertrophy or hyperplasia have been established.

**Replaces term:** Cementation hyperplasia; Cementum hypertrophy; Drumstick-shaped root

**Synonym:** Hypercementosis; Cementum, overdeveloped  
Hypercementosis: see *Cementum, overgrowth*.

#### 4.46 | Pulp, calcification

##### 4.46.1 | Definition

Calcifications of dental pulp (Figure 42). *Subjective*.



#### 4.46.2 | Comments

Calcifications may appear as punctate calcifications, irregular, roughly spherical mineralized masses in any part of the pulp. It may occur isolated or associated to calcifications elsewhere such as the carotid arteries and kidneys (Yeluri, Kumar, & Raghav, 2015). The diagnosis pulp calcifications can be established using radiological studies.

Replaces term: Pulpoliths

**Synonym:** Pulp stones; Pulp denticles

Pulp denticles: see *Pulp, calcification*.

Pulp, flame-shaped: see *Pulp, Thistle tube shaped*.

#### 4.47 | Pulp, obliteration

##### 4.47.1 | Definition

Mineralized substance filling the entire dental pulp space (Figure 43). *Subjective*.

##### 4.47.2 | Comments

The diagnosis pulp obliteration can be established using radiological studies. Gradual obliteration of the pulp is a physiologic process that occurs with aging. On radiographs the contours of the pulp disappear in part or totally, but histologically pulpal tissue remains present.

Pulp stones: see *Pulp, calcification*.

#### 4.48 | Pulp, thistle tube shaped

##### 4.48.1 | Definition

A thistle tube shape of the pulp chamber (Figure 44). *Subjective*.

##### 4.48.2 | Comments

Enlarged coronal pulp chamber with narrow pulp canals giving a radiographic appearance of the shape of a thistle tube or a flame. It may occur isolated or associated to other dental anomalies rare diseases such as *dentinogenesis imperfecta*, which should be assessed and coded separately. The diagnosis thistle tube shape pulp requires clinical and radiographic examinations.

**Synonym:** Pulp, flame-shaped

Eruption, advanced: see *Tooth, premature eruption*.

#### 4.49 | Eruption, delayed

##### 4.49.1 | Definition

Eruption of a tooth more than 2 SD beyond the mean eruption age (Figure 45). *Objective*.

#### 4.49.2 | Comments

Eruption is defined by the appearance of a tooth that has pierced the oral mucosa. There are established norms for the timing of eruption in both deciduous and permanent teeth (Lunt & Law, 1974; McDonald et al., 2004). Eruption delay may affect either the deciduous teeth, permanent teeth, or both. The absence of shedding of deciduous teeth may be seen in association with delayed permanent tooth eruption or agenesis of successional permanent teeth. The diagnosis eruption delayed requires clinical and radiographic examinations.

#### 4.50 | Eruption, failure

##### 4.50.1 | Definition

A tooth which does not erupt within the teeth eruption timeline and after the loss of eruption potential (Figure 46). *Objective*.

##### 4.50.2 | Comments

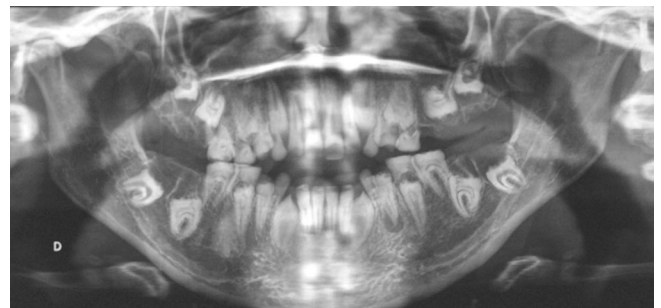Usually a tooth erupts at a stage of half or two-third root formation. There are established norms for the timing of eruption and tooth stages in both deciduous and permanent teeth (Lunt & Law, 1974; McDonald et al., 2004). It may be difficult to discern *Delayed eruption* from failure of eruption: failure indicates it will never erupt, delayed indicates it may still erupt. Eruption failure may be caused by an isolated obstacle (supernumerary teeth), ankylosis of impacted teeth, or disturbances of biological eruption pathway. Partial or complete non-eruption of not initially ankylosed teeth due to a disturbed eruption mechanism result in a severe form of posterior open bite that usually worsens from anterior to posterior. Eruption failure is usually asymmetrical, affects more posterior teeth and both dentition may be involved (Pilz et al., 2014). The diagnosis eruption failure requires clinical and radiographic examinations.

**Synonym:** Tooth, impacted; Tooth, retained

#### 4.51 | Primary failure of eruption

##### 4.51.1 | Definition

Eruption failure of permanent teeth in the absence of an obstacle hindering tooth progression toward the oral cavity. *Objective*.



**FIGURE 46** Eruption, failure of all permanent molars



#### 4.51.2 | Comments

This is a bundled term as Primary failure of eruption (PFE) and is composed of *eruption failure*, *tooth ankylosis*, *tooth infraoccluded*, posterior lateral *open bite*. Each of these signs should be assessed and scored separately. The term designates both a genetic condition, and an Element of Morphology rendering its utilization sometimes confusing.

The non-eruption mechanism defect is due to an abnormal dental follicle, partially or totally blocking tooth progression. It usually involves one or multiple molar sectors. Incisors, canines, and premolars may also be involved but with a reduced individual frequency. The diagnosis Primary failure of eruption failure requires clinical and radiographic examinations.

Tooth, impacted: see *Eruption, failure*.

#### 4.52 | Tooth, premature loss

##### 4.52.1 | Definition

Exfoliation of a tooth more than 2 SD earlier than the normal age for the deciduous teeth. Exfoliation of a permanent tooth is per se abnormal. (Figure 47). *Objective*.

##### 4.52.2 | Comments

Premature loss of a tooth may concern deciduous and permanent teeth. The range of ages in years for normal exfoliation of deciduous teeth usually precedes the mean age of eruption of each tooth by a year or less (Hennekam et al., 2010; Kleigman, Behrman, Jenson, & Stanton, 2007).

**Replaces term:** Exfoliation, early

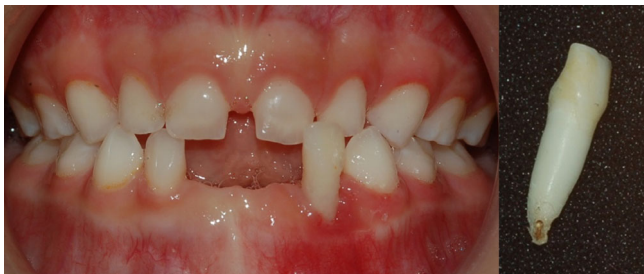#### 4.53 | Tooth, premature eruption

##### 4.53.1 | Definition

A tooth which erupts more than 2 SD earlier than the mean eruption age (Figure 48). *Objective*.

##### 4.53.2 | Comments

Eruption is defined by the appearance of a tooth that has pierced the oral mucosa. There are established norms for the timing of eruption of



**FIGURE 47** Tooth, premature loss of the central mandibular incisors [Color figure can be viewed at [wileyonlinelibrary.com](http://wileyonlinelibrary.com)]

both deciduous and permanent teeth (Lunt & Law, 1974; McDonald et al., 2004) Tooth eruption sequences follow broadly similar and symmetrical patterns during establishment of the deciduous and permanent dentitions, although wide individual variation in timing is common. Eruption timing depends on the population studied. Norms are typically specific for populations (Baylis & B. R., 2017; Verma et al., 2017).

**Synonym:** Eruption advanced; Tooth, advanced development

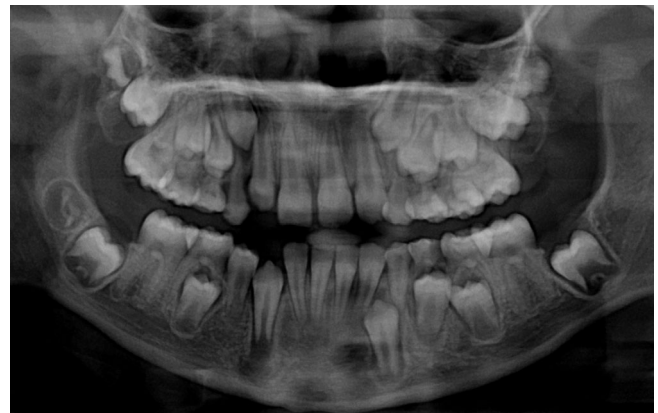#### 4.54 | Tooth, infraoccluded

##### 4.54.1 | Definition

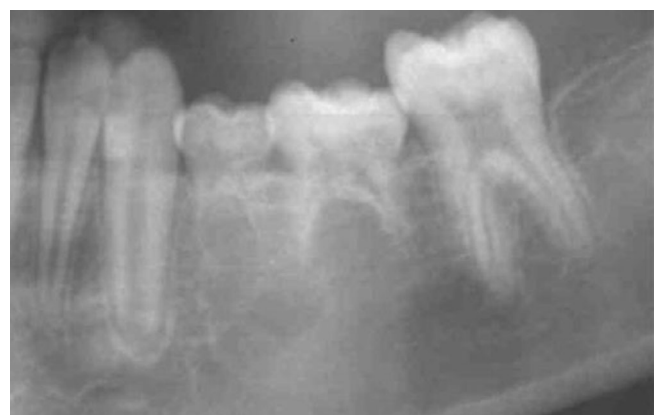A tooth with its occlusal surface at a lower level than the adjacent teeth (Figure 49). *Subjective*.

##### 4.54.2 | Comments

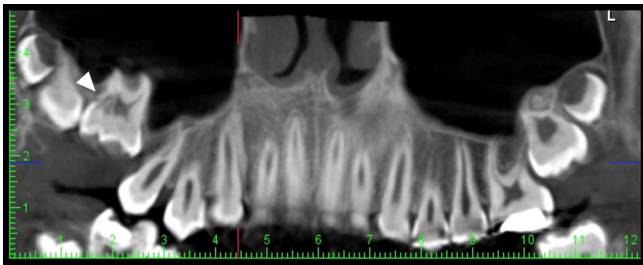
Infraocclusion of a tooth typically concerns deciduous molars. Two anomalies may be described: (1) a halt of the eruption of a tooth shortly after emergence in the oral cavity, despite the lack of a physical obstacle in the eruption pathway (Nielsen, Becktor, & Kjaer, 2006);



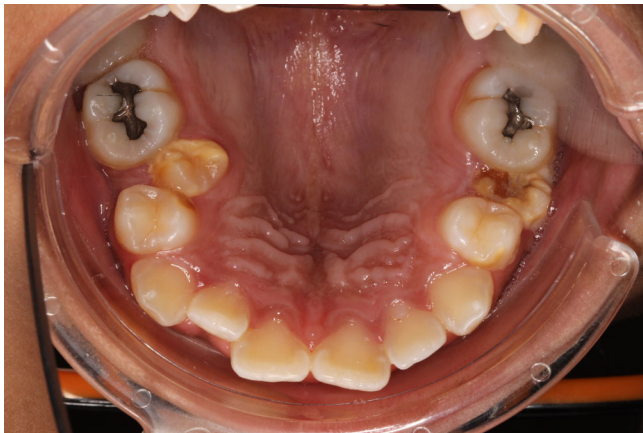**FIGURE 48** Tooth, premature eruption of the first lower right premolar in an 8 year old individual



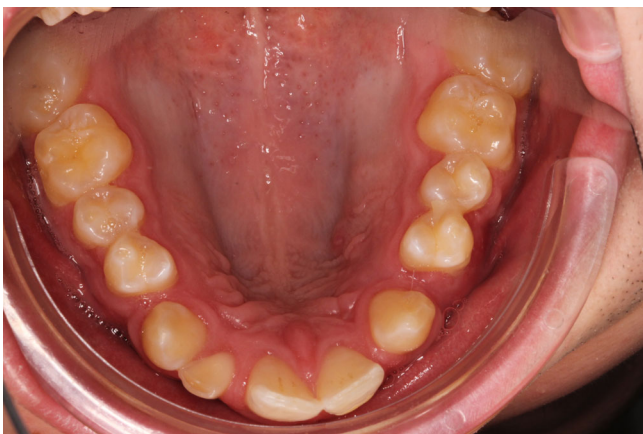**FIGURE 49** Tooth infraoccluded of first and second deciduous molars associated with agenesis of premolars



**FIGURE 50** Tooth ankylosis (arrow head) [Color figure can be viewed at [wileyonlinelibrary.com](http://wileyonlinelibrary.com)]



**FIGURE 51** Tooth malalignment showing palatal position of the second premolar and right lateral incisor [Color figure can be viewed at [wileyonlinelibrary.com](http://wileyonlinelibrary.com)]



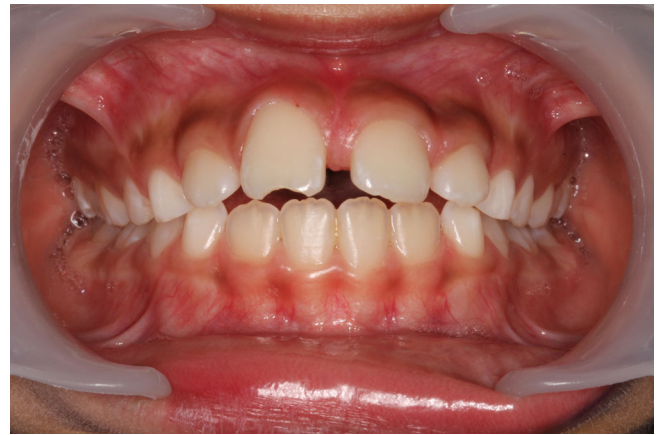**FIGURE 52** Teeth spaced between right central incisor and canine and agenesis of the lateral incisor [Color figure can be viewed at [wileyonlinelibrary.com](http://wileyonlinelibrary.com)]

(2) ankylosis of deciduous teeth which is in occlusion and then will become infraoccluded during adjacent teeth eruption especially permanent teeth during the mixed dentition phase (Raghoebar, Boering, & Vissink, 1991).

**Replaces term:** Reincluded teeth

**Synonym:** Tooth, submerging; Tooth, infrapositioned

Tooth, infrapositioned: see **Tooth, infraoccluded**.



**FIGURE 53** Diastema between maxillary central incisors [Color figure can be viewed at [wileyonlinelibrary.com](http://wileyonlinelibrary.com)]

Tooth, submerging: see **Tooth, infraoccluded**.

#### 4.55 | Tooth, ankylosis

##### 4.55.1 | Definition

Fusion of a tooth with alveolar bone (Figure 50). *Subjective*.

##### 4.55.2 | Comments

Ankylosis is uncommon in the deciduous dentition and very rare in the permanent dentition. It may be observed after trauma. Ankylosis may occur at the crown or root level.

#### 4.56 | Teeth, malposition

##### 4.56.1 | Definition

Location of a tooth out of its normal position or orientation (Figure 51). *Subjective*.

##### 4.56.2 | Comments

Anomalies of tooth position can be classified into ectopic (in an abnormal location), transmigration (pre-eruptive migration to a location some distance away), transposition (positional interchange of two adjacent teeth), rotation (tooth turning along its long axis), crowding (malalignment of tooth row). This should be added in describing a malpositioned tooth.

**Replaces term:** Irregular dentition

#### 4.57 | Dental crowding

##### 4.57.1 | Definition

Changes in alignment of teeth in the dental arch (Figure 54). *Subjective*.

#### 4.57.2 | Comments

There is a discrepancy in the space needed to align the teeth and the size of the alveolar ridge.

**Replaces term:** Irregular teeth, Irregular dentition

**Synonym:** Teeth, malalignment; Teeth, misalignment

Teeth, malalignment: see *Dental crowding*.

Teeth, misalignment: see *Dental crowding*.

#### 4.58 | Teeth, spaced

##### 4.58.1 | Definition

Separation of teeth of the same dental arch by wider spaces than normal (Figure 52). *Subjective*.

##### 4.58.2 | Comments

Wide spacing can be secondary to increased room by an unusually large dental arch or smaller teeth (microdontia) or if mixed deciduous and secondary dentition are present. Slight spacing between the deciduous teeth is physiological, and experience in evaluation is important in determining this feature. This descriptor must be distinguished from a *diastema*. The difference between diastema and widely spaced teeth is that diastema is between two teeth and widely spaced

teeth between more than two teeth. Normal values of dental spacing are not available.

Replaces term: Diastemata

Dental malocclusion: see *Occlusion, anomaly*.

#### 4.59 | Diastema

##### 4.59.1 | Definition

Increased space between two adjacent teeth (Figure 53). *Subjective*.

##### 4.59.2 | Comments

Usually, there is a contact surface between the lateral sides of two adjacent teeth, at their broadest contour area. A diastema can apply to any pair of teeth. The term should be modified by a descriptor of the involved teeth. This descriptor must be distinguished from widely spaced teeth. Midline diastema refers to the diastema between the upper central incisors.

#### 4.60 | Occlusion anomaly

##### 4.60.1 | Definition

Alteration of the dental arch relationships in form or position (Figure 55). *Objective*.

##### 4.60.2 | Comments

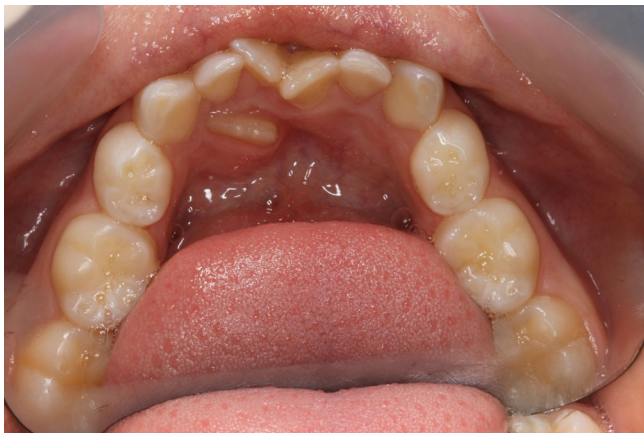Occlusion anomalies include a large variety of disturbed occlusion such as disto-occlusion, mesio-occlusion, midline deviation of dental arch, overjet, and posterior lingual occlusion of mandibular teeth. The Angle classification is used to define dental relationship using the first permanent maxillary molar position as a reference: Class I: normocclusion, Class II (distocclusion) retrognathism; Class III mesiocclusion (prognathism) (Angle, 1899).

**Synonym:** Dental malocclusion

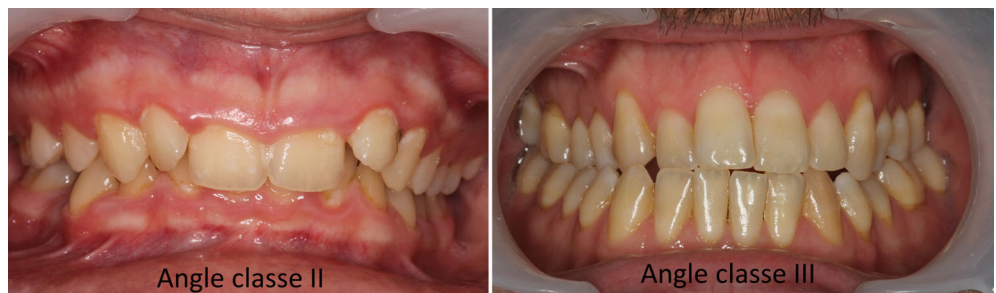#### 4.61 | Open bite

##### 4.61.1 | Definition

Visible anterior space between the dental arches in occlusion (Figure 56). *Subjective*.



**FIGURE 54** Dental crowding: rotation of mandibular incisors and palatal eruption of the left lateral incisor [Color figure can be viewed at wileyonlinelibrary.com]



**FIGURE 55** Occlusion anomaly (Angle class II and III) [Color figure can be viewed at wileyonlinelibrary.com]



#### 4.61.2 | Comments

Open bite produces an absence of vertical overlap of the two dental arches. It may be associated with malocclusion, but this should be assessed and coded separately. Open bite may occur in the anterior or posterior part of the arches which are called anterior open bite, frontal open bite and lateral open bite, respectively. This should be added in describing an open bite.

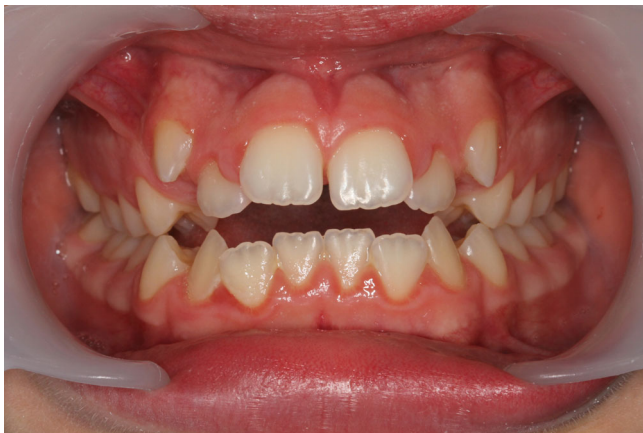#### 4.62 | Cross bite

##### 4.62.1 | Definition

Lingual occlusion of buccal cusps and/or incisal edge of maxillary teeth to the buccal cusps and/or incisal edge of mandibular teeth (Figure 57). *Subjective.*

##### 4.62.2 | Comments

Cross bite may occur unilaterally, bilaterally, or frontally. A total cross bite with buccal displacement of the maxillary posterior teeth, with or without contact between the lingual surface of the maxillary lingual cusp and the buccal surface of the



**FIGURE 56** Open bite evident in the absence of contact between dental arches [Color figure can be viewed at [wileyonlinelibrary.com](http://wileyonlinelibrary.com)]

buccal cusp of its mandibular antagonist, has been called scissor bite. If only a single tooth is affected, the term single cross bite can be used.

#### 4.63 | Overbite, increased

##### 4.63.1 | Definition

Vertical overlap (frontal plane) of maxillary incisors over mandibular incisors exceeding 2 mm (Figure 58). *Objective.*

##### 4.63.2 | Comments

An overjet concerns only anterior teeth.

Supraocclusion: see **Overbite, increased**.

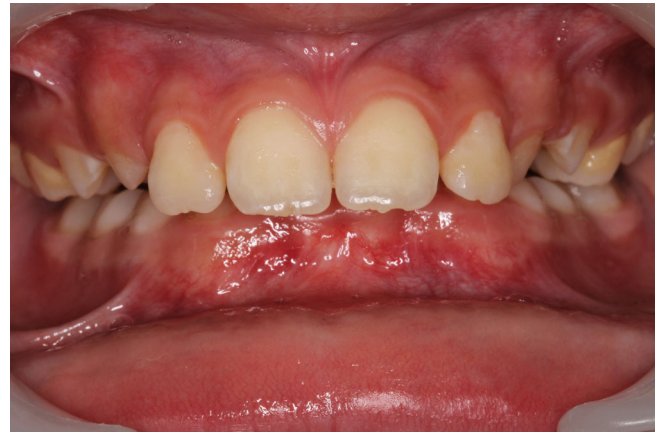An overbite concerns only anterior teeth.

**Synonym:** Supraocclusion; Deep bite

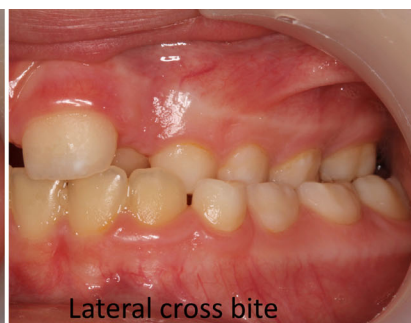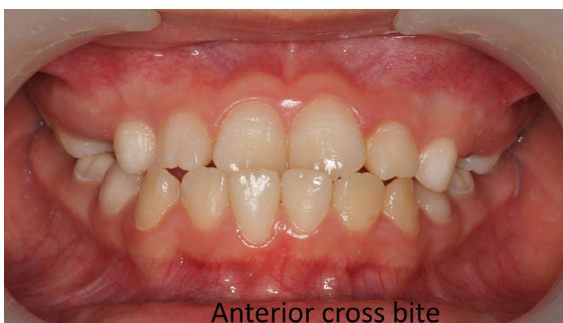#### 4.64 | Overjet, increased

##### 4.64.1 | Definition

Horizontal overlap (sagittal plane) of upper frontal teeth over the lower frontal teeth exceeding 3.5 mm (Figure 59). *Objective.*



**FIGURE 58** Overbite, increased evident in overlap of maxillary incisors over the mandibular ones [Color figure can be viewed at [wileyonlinelibrary.com](http://wileyonlinelibrary.com)]



**FIGURE 57** Cross bite (anterior and lateral) [Color figure can be viewed at [wileyonlinelibrary.com](http://wileyonlinelibrary.com)]

## 4.65 | Gingival, overgrowth

### 4.65.1 | Definition

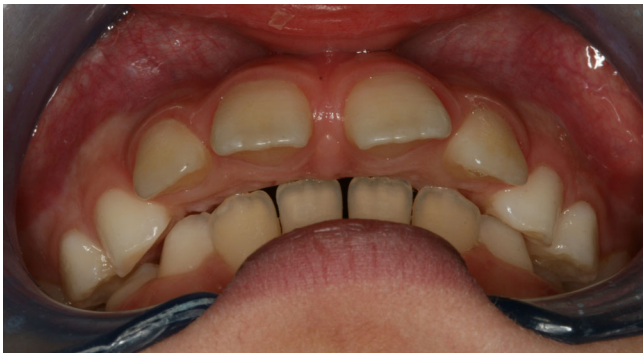Thickening of the gingiva (Figure 60). *Subjective.*

### 4.65.2 | Comments

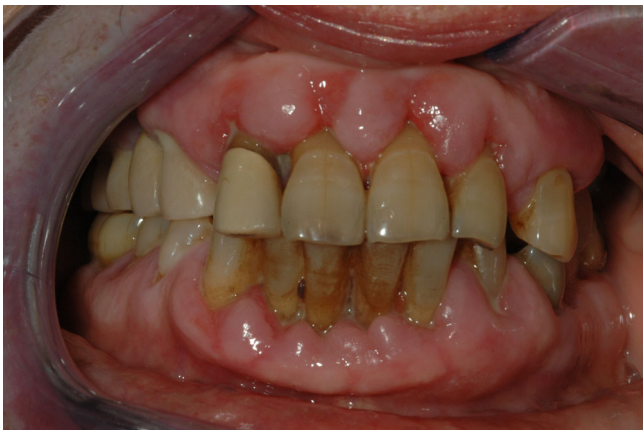The degree of thickening ranges from involvement of only the interdental papillae to gingival overgrowth covering the entire tooth crown. The gingival soft tissue overlying the alveolar ridge thickens. It may occur isolated, associated to orthodontic treatment (Zanatta, Ardenghi, Antoniazzi, Pinto, & Rosing, 2014), systemic treatment (Miranda et al., 2001), and generalized (Jaureguiberry et al., 2012). Gingival overgrowth can also be seen subsequently to external factors (phenytoin; cyclosporin A; nifediprin) or can be genetically determined. Gingival overgrowth can be caused by gingival hypertrophy and gingival hyperplasia, which can only be diagnosed using histological studies.

**Replaces term:** Gingival hyperplasia; Gingival hypertrophy

**Synonym:** Gingival overdevelopment; Gingiva, enlarged



**FIGURE 59** Overjet increased evident in the increase of horizontal distance between maxillary and mandibular teeth [Color figure can be viewed at [wileyonlinelibrary.com](http://wileyonlinelibrary.com)]



**FIGURE 60** Gingival overgrowth [Color figure can be viewed at [wileyonlinelibrary.com](http://wileyonlinelibrary.com)]

## 5 | NOSOLOGY OF GENETICALLY DETERMINED DENTAL DISORDERS

The presently proposed nosology of genetically determined dental disorders consists of 408 entities (Table 1). Dental non-developmental anomalies registered in OMIM, which are at least in part acquired, such as dental caries, are not included. Disorders going along with malocclusion of which the origin can be completely acquired to completely genetically determined, and which can be dental but also non-dental, are also excluded. Some disorders pertaining to a group are included, whereas other are not. For example, within the group of epidermolysis bullosa disorders, the dystrophica type is not included as its only associated dental sign is caries, but the junctional type is included as it goes along with enamel anomalies.

Each of the eight dental anomaly groups is subdivided into isolated and syndromic forms. Syndromes are grouped according to the recommendations for the grouping of rare disorders established by the European Reference Networks (Evangelista et al., 2016). Some syndromes go along with several different dental anomalies, such as Johanson-Blizzard syndrome with dental agenesis and severe microdontia. These disorders are classified in only one group, and other main dental phenotypes are added in the “notes” column. In 322 of the 408 disorders (79%), a gene is identified. In an additional 17 (4%), a candidate locus is known. The efforts made in establishing a common characterization of dental and craniofacial disorders, both isolated and syndromic, as well as in ascertaining their developmental and genetic common traits (for review: (Bloch-Zupan et al., 2012; Klein et al., 2013; Mitsiadis & Luder, 2011; Thesleff, 2014) are contributing to these high percentages. However, this percentage could not be linked to the genetic diagnostic rates in practice. Isolated orodontal disorders account for 53 of the 408 entities (13%), the remaining 87% are syndromes. In comparing the various dental anomalies, we find that dental agenesis is present in 121 disorders, supernumerary teeth in 18 disorders, dental size and/or shape disorders in 29 disorders, enamel anomalies in 105 disorders, dentin anomalies in 35 disorders, anomalies in dental eruption in 40 disorders, periodontal and gingival anomalies in 52 disorders, and tumor-like anomalies in eight disorders.

The development in sequencing techniques allowing to evaluate for variants in groups of genes causing specific signs or symptoms (NGS panel sequencing) has demonstrated that disorders initially described as occurring isolated could be allelic to syndromes, and vice versa. This is occurring in dental disorders as well. For example, variants in *EDA* were first described causing ectodermal dysplasia but were subsequently detected in individuals with dental agenesis without other signs of ectodermal dysplasia, and similar widening of phenotypes being caused by variants in single genes have been reported in several other genes such as *COL17A1*, *DLX3*, and *LAMA3* (Poulter et al., 2014; Prasad et al., 2016; Yang et al., 2013).

We hope that these clinical descriptions are useful in patient's care, especially in case of multi-disciplinary discussions. Dental anomalies are relevant clinical signs and may provide key clues for

differential diagnosis of rare disorders, and the present nosology may be helpful in this respect as well. The present nosology is the first comprehensive nosology in Dentistry. Undoubtedly, it will need regularly updating. Furthermore, we welcome remarks and criticisms by colleagues around the world to ameliorate both the definitions and the nosology.

D[4]/phenodent: [www.phenodent.org](http://www.phenodent.org)

Human Phenotype Ontology: [www.human-phenotype-ontology.org](http://www.human-phenotype-ontology.org)

ICD10-ICD11 MMS: Revised International Classification of Disorders for Mortality and <https://icd.who.int/dev11/l-m/en>

OMIM (Online Mendelian Inheritance in Man): <http://www.ncbi.nlm.nih.gov/omim/>

Orphanet: [www.orpha.net](http://www.orpha.net) (Rath et al., 2012).

## COLLABORATORS, INTERNATIONAL GROUP OF DENTAL NOMENCLATURE

Consortium from collaborative national “TÊTECOU” and O-Rares oral and dental rare disease network - French rare disorders Healthcare Network for rare disorders of the head, neck and teeth: Jean-Louis Sixou (Service d'Odontologie et de chirurgie buccale, CHU de Rennes), Hervé Foray (Service d'Odontologie et de chirurgie buccale, CHU de Brest), Béatrice Bonin-Goga (Service de Chirurgie maxillo-faciale, plastique de la face et stomatologie, CHRU Hôpitaux de TOURS, Hôpital Clocheville), Florent Sury, CHU Tours, Frédéric Vaysse (Service d'odontologie, CHU Toulouse, Hôpital Rangueil-Maraichers), Joël Ferri (Service d'odontologie et chirurgie maxillo-faciale, CHRU de Lille, Hôpital Roger Salengro), Corinne Tardieu (Pôle odontologie - Centre dentaire, Assistance Publique des Hôpitaux de Marseille, Hôpital de La Timone), Brigitte Alliot-Licht (Odontologie Conservatrice et Pédiatrique, CHU de Nantes, Site de l'Hôtel-Dieu), Jean-Jacques Morrier (Service de Consultations et Traitements Dentaires, Hospices Civils de Lyon, Hôpitaux Nord), Dominique Droz (CHU de Nancy, Service d'Odontologie, Nancy, France), Michèle Muller-Bolla (Département d'Odontologie Pédiatrique, UFR d'Odontologie, Université de Nice Sophia-Antipolis, CHU de Nice, Nice, France, 10URB2i - EA 4462, Paris Descartes, Paris, France), Séréna Lopez-Cazaux (Faculté de Chirurgie Dentaire, Département d'Odontologie Pédiatrique, CHU Hôtel Dieu, Service d'odontologie conservatrice et pédiatrique, Nantes, France), Isabelle Bailleul-Forestier (CHU de Toulouse, Odontologie Pédiatrique, Faculté de Chirurgie Dentaire, Université Paul Sabatier, Toulouse, France), Tiphaine Davit-Beal (Département d'Odontologie Pédiatrique, Faculté de Chirurgie Dentaire, Université Paris Descartes, Montrouge, France, Evolution et Développement du Squelette-EDS, UMR7138-SAE, Université Pierre et Marie Curie, Paris, France), Marie Paule Gelle (Faculté d'Odontologie, Université de Reims Champagne-Ardenne, 2 rue du Général Koenig, Reims 51100, France, Laboratoire EA 4691 “BIOS,” 1, rue du Maréchal Juin, Reims 51100, France), Louis Frédéric Jacquelin, (Faculté d'Odontologie, Université de Reims Champagne-Ardenne, 2 rue du Général Koenig, Reims 51100, France), Laboratoire EA 4691 “BIOS,” 1, rue du Maréchal Juin, Reims 51100, France,

Edouard Euvrard, (Centre hospitalier régional universitaire de Besançon—Site de Jean Minjot, CICIT unité INSERM 1431), Victorin Ahoosi, (CHU Dijon-Bourgogne Dijon, France).

Endorsing International Consortium (expert reviewing panel): Roger Hall (Australia), Richard Widmer (Australia), Anna Schossig (Austria), Ines Kapferer-Seebacher (Austria), Charles Pilipili (Belgium), Rose Mbede (Cameroun), Petra Hlinakova (Czech Republic), Maria-Angelica Quintana Torres (Chili), Jung Wook Kim (Corea), Hans Gjørup (Denmark), Dorte Haubek (Denmark), Satu Alaluusua (Finland), Priska Fischer (Germany), Anna Wolff (Germany), Marcel Hanisch (Germany), Nick A Lygidakis (Greece), Elia Sfeir, (Lebanon), Mustafa El Alloussi (Morocco), Ahmed Bilal (Pakistan), Carlalberta Verna (Switzerland), Eirini Stratigaki (Switzerland), Patimaporn Pungchanchaikul (Thailand), Supawich Morkmued (Thailand), Alan Mighell (UK), Susan Parek (UK), James K. Hartsfield (USA), Ophir Klein (USA); European Reference Network ERN CRANIO: Tatjana Dostalova (Czech Republic), Marjin Creton (The Netherlands), Edwin Ongkosuwito (The Netherlands), Jamila Ross (The Netherlands), Marie-José van den Boogaard (The Netherlands), and Peter Moosey (UK).

## CONTRIBUTORS

MDLD: Conception and design of the research, database analysis, draft and revision of the manuscript; BF: database analysis, draft and revision of the manuscript; MCM, ACA: draft and revision of the manuscript; LF: draft and revision of the manuscript; MLBL, ST, SK, PG, BVF, RF, MVB, LJ, FC: revision of the manuscript; MDC database analysis, draft and revision of the manuscript; ST: database analysis; MK database analysis; JC database analysis; AB draft and revision of the manuscript; ABZ: database analysis, draft and revision of the manuscript.

## ACKNOWLEDGMENTS


This initiative participates to the actions of the project No. 1.7 “RARENET: a trinational network for education, research and management of complex and rare disorders in the Upper Rhine” co-financed by the European Regional Development Fund (ERDF) of the European Union in the framework of the INTERREG V Upper Rhine program as well as to the ERN (European reference network) CRANIO initiative. BF is the holder of an INTERFACE contract, INSERM/APHP, which supported this study. We are grateful to la Fondation des “Gueules Cassées” who supported this research field and several authors research. ABZ is a USIAS 2015 Fellow of the Institute of Advanced Studies (Institut d'Etudes Avancées) de l'Université de Strasbourg, France. International Collaboration Capes-Cofecub Grant, Brazil and France (MDLD, ACA, AB). We thank Karen Niederreither for careful and critical reading of the manuscript. We are grateful to patients and their families for continuous support. We would like to acknowledge and pay tribute to Robert James Gorlin, Crispian Scully, Heddie Sedano, and Robin Winter for their invaluable contributions to the field. We assure no conflict of interest. The grant ANR-10-LABX-0030-INRT, a French State fund managed by the Agence Nationale de



la Recherche under the frame programme Investissements d'Avenir labelled ANR-10-IDEX-0002-02. This work was also funded by INSERM.

## ORCID

Muriel de La Dure-Molla  <https://orcid.org/0000-0003-3557-2845>

Benjamin Philippe Fournier  <https://orcid.org/0000-0003-4383-7524>

Raoul C. Hennekam  <https://orcid.org/0000-0002-6745-1522>

Ariane Berdal  <https://orcid.org/0000-0001-5833-5813>

Agnès Bloch-Zupan  <https://orcid.org/0000-0002-6511-2615>

## REFERENCES

- Allanson, J. E., Biesecker, L. G., Carey, J. C., & Hennekam, R. C. (2009). Elements of morphology: Introduction. *American Journal of Medical Genetics. Part A*, 149A(1), 2–5. <https://doi.org/10.1002/ajmg.a.32601>
- Angle, E. H. (1899). Classification of malocclusion. *The Dental Cosmos*, 41(3), 248–264.
- Arys, A., & Dourov, N. (1987). Enamel pearls in the deciduous teeth. *Journal de Biologie Buccale*, 15(4), 249–255.
- Axelsson, S. (2005). Variability of the cranial and dental phenotype in Williams syndrome. *Swedish Dental Journal. Supplement*, (170), 3–67.
- Baylis, S., & Bassed, R. (2017). Precision and accuracy of commonly used dental age estimation charts for the New Zealand population. *Forensic Science International*, 277, 223–228.
- Black, G. V. (1890). *Descriptive anatomy of the human teeth*. Philadelphia: Wilmington Dental manufacturing Company.
- Bloch-Zupan, A. (2004). Génétique: la contribution de l'odontologie. *Le chirurgien dentiste de France*, 1184, 30–35.
- Bloch-Zupan, A., Sedano, H., & Scully, C. (2012). *Dento/oro/craniofacial anomalies and genetics* (1st ed.). Boston, MA: Elsevier.
- Bot, P. L., & Salmon, D. (1977). Congenital defects of the upper lateral incisors (ULI): Condition and measurements of the other teeth, measurements of the superior arch, head and face. *American Journal of Physical Anthropology*, 46(2), 231–243. <https://doi.org/10.1002/ajpa.1330460204>
- Brusevold, I. J., Bie, T. M. G., Baumgartner, C. S., Das, R., & Espelid, I. (2017). Molar incisor malformation in six cases: Description and diagnostic protocol. *Oral Surgery, Oral Medicine, Oral Pathology, Oral Radiology*, 124(1), 52–61. <https://doi.org/10.1016/j.oooo.2017.03.050>
- Canese, K., & Weis, S. (2002). PubMed: The Bibliographic Database (Vol. <http://www.ncbi.nlm.nih.gov/pubmed/>).
- Carabelli, G. (1844). *Systemisches Handbuch der Zahnheilkunde*. Wien: Bei Braumuller und Seidel.
- Carey, J. C., Cohen, M. M., Jr., Curry, C. J., Devriendt, K., Holmes, L. B., & Verloes, A. (2009). Elements of morphology: Standard terminology for the lips, mouth, and oral region. *American Journal of Medical Genetics. Part A*, 149A(1), 77–92. <https://doi.org/10.1002/ajmg.a.32602>
- Chrcanovic, B. R., Abreu, M. H., & Custodio, A. L. (2010). Prevalence of enamel pearls in teeth from a human teeth bank. *Journal of Oral Science*, 52(2), 257–260.
- Evangelista, T., Hedley, V., Atalaia, A., Johnson, M., Lynn, S., Le Cam, Y., & Bushby, K. (2016). The context for the thematic grouping of rare diseases to facilitate the establishment of European reference networks. *Orphanet Journal of Rare Diseases*, 11, 17. <https://doi.org/10.1186/s13023-016-0398-y>
- FDI Director calls on more countries to adopt the FDI two-digit tooth-numbering system. (1988). *Journal of the Irish Dental Association*, 34(2), 49.
- Ferre, F. C., Frank, M., Gogly, B., Golmard, L., Naveau, A., Cherifi, H., ... Fournier, B. P. (2012). Oral phenotype and scoring of vascular Ehlers-Danlos syndrome: A case-control study. *BMJ Open*, 2(2), e000705. <https://doi.org/10.1136/bmjopen-2011-000705>
- Fournier, B. P., Bruneau, M. H., Toupenay, S., Kerner, S., Berdal, A., Cormier-Daire, V., ... de La Dure-Molla, M. (2018). Patterns of dental agenesis highlight the nature of the causative mutated genes. *Journal of Dental Research*, 97, 1316. <https://doi.org/10.1177/0022034518777460>
- Groza, T., Kohler, S., Moldenhauer, D., Vasilevsky, N., Baynam, G., Zemojtel, T., ... Robinson, P. N. (2015). The human phenotype ontology: Semantic unification of common and rare disease. *American Journal of Human Genetics*, 97(1), 111–124. <https://doi.org/10.1016/j.ajhg.2015.05.020>
- Hall, R. K. (1994). *Pediatric orofacial medicine and pathology* (C. a. H. M. s. edition). Great Britain: Chapman & Hall.
- Hall, R. K. (2006). Solitary median maxillary central incisor (SMMCI) syndrome. *Orphanet Journal of Rare Diseases*, 1, 12. <https://doi.org/10.1186/1750-1172-1-12>
- Hennekam, R., Allanson, J., & Krantz, I. (2010). *Gorlin's syndromes of the head and neck 5th edition* (5th ed.). USA: Oxford University Press.
- Hennekam, R. C., Biesecker, L. G., Allanson, J. E., Hall, J. G., Opitz, J. M., Temple, I. K., ... Elements of Morphology, C. (2013). Elements of morphology: General terms for congenital anomalies. *American Journal of Medical Genetics. Part A*, 161A(11), 2726–2733. <https://doi.org/10.1002/ajmg.a.36249>
- Herrera-Atoche, J. R., Aguayo-de-Pau, M. D., Escoffie-Ramirez, M., Aguilar-Ayala, F. J., Carrillo-Avila, B. A., & Rejon-Peraza, M. E. (2017). Impacted maxillary canine prevalence and its association with other dental anomalies in a Mexican population. *International Journal of Dentistry*, 2017, 7326061–7326064. <https://doi.org/10.1155/2017/7326061>
- Huckert, M., Stoetzel, C., Morkmued, S., Laugel-Hausalter, V., Geoffroy, V., Muller, J., ... Bloch-Zupan, A. (2015). Mutations in the latent TGF-beta binding protein 3 (LTBP3) gene cause brachyolmia with amelogenesis imperfecta. *Human Molecular Genetics*, 24(11), 3038–3049. <https://doi.org/10.1093/hmg/ddv053>
- Hulsmann, M. (1997). Dens invaginatus: Aetiology, classification, prevalence, diagnosis, and treatment considerations. *International Endodontic Journal*, 30(2), 79–90.
- Hunagasi, S., Koneru, A., Manvikar, V., Vanishree, M., & Amrutha, R. (2017). A rare case of twinning involving primary maxillary lateral incisor with review of literature. *Journal of Clinical and Diagnostic Research*, 11(2), ZD09–ZD11. <https://doi.org/10.7860/JCDR/2017/23510.9212>
- Issa, Y. A., Kamal, L., Rayyan, A. A., Dweik, D., Pierce, S., Lee, M. K., ... Kanaan, M. (2016). Mutation of KREMEN1, a modulator of Wnt signaling, is responsible for ectodermal dysplasia including oligodontia in Palestinian families. *European Journal of Human Genetics*, 24(10), 1430–1435. <https://doi.org/10.1038/ejhg.2016.29>
- Jaureguiberry, G., De la Dure-Molla, M., Parry, D., Quentric, M., Himmerkus, N., Koike, T., ... Kleta, R. (2012). Nephrocalcinosis (enamel renal syndrome) caused by autosomal recessive FAM20A mutations. *Nephron. Physiology*, 122(1–2), 1–6. <https://doi.org/10.1159/000349989>
- Jeong, K. H., Kim, D., Song, Y. M., Sung, J., & Kim, Y. H. (2015). Epidemiology and genetics of hypodontia and microdontia: A study of twin families. *The Angle Orthodontist*, 85(6), 980–985. <https://doi.org/10.2319/052814-376.1>
- Joiner, A., & Luo, W. (2017). Tooth colour and whiteness: A review. *Journal of Dentistry*, 67S, S3–S10. <https://doi.org/10.1016/j.jdent.2017.09.006>
- Kantaputra, P., Kaewgahya, M., Jotikasthira, D., & Kantaputra, W. (2014). Tricho-odonto-onycho-dermal dysplasia and WNT10A mutations. *American Journal of Medical Genetics. Part A*, 164A(4), 1041–1048. <https://doi.org/10.1002/ajmg.a.36388>

- Kantaputra, P. N., Kaewgahya, M., Hatsadaloi, A., Vogel, P., Kawasaki, K., Ohazama, A., & Ketudat Cairns, J. R. (2015). GREMLIN 2 mutations and dental anomalies. *Journal of Dental Research*, 94(12), 1646–1652. <https://doi.org/10.1177/0022034515608168>
- Kasat, V. O., Singh, M., Saluja, H., & Ladda, R. (2014). Coexistence of two talon cusps and two dens invaginatus in a single tooth with associated radicular cyst—a case report and review of literature. *Journal of Clinical and Experimental Dentistry*, 6(4), e430–e434. <https://doi.org/10.4317/jced.51421>
- Kim, J. W., Seymen, F., Lee, K. E., Ko, J., Yildirim, M., Tuna, E. B., ... Hu, J. C. (2013). LAMB3 mutations causing autosomal-dominant amelogenesis imperfecta. *Journal of Dental Research*, 92(10), 899–904. <https://doi.org/10.1177/0022034513502054>
- Kim, J. W., Zhang, H., Seymen, F., Koruyucu, M., Hu, Y., Kang, J., ... Hu, J. C. (2018). Mutations in RELT cause autosomal recessive amelogenesis Imperfecta. *Clinical Genetics*, 95, 375–383. <https://doi.org/10.1111/cge.13487>
- Kleigman, R. M., Behrman, R. E., Jenson, H. B., & Stanton, B. F. (2007). In P. S. E. Philadelphia (Ed.), *Nelson's textbook of pediatrics* (18th ed.). USA: Saunders.
- Klein, O. D., Oberoi, S., Huysseune, A., Hovorakova, M., Peterka, M., & Peterkova, R. (2013). Developmental disorders of the dentition: An update. *American Journal of Medical Genetics. Part C, Seminars in Medical Genetics*, 163C(4), 318–332. <https://doi.org/10.1002/ajmg.c.31382>
- de La Dure-Molla, M., Fournier, B., & Berdal, A. (2015). Isolated dentinogenesis imperfecta and dentin dysplasia: Revision of the classification. *European Journal of Human Genetics*, 23(4), 445–451. <https://doi.org/10.1038/ejhg.2014.159>
- Lagana, G., Venza, N., Borzabadi-Farahani, A., Fabi, F., Danesi, C., & Cozza, P. (2017). Dental anomalies: Prevalence and associations between them in a large sample of non-orthodontic subjects, a cross-sectional study. *BMC Oral Health*, 17(1), 62. <https://doi.org/10.1186/s12903-017-0352-y>
- Laugel-Haushalter, V., Morkmued, S., Stoetzel, C., Geoffroy, V., Muller, J., Boland, A., ... Pungchanchaikul, P. (2018). Genetic evidence supporting the role of the calcium channel, CACNA1S, in tooth cusp and root patterning. *Frontiers in Physiology*, 9, 1329. <https://doi.org/10.3389/fphys.2018.01329>
- Lavelle, C. L. (1972). Maxillary and mandibular tooth size in different racial groups and in different occlusal categories. *American Journal of Orthodontics*, 61(1), 29–37.
- Lunt, R. C., & Law, D. B. (1974). A review of the chronology of eruption of deciduous teeth. *Journal of the American Dental Association* (1939), 89(4), 872–879.
- Mallineni, S. K., Panampally, G. K., Chen, Y., & Tian, T. (2014). Mandibular talon cusps: A systematic review and data analysis. *Journal of Clinical and Experimental Dentistry*, 6(4), e408–e413. <https://doi.org/10.4317/jced.51476>
- McCreeedy, C., Robbins, H., Newell, A., & Mallya, S. M. (2016). Molar-incisor malformation: Two cases of a newly described dental anomaly. *Journal of Dentistry for Children*, 83(1), 33–37.
- McDonald, R. E., Avery, D. A., & Dean, J. A. (2004). In S. L. Mosby (Ed.), *Dentistry for the child and adolescent*. USA: Mosby.
- Mhaske, S., Yuwanati, M. B., Mhaske, A., Ragavendra, R., Kamath, K., & Saawarn, S. (2013). Natal and neonatal teeth: An overview of the literature. *ISRN Pediatrics*, 2013, 956269–956211. <https://doi.org/10.1155/2013/956269>
- Miranda, J., Brunet, L., Roset, P., Berini, L., Farre, M., & Mendieta, C. (2001). Prevalence and risk of gingival enlargement in patients treated with nifedipine. *Journal of Periodontology*, 72(5), 605–611. <https://doi.org/10.1902/jop.2001.72.5.605>
- Mitsiadis, T. A., & Luder, H. U. (2011). Genetic basis for tooth malformations: From mice to men and back again. *Clinical Genetics*, 80(4), 319–329. <https://doi.org/10.1111/j.1399-0004.2011.01762.x>
- Nanci, A. (2012). *Ten Cate's oral histology 8th edition, development, structure, and function*. USA: Mosby.
- Negre-Barber, A., Montiel-Company, J. M., Boronat-Catala, M., Catala-Pizarro, M., & Almerich-Silla, J. M. (2016). Hypomineralized second primary molars as predictor of molar incisor hypomineralization. *Scientific Reports*, 6, 31929. <https://doi.org/10.1038/srep31929>
- Nielsen, S. H., Becktor, K. B., & Kjaer, I. (2006). Primary retention of first permanent mandibular molars in 29 subjects. *European Journal of Orthodontics*, 28(6), 529–534. <https://doi.org/10.1093/ejo/cj1049>
- Papapanou, P. N., Sanz, M., Buduneli, N., Dietrich, T., Feres, M., Fine, D. H., ... Tonetti, M. S. (2018). Periodontitis: consensus report of workgroup 2 of the 2017 world workshop on the classification of periodontal and peri-implant diseases and conditions. *Journal of Periodontology*, 89(Suppl 1), S173–S182. <https://doi.org/10.1002/JPER.17-0721>
- Parry, D. A., Smith, C. E., El-Sayed, W., Poulter, J. A., Shore, R. C., Logan, C. V., ... Mighell, A. J. (2016). Mutations in the pH-sensing G-protein-coupled receptor GPR68 cause amelogenesis imperfecta. *American Journal of Human Genetics*, 99(4), 984–990. <https://doi.org/10.1016/j.ajhg.2016.08.020>
- Peck, S., & Peck, L. (1993). A time for change of tooth numbering systems. *Journal of Dental Education*, 57(8), 643–647.
- Peled, A., Sarig, O., Samuelov, L., Bertolini, M., Ziv, L., Weissglas-Volkov, D., ... Sprecher, E. (2016). Mutations in TSPEAR, encoding a regulator of notch signaling, affect tooth and hair follicle morphogenesis. *PLoS Genetics*, 12(10), e1006369. <https://doi.org/10.1371/journal.pgen.1006369>
- Pilz, P., Meyer-Marcotty, P., Eigenthaler, M., Roth, H., Weber, B. H., & Stelzig-Eisenhauer, A. (2014). Differential diagnosis of primary failure of eruption (PFE) with and without evidence of pathogenic mutations in the PTHR1 gene. *Journal of Orofacial Orthopedics*, 75(3), 226–239. <https://doi.org/10.1007/s00056-014-0215-y>
- Polder, B. J., Van't Hof, M. A., Van der Linden, F. P., & Kuijpers-Jagtman, A. M. (2004). A meta-analysis of the prevalence of dental agenesis of permanent teeth. *Community Dentistry and Oral Epidemiology*, 32(3), 217–226. <https://doi.org/10.1111/j.1600-0528.2004.00158.x> COM158 [pii].
- Poornima, P., Kirthiga, M., Sasalwad, S., & Nagaveni, N. B. (2016). Prevalence of a few variant dental features in children aged 11–16 years in Davangere, a city in Karnataka. *Journal of Forensic Dental Sciences*, 8(1), 13–17. <https://doi.org/10.4103/0975-1475.176948>
- Poulter, J. A., El-Sayed, W., Shore, R. C., Kirkham, J., Inglehearn, C. F., & Mighell, A. J. (2014). Whole-exome sequencing, without prior linkage, identifies a mutation in LAMB3 as a cause of dominant hypoplastic amelogenesis imperfecta. *European Journal of Human Genetics*, 22(1), 132–135. <https://doi.org/10.1038/ejhg.2013.76>
- Prasad, M. K., Geoffroy, V., Vicaire, S., Jost, B., Dumas, M., Le Gras, S., ... Bloch-Zupan, A. (2016). A targeted next-generation sequencing assay for the molecular diagnosis of genetic disorders with orodental involvement. *Journal of Medical Genetics*, 53(2), 98–110. <https://doi.org/10.1136/jmedgenet-2015-103302>
- Raghoobar, G. M., Boering, G., & Vissink, A. (1991). Clinical, radiographic and histological characteristics of secondary retention of permanent molars. *Journal of Dentistry*, 19(3), 164–170.
- Rath, A., Olry, A., Dhombres, F., Brandt, M. M., Urbero, B., & Ayme, S. (2012). Representation of rare diseases in health information systems: The Orphanet approach to serve a wide range of end users. *Human Mutation*, 33(5), 803–808. <https://doi.org/10.1002/humu.22078>
- Reston, E., Bervian, J., Kramer, P., Spiguel, M., Ferreira, S., & Closs, L. (2014). Esthetic rehabilitation of a patient with severe oligodontia. *Operative Dentistry*, 39(4), 339–344. <https://doi.org/10.2341/12-397-S>
- Seow, W. K., & Lai, P. Y. (1989). Association of taurodontism with hypodontia: A controlled study. *Pediatric Dentistry*, 11(3), 214–219.
- Seymen, F., Kim, Y. J., Lee, Y. J., Kang, J., Kim, T. H., Choi, H., ... Kim, J. W. (2016). Recessive mutations in ACPT, encoding testicular acid



- phosphatase, cause hypoplastic amelogenesis imperfecta. *American Journal of Human Genetics*, 99(5), 1199–1205. <https://doi.org/10.1016/j.ajhg.2016.09.018>
- Smith, C. E., Murillo, G., Brookes, S. J., Poulter, J. A., Silva, S., Kirkham, J., ... Mighell, A. J. (2016). Deletion of amelotin exons 3-6 is associated with amelogenesis imperfecta. *Human Molecular Genetics*, 25(16), 3578–3587. <https://doi.org/10.1093/hmg/ddw203>
- Tallon-Walton, V., Nieminen, P., Arte, S., Carvalho-Lobato, P., Ustrell-Torrent, J. M., & Manzanares-Cespedes, M. C. (2010). An epidemiological study of dental agenesis in a primary health area in Spain: Estimated prevalence and associated factors. *Medicina Oral, Patología Oral y Cirugía Bucal*, 15(4), e569–e574.
- Tallon-Walton, V., Manzanares-Cespedes, M. C., Carvalho-Lobato, P., Valdivia-Gandur, I., Arte, S., & Nieminen, P. (2014). Exclusion of PAX9 and MSX1 mutation in six families affected by tooth agenesis. A genetic study and literature review. *Medicina Oral, Patología Oral y Cirugía Bucal*, 19(3), e248–e254.
- Tan, T. Y., Aftimos, S., Worgan, L., Susman, R., Wilson, M., Ghedia, S., ... Peters, G. (2009). Phenotypic expansion and further characterisation of the 17q21.31 microdeletion syndrome. *Journal of Medical Genetics*, 46(7), 480–489. <https://doi.org/10.1136/jmg.2008.065391>
- Thesleff, I. (2014). Current understanding of the process of tooth formation: Transfer from the laboratory to the clinic. *Australian Dental Journal*, 59(Suppl 1), 48–54. <https://doi.org/10.1111/adj.12102>
- Tinoco, R. L., Lima, L. N., Delwing, F., Francesquini, L., Jr., & Daruge, E., Jr. (2016). Dental anthropology of a Brazilian sample: Frequency of non-metric traits. *Forensic Science International*, 258(102), e101–e105. <https://doi.org/10.1016/j.forsciint.2015.10.019>
- Tucker, A., & Sharpe, P. (2004). The cutting-edge of mammalian development; how the embryo makes teeth. *Nature Reviews. Genetics*, 5(7), 499–508. <https://doi.org/10.1038/nrg1380>
- Verma, N., Bansal, A., Tyagi, P., Jain, A., Tiwari, U., & Gupta, R. (2017). Eruption chronology in children: A cross-sectional study. *International Journal of Clinical Pediatric Dentistry*, 10(3), 278–282. <https://doi.org/10.5005/jp-journals-10005-1450>
- Weerheijm, K. L. (2003). Molar incisor hypomineralisation (MIH). *European Journal of Paediatric Dentistry*, 4(3), 114–120.
- Witkop, C. J., Jr. (1988). Amelogenesis imperfecta, dentinogenesis imperfecta and dentin dysplasia revisited: Problems in classification. *Journal of Oral Pathology*, 17(9–10), 547–553.
- Xiong, F., Ji, Z., Liu, Y., Zhang, Y., Hu, L., Yang, Q., ... Xu, X. (2017). Mutation in SSUH2 causes autosomal-dominant dentin dysplasia type I. *Human Mutation*, 38(1), 95–104. <https://doi.org/10.1002/humu.23130>
- Yamunadevi, A., Selvamani, M., Vinitha, V., Srivandhana, R., Balakrithiga, M., Prabhu, S., & Ganapathy, N. (2015). Clinical evaluation of nonsyndromic dental anomalies in Dravidian population: A cluster sample analysis. *Journal of Pharmacy and Bioallied Sciences*, 7(Suppl 2), S499–S503. <https://doi.org/10.4103/0975-7406.163517>
- Yang, Y., Luo, L., Xu, J., Zhu, P., Xue, W., Wang, J., ... Su, L. (2013). Novel EDA p.Ile260Ser mutation linked to non-syndromic hypodontia. *Journal of Dental Research*, 92(6), 500–506. <https://doi.org/10.1177/0022034513487557>
- Yang, Q., Chen, D., Xiong, F., Chen, D., Liu, C., Liu, Y., ... Xu, X. (2016). A splicing mutation in VPS4B causes dentin dysplasia I. *Journal of Medical Genetics*, 53(9), 624–633. <https://doi.org/10.1136/jmedgenet-2015-103619>
- Yeluri, G., Kumar, C. A., & Raghav, N. (2015). Correlation of dental pulp stones, carotid artery and renal calcifications using digital panoramic radiography and ultrasonography. *Contemporary Clinical Dentistry*, 6 (Suppl 1), S147–S151. <https://doi.org/10.4103/0976-237X.166837>
- Zanatta, F. B., Ardenghi, T. M., Antoniazzi, R. P., Pinto, T. M., & Rosing, C. K. (2014). Association between gingivitis and anterior gingival enlargement in subjects undergoing fixed orthodontic treatment. *Dental Press Journal of Orthodontics*, 19(3), 59–66.

## SUPPORTING INFORMATION

Additional supporting information may be found online in the Supporting Information section at the end of this article.

**How to cite this article:** de La Dure-Molla M, Fournier BP, Manzanares MC, et al. Elements of morphology: Standard terminology for the teeth and classifying genetic dental disorders. *Am J Med Genet Part A*. 2019;179A:1913–1981. <https://doi.org/10.1002/ajmg.a.61316>