

See discussions, stats, and author profiles for this publication at: <https://www.researchgate.net/publication/265335134>

# Varicella pneumonia associated with spontaneous popliteal arterial thrombosis in an adult: a case study and review of the literature

Article in *JMM Case Reports* · August 2014

DOI: 10.1099/jmmcr.0.003640

CITATIONS

0

READS

77

5 authors, including:



Alex Smithson

La Fundacio Hospital de l' Esperit Sant

58 PUBLICATIONS 711 CITATIONS

[SEE PROFILE](#)



Javi Ramos

La Fundacio Hospital de l' Esperit Sant

31 PUBLICATIONS 172 CITATIONS

[SEE PROFILE](#)

Some of the authors of this publication are also working on these related projects:



Hidroneumotórax en paciente con enfisema bulloso [View project](#)



Debilidad muscular aguda en urgencias [View project](#)

## Case Report

# Varicella pneumonia associated with spontaneous popliteal arterial thrombosis in an adult: a case study and review of the literature

Alex Smithson,<sup>1</sup> Jessica Ruiz,<sup>2</sup> Xavi Ramos,<sup>2</sup> Esther Niño<sup>2</sup> and Fernando Armestar<sup>3</sup>

### Correspondence

Alex Smithson  
asa30412@hotmail.com

<sup>1</sup>Emergency Department, Fundació Hospital de l'Esperit Sant, Santa Coloma Gramenet, Spain

<sup>2</sup>Internal Medicine Department, Fundació Hospital de l'Esperit Sant, Santa Coloma de Gramenet, Spain

<sup>3</sup>Intensive Care Unit, Hospital Universitari Germans Tries i Pujol, Badalona, Spain

**Introduction:** Chickenpox is generally a childhood exanthematic benign self-limited disease. In contrast, most complications and fatal cases occur among adults, which is the group that suffers less commonly from this disease. The frequency of chickenpox in adults is increasing worldwide, together with the associated complications, mainly varicella pneumonia, which can lead to death. The incidence of other complications such as peripheral artery thrombosis is much lower but can cause important morbidity.

**Case presentation:** We report the case of a 63-year-old male smoker, who was otherwise previously healthy, who was admitted to the Emergency Department with chickenpox and varicella pneumonia with respiratory insufficiency requiring mechanical ventilation and intensive care unit admission. During hospitalization, the patient developed spontaneous popliteal artery thrombosis that finally led to transfemoral amputation.

**Conclusions:** Varicella pneumonia and peripheral artery thrombosis are two of the known complications of chickenpox. Both complications seem to be much more frequent in men with an active smoking habit. Clinicians should be aware of these complications in order to recognize them promptly and provide adequate treatment.

**Keywords:** arterial thrombosis; chickenpox; pneumonia; varicella-zoster virus.

Received 4 July 2014

Accepted 8 August 2014

## Introduction

Varicella-zoster virus (VZV) is an enveloped dsDNA virus that belongs to the family *Herpesviridae*. VZV primary infection leads to chickenpox or varicella, an exanthematic disease typical of childhood (Gershon & Gershon, 2013). Despite chickenpox being an infrequent disease in adults, most complications and fatal cases are seen in adulthood (Tunbridge & Breuer, 2008). Here, we present the clinical case of an adult who developed extensive chickenpox complicated with varicella pneumonia and a peripheral ischaemia.

## Case report

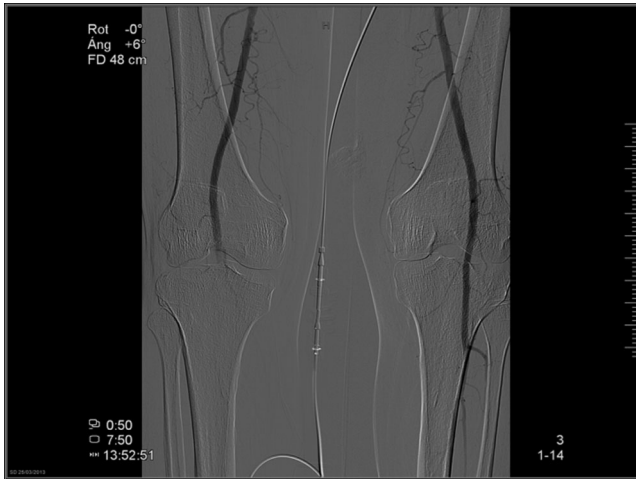
A 63-year-old male active smoker with a medical history of hypertension and diabetes mellitus was admitted because of varicella pneumonia. Treatment with acyclovir and non-invasive mechanical ventilation was started. After 48 h, he

presented acute symptoms of arterial ischaemia of the right lower limb, and treatment with intravenous heparin and prostaglandins was initiated. Arteriography showed a non-occlusive thrombus in the right common iliac artery and occlusion of the popliteal artery, without evident atherosclerotic disease (Fig. 1). A transfemoral embolectomy was carried out with extraction of embolic material and evidence of distal thrombosis. Despite medical treatment, he required transfemoral amputation of the right lower limb 12 days after onset of the ischaemic symptoms.

## Discussion

Our patient presented a spontaneous peripheral arterial thrombosis, which we believe was associated with the VZV infection. VZV is one of the few viruses that shows tropism for the endothelium and the only one with a demonstrated ability to replicate in endothelial cells, mainly in cerebral arteries. The relationship between VZV and cerebrovascular disease has been clearly established. It is the most

Abbreviations: VZV, varicella-zoster virus.



**Figure 1.** Lower limb angiography showing occlusion of the right popliteal artery.

common cause of ischaemic stroke in children and occurs with less frequency in adults (Gilden *et al.*, 2009). In a recent study, it was observed that children who experience chickenpox have a fourfold increased risk of stroke in the subsequent 6 months (Thomas *et al.*, 2014). VZV can also cause aneurysms, cerebral or subarachnoid haemorrhage, vascular ectasias and carotid artery dissection (Gilden *et al.*, 2009).

Despite the predominant preference of VZV for cerebral arteries, it can also affect, although with much less frequency, peripheral arteries with a clear predilection for the lower limbs. After reviewing the literature using PubMed, we found only four cases of peripheral thrombosis associated with chickenpox in healthy adults, and all of them involved the lower limbs (Limb & Binning, 2009; Massano *et al.*, 2008; Peyton *et al.*, 1998). The main characteristics of these cases and our own case are summarized in Table 1. All the cases were male, generally smokers, with chickenpox complicated with varicella pneumonia, without prior history of peripheral vascular disease, who developed lower limb ischaemic symptoms between 2 and 8 days from the onset of chickenpox cutaneous symptoms. Three of the four patients in which a complete coagulation study was carried out had abnormalities causing a hypercoagulable state. Our patient had in common with the previous published cases the fact that he was smoker without known peripheral vascular disease and that the peripheral arterial thrombosis appeared in association with varicella pneumonia.

The origin of this complication is unknown, although it has been suggested that it is mediated by autoantibodies induced by the VZV infection and directed against proteins involved in the coagulation pathway. It is well known that chickenpox is a risk factor for thrombophilic disorders in children, including purpura fulminans, deep-vein thrombosis and

**Table 1.** Characteristics of published cases of chickenpox associated with peripheral arterial thrombosis and our own case

Reference	Age (years)/sex	Smoker	Comorbidities	VZV symptoms	Days from rash to limb ischaemia	Artery thrombosis location	Coagulopathy	Limb evolution/outcome
Massano <i>et al.</i> (2008)	39/M	Yes	None	R, stroke, central retinal artery thrombosis	7	Left femoral and common iliac and right femoral	Low protein S; anticardiolipin IgM; anti β2-glycoprotein I IgM	Retain/recovery
Limb & Binning (2009)	38/M	Unknown	None	R, VP	2	Left limb. No additional information	Not found	Amputation/recovery
Peyton, <i>et al.</i> (1998)	47/M	No	None	R, VP	8	Bilateral femoral and tibial	Low S protein; lupus anticoagulant	Retained/death
Peyton, <i>et al.</i> (1998)	37/M	Yes	DM, Hta	R, VP	5	Left femoral and tibial	Low S protein; antiphospholipid antibodies	Retained/recovery
Present case	63/M	Yes	DM, Hta	R, VP	9	Right common iliac and popliteal artery	Not evaluated	Amputation/recovery

M, male; DM, diabetes mellitus; Hta, Hypertension; R, rash; VP, varicella pneumonia.

pulmonary embolism (Raffini *et al.*, 2009). Low protein S and protein C levels, autoantibodies directed against phospholipids, and coagulation proteins and lupus anti-coagulant have been detected in children with chickenpox, particularly in those who develop thrombophilic disorders (Ferrara *et al.*, 2013; Josephson *et al.*, 2001). In the case we have presented, the levels of protein S or lupus anti-coagulant or other pro-coagulant factors were not measured as the ischaemic complication was not thought to be related to a thrombophilic state induced by the VZV infection.

In summary, chickenpox in adults, even in those who are previously healthy, is a life-threatening infectious disease with a significant number of potential and serious complications such as spontaneous arterial thrombosis. Clinicians should be well aware of these to provide early recognition and optimal therapeutic management.

## References

- Ferrara, M., Bertocco, F., Ferrara, D. & Capozzi, L. (2013). Thrombophilia and varicella zoster in children. *Hematology* **18**, 119–122.
- Gershon, A. A. & Gershon, M. D. (2013). Pathogenesis and current approaches to control of varicella-zoster virus infections. *Clin Microbiol Rev* **26**, 728–743.
- Gilden, D., Cohrs, R. J., Mahalingam, R. & Nagel, M. A. (2009). Varicella zoster vasculopathies: diverse clinical manifestations, laboratory features, pathogenesis, and treatment. *Lancet Neurol* **8**, 731–740.
- Josephson, C., Nuss, R., Jacobson, L., Hacker, M. R., Murphy, J., Weinberg, A. & Manco-Johnson, M. J. (2001). *Pediatr Res* **50**, 345–352.
- Limb, J. & Binning, A. (2009). Thrombosis associated with varicella zoster in an adult. *Int J Infect Dis* **13**, 498–500.
- Massano, J., Ferreira, D., Toledo, T., Mansilha, A., Azevedo, E. & Carvalho, M. (2008). Stroke and multiple peripheral thrombotic events in an adult with varicella. *Eur J Neurol* **15**, 90–91.
- Peyton, B. D., Cutler, B. S. & Stewart, F. M. (1998). Spontaneous tibial artery thrombosis associated with varicella pneumonia and free protein S deficiency. *J Vasc Surg* **27**, 563–567.
- Raffini, L., Huang, Y. S., Witmer, C. & Feudtner, C. (2009). Dramatic increase in venous thromboembolism in children's Hospital in the United States from 2001 to 2007. *Pediatrics* **124**, 1001–1008.
- Thomas, S. L., Minassian, C., Ganesan, V., Langan, S. & Smeeth, L. (2014). Chickenpox and risk of stroke: a self-controlled case series analysis. *Clin Infect Dis* **58**, 61–68.
- Tunbridge, A. J., Breuer, J. & Jeffery, K. J. (2008). Chickenpox in adults - clinical management. *J Infect* **57**, 95–102.