



## Tumour Review

# From genetics to therapy: Unraveling the complexities of Richter transformation in chronic lymphocytic leukemia

Pau Abrisqueta<sup>a,b</sup>, Ferran Nadeu<sup>c,d</sup>, Jan Bosch-Schips<sup>e</sup>, Gloria Iacoboni<sup>a,b</sup>, Angel Serna<sup>a,b</sup>, Alba Cabirta<sup>a,b</sup>, Lucrecia Yáñez<sup>f</sup>, Leticia Quintanilla-Martínez<sup>g</sup>, Francesc Bosch<sup>a,b,\*</sup>

<sup>a</sup> Department of Hematology, Vall d'Hebron Hospital Universitari, Experimental Hematology, Vall d'Hebron Institute of Oncology (VHIO), Vall d'Hebron Barcelona Hospital Campus, Passeig Vall d'Hebron 119-129, 08035 Barcelona, Spain

<sup>b</sup> Departament de Medicina, Universitat Autònoma de Barcelona, 08193 Bellaterra, Spain

<sup>c</sup> Institut d'Investigacions Biomèdiques August Pi i Sunyer (IDIBAPS), 08036 Barcelona, Spain

<sup>d</sup> Centro de Investigación Biomédica en Red de Cáncer (CIBERONC), Madrid, Spain

<sup>e</sup> Department of Pathology, Hospital Universitari de Bellvitge-Bellvitge Biomedical Research Institute (IDIBELL), L'Hospitalet de Llobregat, 08907 Barcelona, Spain

<sup>f</sup> Department of Hematology, Hospital Universitario Marqués de Valdecilla, Santander, Spain

<sup>g</sup> Institute of Pathology and Neuropathology, Tübingen University Hospital and Comprehensive Cancer Center Tübingen-Stuttgart, 72076 Tübingen, Germany

## ARTICLE INFO

## Keywords:

Chronic lymphocytic leukemia  
Richter's transformation  
Clonal evolution

## ABSTRACT

Richter transformation (RT) refers to the progression of chronic lymphocytic leukemia, the most prevalent leukemia among adults, into a highly aggressive lymphoproliferative disorder, primarily a diffuse large B-cell lymphoma. This is a severe complication that continues to be a therapeutic challenge and remains an unmet medical need. Over the last five years, significant advances have occurred in uncovering the biological processes leading to the RT, refining criteria for properly diagnose RT from other entities, and exploring new therapeutic options beyond the ineffective chemotherapy. This review summarizes current knowledge in RT, including recent advances in the understanding of the pathogenesis of RT, in the classification of RT, and in the development of novel therapeutic strategies for this grave complication.

## Introduction

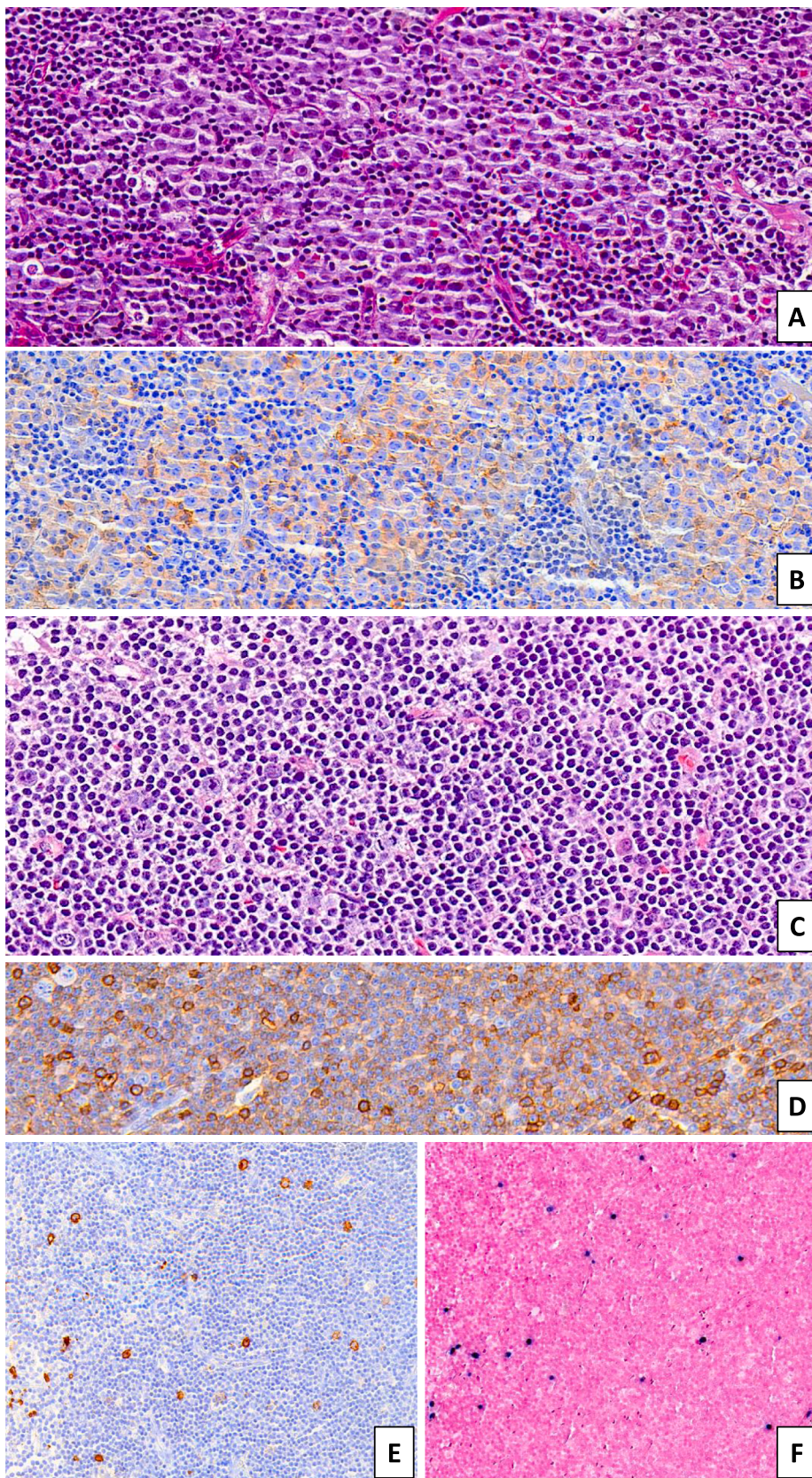
With an estimated incidence of 4.7 new cases per 100,000 individuals, chronic lymphocytic leukemia (CLL) is the most common form of chronic leukemia in the USA and in Europe [1]. In 1928, Dr. Maurice N. Richter described a clinical case of a male diagnosed with CLL who developed constitutional symptoms. The enlarged lymph nodes found in the necropsy were diagnosed with a reticular cell sarcoma [2]. Since then, the occurrence of an aggressive lymphoma in patients with a previous or concurrent diagnosis of CLL has been termed Richter transformation (RT), a nosological entity recognized in the World Health Organization (WHO) and the International Consensus Classification (ICC) [3–5]. RT is a rare complication of CLL that occurs at a rate of approximately 0.5%–1% per year [6], being more frequent in patients in whom the underlying CLL present particular high-risk biological features, including *TP53* gene aberrations, the use of stereotyped subset #8 of immunoglobulin heavy variable (IGHV) genes, or mutations in the *NOTCH1* gene [7–10]. The great majority of patients with RT have

histology of diffuse large B-cell lymphoma (DLBCL), clonally related to the underlying CLL in 70–80% of cases [8,11]. Less commonly, RT results from the transformation of CLL into Hodgkin lymphoma or exceedingly rare histologies [3,12–15]. DLBCL-type RT usually display a non-germinal center B-cell phenotype and disclose a pattern of recurrent genetic abnormalities that differ from the ones observed in *de novo* DLBCL [7,16–18]. Notably, by combining genomic and transcriptome with single-cell sequencing analysis it has been found that minute sub-clones carrying biological characteristics of RT cells might be already present at the diagnosis of CLL [17].

Owing to the underlying CLL affecting elderly individuals, the genetic profile, the aggressiveness of the disease, and treatment resistance, DLBCL-type RT is classically associated with a dismal outcome [8,19,20]. Several prognostic variables have been correlated with the clinical course, including the presence of *TP53* gene abnormalities, the number of lines of treatment prior the diagnosis of RT, and the clonal relationship between CLL and RT, having the clonally related RT a more aggressive clinical course [8,19,20].

\* Corresponding author at: Department of Hematology, University Hospital Vall d'Hebron, Psg Vall d'Hebron 119-129, 08035 Barcelona, Spain.  
E-mail address: [fbosch@vhio.net](mailto:fbosch@vhio.net) (F. Bosch).





**Fig. 1.** (A) Diffuse large B-cell lymphoma (DLBCL)-type Richter transformation (RT) in a 66-year-old female patient with a previous history of chronic lymphocytic leukemia (CLL). Biopsy shows a diffuse sheet of atypical large cells with high nucleus-to-cytoplasm ratio and conspicuous nucleoli. Partial PD-1 expression in the transformed large cells supports a clonal relationship to her known disease (B). (C) This other example shows a Hodgkin lymphoma (HL)-type RT type 1 in a 73-year-old male with prior CLL and clinically suspected disease progression. Biopsy shows Hodgkin and Reed-Sternberg (HRS) cells with bright red nucleoli in a background of CD5-positive (D) and CD23-positive CLL (not shown). HRS cells are positive for CD30 (E), CD15 (not shown) and EBER-ISH (*Epstein-Barr encoding region-in situ hybridization*) (F) [Original magnification: (A):  $\times 400$ ; (B):  $\times 400$ ; (C–D):  $\times 630$ ; (E–F):  $\times 200$ ]. Images courtesy of Dr. Fina Climent.



Treatment of patients with RT remains an unmet medical need. It usually relays on chemoimmunotherapy regimens commonly employed in patients with *de novo* DLBCL, particularly R-CHOP-like therapies, with disappointing results [20–22]. More intensive chemotherapy regimens using fractionated cyclophosphamide such as hyper-CVAD or platinum-based combinations have also shown very limited efficacy and an unbearable hematological and infectious toxicity [23–25]. The unsatisfactory results achieved with conventional chemotherapies led to the use of consolidation strategies with stem-cell transplantation (SCT) that prove to be active in a limited number of selected patients [26–28]. Finally, new approaches employing novel targeting therapies, such as check-point inhibitors, BCL-2 or B-cell receptor (BCR) inhibitors, T-cell engagers and CAR-T treatments, either alone or in different combinations, are currently under investigation with promising results [29–35].

Over the past five years, significant advancements have been made in the comprehension of the biology, pathogenesis, and treatment of RT. In this review, we will examine the recent discoveries in (epi)genetic features that contribute to the development of RT, the current histological classification system, and the therapeutic strategies being developed to address this unmet medical need.

### Epidemiology and risk factors

Although RT is an uncommon event, a proportion of CLL patients ranging from 2 to 10 % may experience an aggressive histological transformation. This variation in prevalence can be attributed to factors such as difficulties in the diagnosis as well as the characteristics of the specific patient population under study [6,20,36–38]. Large single-center population-based studies such as reported by M.D. Anderson Cancer Center or Mayo Clinic CLL Database communicated a frequency of biopsy-proven RT of 148/3986 (3.7 %) and 37/1641 (2.3 %) in CLL patients, with an incidence at 5 and 10 years post-CLL diagnosis of 2.1 % and 4.8 % respectively, and an annual incidence rate of 0.5 % per year in the latter series [6,20]. In contrast, larger data from the SEER database on 74,116 patients with CLL reported 530 patients that developed a RT (0.7 %) [37].

The occurrence of RT with respect to diverse therapeutic options for CLL remains a subject of ongoing debate. Several studies have suggested a higher incidence of RT among highly pretreated relapsed/refractory (R/R) CLL patients [39]. The Mayo Clinic CLL Database study reported an increasing rate of RT in those patients who had received treatment for their CLL (1 % per year, incidence at 5-years of 5.0 %, and at 10-years of 15.2 %) [6]. More recently, the German CLL Study Group (GCLLSG) identified 103 RT cases among 2975 (3.5 %) patients with CLL enrolled in front-line trials with chemo- or chemoimmunotherapy of the Group with a 3 and 12-year incidence of 2.1 % and 8.2 %, respectively [40].

It is worth to note that a substantial percentage of patients exhibits RT prior to receiving therapy for CLL. This is evidenced by the 28 % of RT cases reported by centers of the Spanish Chronic Lymphocytic Leukemia Study Group (GELLC) and the 46 % of the patients from the Mayo Clinic CLL Database, who had developed RT prior to the initiation of CLL treatment. These findings suggest the presence of inherent biological risk factors for RT that are independent of therapy [6,19].

Several clinical and biological characteristics have been identified as being associated with an increased risk of RT, including advance Binet/Rai stage, high-risk genetic features such as *TP53* gene abnormalities and complex karyotype (CK), unmutated IGHV status, stereotyped subset #8, and mutations in *NOTCH1* [6,9,10,16,41,42]. Additionally, *NOTCH1* mutations are a frequent genetic lesion that occurs during transformation, further emphasizing their association with RT. Furthermore, a multicenter retrospective study found that CLL patients with CK at diagnosis, particularly in those harboring high-CK (five or more chromosome abnormalities) or those with major structural abnormalities, had a 10-years incidence rate of RT of 31 % [42].

### Diagnosis and pathological features

The current gold standard for diagnosis of RT is the biopsy of an affected lymph node or involved extranodal site [1,43,44]. (Fig. 1) Since RT onset is usually neither disseminated nor simultaneous in all lymphatic regions, the decision whether to biopsy patients with clinical suspicion of RT – as well as the choice of optimal site for biopsy – is aided by imaging studies with fluorodeoxyglucose (18FDG) positron emission tomography (PET)/computed tomography (CT) [45–48], (discussed later).

Histopathological diagnosis of RT is challenging due to the lack of clear-cut histological criteria to differentiate DLBCL-type RT from other morphological mimics, mainly accelerated/progressed chronic lymphocytic leukemia (a/pCLL) or *de-novo* DLBCL [45]. The existence of rare transformations and morphological changes imitating transformation in the setting of treatment with novel agents, as well as laborious comparative clonality analysis conducted in small needle biopsies, only add to the complexity of diagnosis [49,50]. Furthermore, owing that RT may have heterogenous or admixed involvement within affected lymph nodes, diagnosis should be ideally performed from an excisional biopsy [51,52].

#### Pathological features of DLBCL-type RT

DLBCL-type RT is morphologically characterized by diffuse, confluent sheets of large neoplastic B-cells [1,8,53], and should meet the 2017 WHO histological criteria: [1] presence of large B lymphocytes with nuclear sizes equal to the nucleus of macrophages or at least more than twice that of a normal lymphocyte, and [2] evident diffuse growth pattern, not only as isolated foci - though admixed growth patterns have been reported. Most cases have centroblastic features (60–80 %), whereas immunoblastic (20 %–40%) and anaplastic features are less frequent [9,11]. DLBCL-type RT shows marked effacement of the affected lymph node, bone marrow or extranodal site but, not uncommonly, involvement can be partial and adjacent residual CLL/small lymphocytic lymphoma (SLL) may be seen. Other accepted findings are starry-sky pattern, necrosis, numerous apoptotic bodies and mitotic figures, and marked extracapsular extension of the large cell component.

DLBCL-type RT expresses B-cell markers CD19, CD20, CD79a, PAX5 and CD22, with inconsistent expression of typical CLL/SLL markers CD5 (30 %) and CD23 (15 %) [6,11,54]. Positivity for CD38, CD49d and ZAP70 is usually seen, and monotypic surface immunoglobulin light chains are detectable [55]. Immunophenotypically, 90 % of cases are of post-germinal center phenotype (IRF4/MUM1 positivity) [7,11,56]. *MYC* overexpression is detected in 30–40 % of cases, in which *MYC* translocations are also found [52,53,57]. *BCL2* is positive in up to 80 % of cases of DLBCL-type RT, but these do not harbor *BCL2* translocations nor somatic mutations, which are much more often found in *de novo* DLBCL [16,58]. Similarly, *BCL6* translocations are rare in DLBCL-type RT but are routinely present in *de novo* DLBCL, and can be useful in their differential [11,44,59]. Programmed cell death 1 (PD-1) expression, a distinguishing feature, in neoplastic B-cells is remarkably upregulated and expressed in 80 % of clonally related DLBCL-type RT, but is rare in *de novo* DLBCL and CLL/SLL. Thus, high levels of PD-1 expression in tumor cells could be a potential surrogate supporting clonal relationship of DLBCL-type RT with prior CLL/SLL [60,61]. Ki-67 proliferative index is high (>70 %) [62,63] and *TP53* overexpression is also common [56]. Cases are mostly negative for Epstein-Barr virus (EBV) [6,8,11], with the rare exception of EBV-associated large B-cell lymphoma arising during treatment with alemtuzumab (anti-CD52 antibody), resembling lymphomas occurring in immunodeficiency settings [64,65].

Clonally related DLBCL-type RT accounts for 80 % of cases and carries a poor prognosis, whereas clonally unrelated transformation mirrors *de novo* DLBCL outcome [7,8,16,43,66]. Clonality relationship analysis should be compared with circulating CLL cells or, if

unavailable, with adjacent CLL/SLL in tissue [50].

#### *Pathological features of Hodgkin lymphoma-type RT*

Hodgkin lymphoma-type RT (HL-type RT) is rare and accounts for 5–10 % of cases of transformation [1,67,68]. HL-type RT can be distinguished into two histological patterns: Type 1 consists of scattered Hodgkin Reed-Sternberg cells in a background of CLL/SLL (HRS-CLL), whereas Type 2 represents the overt transformation from CLL to Hodgkin lymphoma (cHL-CLL) with HRS cells amidst an accompanying polymorphous inflammatory background – usually resembling mixed cellularity variant – that is clearly segregated from adjacent CLL [6,8,9,11,69,70]. The HRS cells have a classical cHL immunohistochemical profile, with positivity for CD30 (100 %), CD15 (100 %) and PAX5 (88 %) [6,11,69]. CD20 expression is variably positive (49 %) and weak [69]. Of note, HRS-like cells in CLL with intense CD20 expression, CD30 positivity but lack of CD15 probably represent immunoblasts and should not qualify for HRS-CLL [52,69]. Altogether, HL-type RT is clonally related to CLL/SLL in 30–40 % of cases: 29 % of HRS-CLL and 53 % of cHL-CLL [8,69]. The clinical impact of the clonal relationship status in HL-type RT is still not well determined due to the limited available data [69,71]. Finally, the largest series up to date found HRS-CLL and cHL-CLL co-existing in some patients, which suggests that both lesions may represent a biologic continuum [71] and that HRS-CLL progresses to cHL-CLL in some patients [69,71].

#### *Rare variants of RT*

Other unusual variants (<1 %) of RT that are well documented are: (i) plasmablastic lymphoma [13,56,72–74], (ii) B-lymphoblastic leukemia/lymphoma [75–78] and (iii) histiocytic and interdigitating dendritic cell sarcomas [79–82]. In many of the small series and case reports, clonal relationship with underlying CLL/SLL was demonstrated. Currently, prolymphocytic transformation of CLL/SLL is not regarded as a variant of RT.

#### *Morphological mimics of Richter transformation*

##### *Accelerated/progressed CLL*

The term accelerated/progressed (a/p) CLL coins a rare histological variant of CLL/SLL usually associated with clinically aggressive behavior and with a median survival intermediate between typical CLL/SLL and RT [1,6,46,53,63]. Aggressive/progressed CLL commonly mimics RT and morphological boundaries can be blurred [51]. Misclassification happens in up to 18 % of cases, so it is recommended that the diagnosis be made by an expert hematopathologist [53,83]. Namely, a/pCLL consists of biopsy-proven expanded proliferation centers with an increase in large cells – usually paraimmunoblasts – and increased proliferative rate, but with insufficient criteria for a diagnosis of RT [1,53,63,84,85]. Histological features that may also help to refrain from diagnosing a/pCLL as RT are: (i) minimal and distinct preservation of proliferation centers and vague nodularity pattern, (ii) absence of confluent, diffuse sheets of large cells effacing tissue, (iii) an increased proliferative rate and mitotic activity, but lower than what is generally expected in RT (around 70–80 %).

##### *Pseudo-Richter/Richter-like transformation*

Recent publications have drawn attention to rare reversible Richter-like large cell proliferations arising in patients who have temporarily stopped treatment with ibrutinib [5,86,87]. It has been proposed to call such cases “Pseudo-Richter” [87] or “Richter-like” [5] transformation. These pose a severe diagnostic challenge because they can be indistinguishable from a DLBCL-type RT. Published series are limited to draw generalized conclusions, but “Pseudo-Richter” transformation usually consists of a diffuse large B-cell proliferation of non-germinal center phenotype, with a high Ki-67 proliferative index (>80 %). Interestingly,

it seems that most cases have a variably preserved expression of CD5 and CD23, and a strong LEF-1 expression, which are not typical features of DLBCL-type RT. No *MYC* gene rearrangements were detected by fluorescence in situ hybridization (FISH) [86,87]. In a small case series, all three patients had unmutated IGHV genes, *TP53* mutation and mostly abundant tumor cell PD-1 expression, findings typically found in DLBCL-type RT that also support clonal relationship with underlying CLL/SLL [86]. Thus, in the setting ibrutinib stoppage a diagnosis of DLBCL-type RT should be made warily, as these patients respond well to ibrutinib reinitiation. Even so, diagnosis and management should be thoroughly reevaluated after resuming treatment [5].

##### *Herpes simplex virus (HSV) lymphadenitis*

CLL/SLL B-cells are highly sensitive to infection with vectors derived from replication-defective HSV-1 [88]. HSV lymphadenitis is otherwise rare, and usually arises in inguinal lymph nodes in patients with associated hematopoietic malignancies [89,90]. HSV infection in CLL/SLL patients can be clinically indistinguishable from RT [91–94]. Moreover, superimposed HSV lymphadenitis on CLL/SLL can in some cases also histologically mimic RT, due to areas of necrosis surrounded by immunoblastic proliferation with abundant mitotic figures and a high Ki-67 proliferative index. However, the presence of larger multinucleate cells with Cowdry type A inclusions and ground glass nuclei, as well as the association of histiocytic and acute inflammatory cells with geographical necrosis, should raise suspicion for HSV lymphadenitis [91–95]. HSV immunohistochemistry or in situ hybridization (ISH) confirms the diagnosis. Patients with HSV lymphadenitis respond well to antiviral therapy.

#### *Other lymphomas arising in patients with CLL/SLL*

Despite not falling into the category of RT, the existence of lymphomas with a tendency to develop in patients with CLL/SLL is well documented and can potentially mimic RT clinically. It is noteworthy that the majority of peripheral T-cell lymphomas (PTCL) arising in CLL/SLL patients have a cytotoxic phenotype, although overall incidence of T-cell lymphomas in these patients does not seem increased [96]. Other rare composite T-cell lymphomas in CLL/SLL patients are follicular helper T-cell lymphoma [97] and PTCL Not Otherwise Specified (NOS) [98]. Alternatively, composite B-cell lymphomas with CLL/SLL have also been described, mainly mantle cell lymphoma [99–102], hairy cell leukemia [103–106] and extranodal marginal zone lymphoma [107]. Primary cutaneous lymphomas in patients with CLL/SLL have also been reported [108–111].

#### **Molecular mechanisms and clonal evolution underlying RT**

##### *Genomic landscape of RT subtypes*

The molecular background of RT has been progressively elucidated during the last decades thanks to the improvement of next-generation sequencing techniques. Importantly, genetic alterations have to be analyzed in light of RT types (HL or DLBCL) and subtypes (clonally related or unrelated to the preceding CLL based on the analysis of the V(D)J gene rearrangement of the immunoglobulin heavy chain). Due to its rarity, little is known about the genomics of HL-type RT, but most (~70 %) cases are clonally unrelated to the CLL, thus corresponding to second lymphomas frequently associated with Epstein-Barr virus (EBV) infection [15,69]. The high EBV positivity in HL-type RT contrasts with its low incidence in DLBCL-type RT (~65 % vs 6 %) [8,15,69]. Contrarily to HL-type RT, most (~80 %) DLBCL-type RT are clonally related to the CLL [8]. Clonal relationship in DLBCL-type RT determines distinct (immuno)genomic profiles [8]. Clonally unrelated DLBCL-type RT seems to harbor a lower prevalence of *TP53* alterations and stereotyped B-cell receptor immunoglobulins compared to clonally related tumors [8]. Nonetheless, they might carry alterations usually seen in



clonally related DLBCL-type RT including *MYC* and *CDKN2A* [112]. Of note, mutations in genes frequently altered in DLBCL without a history of CLL such as *KMT2D*, *EZH2* and *CREBBP* are rare in clonally unrelated DLBCL-type RT [18,112]. Nonetheless, the global driver landscape of clonally unrelated DLBCL-type RT is more similar to *de novo* DLBCL than clonally related DLBCL-type RT [18].

Clonally related DLBCL-type RT is the most studied subtype of RT both in the setting of chemoimmunotherapy (CIT) [7,8,16–18,113–116] and targeted therapies [17,18,117–121]. Based on these studies, virtually all (~90 %) clonally related DLBCL-type RT carry alterations in genes involved in cell cycle including *TP53*, *CDKN2A/B* and, to a lesser extent, *CDKN1A/B*, *CCND2*, *CCND3* and *CDK6*, among others. In addition, approximately 75 % of cases carry alterations in *MYC* pathway with amplifications or translocations of *MYC* and *MYCN*, and mutations/deletions of *MGA*. Alterations in genes involved in NF- $\kappa$ B (*BIRC3*, *EGR2*, *TNFAIP3*, *NFKBIE*, *TRAF3*) and NOTCH (*NOTCH1*, *SPEN*, *FBXW7*) pathways are found in ~75 % and ~30 % of cases, respectively. A large fraction of DLBCL-type RT (~75 %) also carries alterations in genes involved in chromatin remodeling such as *SETD2*, *SETD1A*, *SETD1B*, *ARID1A* and *CHD2*. With the exception of *MYC* and NOTCH pathway alterations, which rarely co-occur in the same tumors, these pathways are simultaneously altered in most cases. Clonally related DLBCL-type RT also carry a higher genomic complexity (i.e. more copy number alterations and structural variants) than the preceding CLL [7,16,17]. This increased genomic complexity is usually caused by the presence of chromothripsis affecting one or multiple chromosomes, which target in a single catastrophic event multiple driver genes such as *CDKN2A/B*, *CDKN1B*, *MYC*, *MGA*, and *TNFAIP3* [17]. In addition, whole-genome doubling has also been described in a fraction of tumors (~15 %) [18]. Altogether, these results show the complex driver landscape of clonally related DLBCL-type RT, which in turn is remarkably different to that observed in CLL [122] and *de novo* DLBCL [123,124]. In line with this rich and heterogeneous driver profile, unsupervised consensus clustering of DLBCL-type RT based on their driver alterations uncovered distinct RT molecular subtypes differing in driver alterations, genome alterations and, potentially, clinical outcome [18]. Larger cohorts with a complete characterization of the clonal relationship of DLBCL-type RT are needed to properly corroborate the potential prognostic value of the driver alterations, either alone or in combination, and genetic subtypes. Also of note, *BTK/PLCG2* and *BCL2* mutations are rare in clonally related DLBCL-type RT emerging after BCR and *BCL2* inhibitors, respectively [17,18,118,119]. In this regard, a similar driver landscape has been observed in clonally related DLBCL-type RT emerging after CIT and targeted therapies [17,18], although larger and homogeneously treated cohorts are needed to properly analyze subtle differences.

*In vitro* and mouse models have recently provided the rationale behind the genomic dysregulation of cell cycle in clonally related DLBCL-type RT [125]. It has been shown that BCR-stimulated proliferative CLL cells upregulate cell cycle inhibitors *CDKN1A* and *CDKN2A/B* to mediate control of cell proliferation. The inactivation of *TP53* and *CDKN2A/B* allow cells to proliferate beyond cell cycle arrest, thus providing experimental evidence on the loss of cell cycle control to enhance the high proliferation of RT [125]. Additional to BCR stimuli, mouse models also suggest that macrophage-derived signals [126] and constitutive Akt activation [127] might also support the growth and development of RT. In addition, genetically engineered mice revealed that co-selection of mutations in multiple CLL/RT drivers (specially *Trp53*, *Mga* and *Chd2*) drive lymphoma transformation mimicking clonally related DLBCL-type RT [128]. These results reinforce the idea that deregulation of multiple pathways including cell cycle, *MYC*/NOTCH, NF- $\kappa$ B and/or chromatin remodelers favors RT.

#### Epigenomic landscape of clonally related DLBCL-type RT

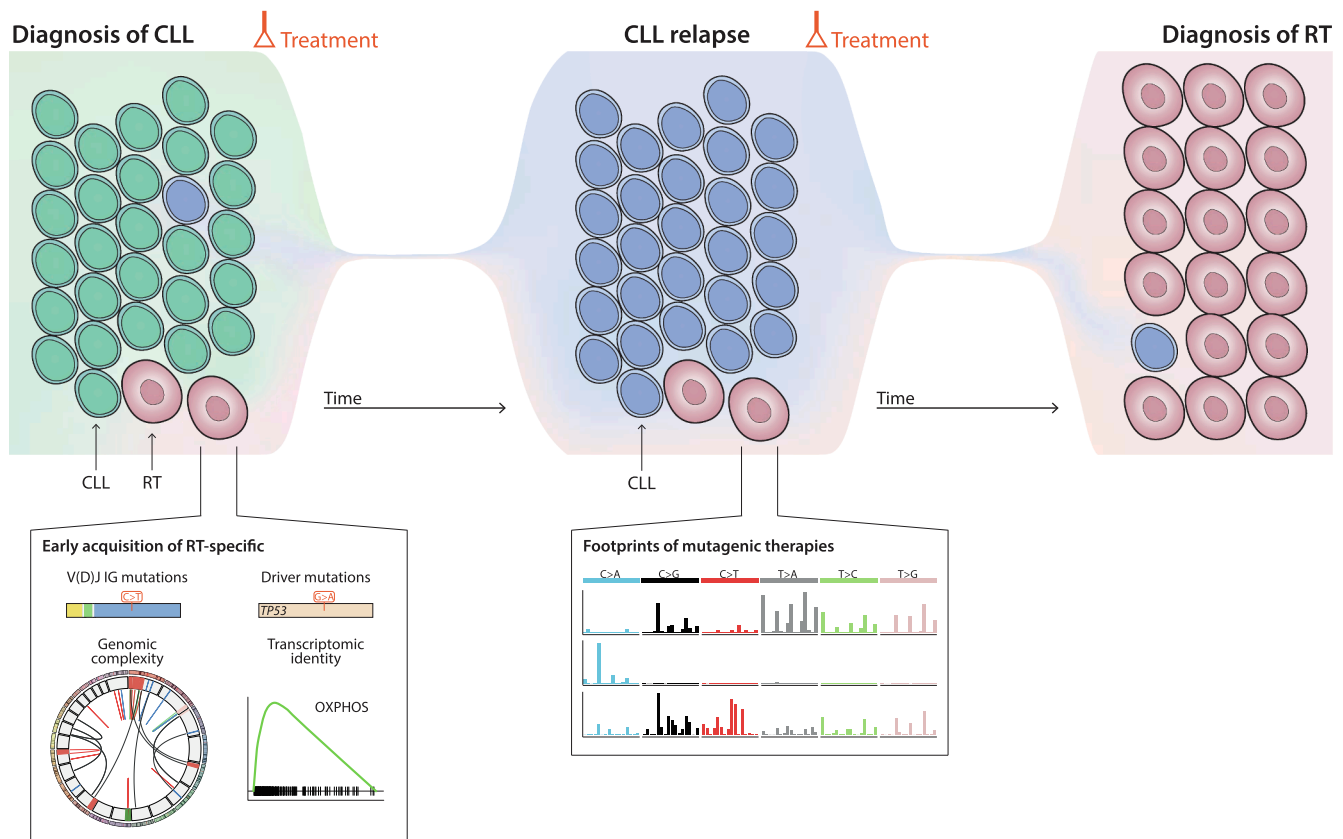
The genome-wide DNA methylome of DLBCL-type RT is hypomethylated compared to CLL and *de novo* DLBCL [17,129]. This pattern,

which might partially reflect the CLL cell of origin [17], is not found in clonally unrelated DLBCL-type RT, the methylome of which is more similar to *de novo* DLBCL [129], a finding in line with their driver genomic profiles. Intriguingly, ~6 % of *de novo* DLBCL shared a methylome profile similar to that of clonally-related DLBCL-type RT, which were mostly of the activated B cell-like subtype, enriched for *NOTCH1* mutations, and had an unfavorable outcome [129]. Whether these tumors might reflect clonally related DLBCL-type RT in which the preceding CLL was not detected or truly *de novo* DLBCL with RT-like features remains to be demonstrated.

The first glimpse into the chromatin accessibility and activity of clonally related DLBCL-type RT has been recently obtained studying a few cases that transformed after BCR inhibitors [17]. A small set of transcription factors related to proliferation (E2F family), *MYC* (*MAZ*), and oxidative phosphorylation (OXPHOS; *TEAD4*), among other pathways, seem to modulate the epigenome of clonally related DLBCL-type RT. Transcriptomic analyses have uncovered that genes upregulated in these cases include a number of Wnt family members, Toll-like receptors, and cyclin-dependent kinases, among others [17,129]. In agreement with the transcription factors identified, pathways upregulated in RT are related to proliferation, *MYC*, mTOR, and OXPHOS. Intriguingly, most clonally related DLBCL-type RT emerging after therapy with BCR inhibition showed a lower BCR signaling capacity compared to CLL [17]. These epigenetic and transcriptomic findings link clonally related DLBCL-type RT emerging after BCR inhibition with a subset of *de novo* DLBCL characterized by a high OXPHOS and low BCR signaling, which are insensitive to BCR inhibition [130,131]. Therefore, this OXPHOS<sup>high</sup>-BCR<sup>low</sup> axis might allow RT cells to escape from BCR inhibition. The potential BCR-signaling independence of BCR<sup>low</sup> clonally related DLBCL-type RT is supported by the identification of a clonally related DLBCL-type RT carrying novel mutations in the IGHV gene leading to an unproductive immunoglobulin gene [17] and the development of clonally related RT with plasmablastic differentiation, a cell type independent of BCR signaling [12,17,132,133], in patients treated with BCR inhibitors. The OXPHOS<sup>high</sup> phenotype observed in DLBCL-type RT could be driven by *MYC* pathway alterations [134–137], an hypothesis in agreement with the genomic alterations targeting genes involved in *MYC* pathway and the upregulation of *MYC*-related transcription factors and gene expression signatures in DLBCL-type RT [17]. OXPHOS inhibition using IACS-010759, a target of the mitochondrial complex I [138], markedly decrease the proliferation of OXPHOS<sup>high</sup> RT cells *in vitro* [17]. The dependency of clonally related DLBCL-type RT on OXPHOS pathway to sustain their high proliferation could be exploited therapeutically, probably in combination with *BCL2* inhibitors [137] or other drugs. Other pathways modulated epigenetically such as *MYC* and mTOR might also represent actionable targets of RT [128].

#### Evolutionary history of clonally related RT

Initial studies of RT under novel targeted therapies identified that clonally related RT sometimes occurs within the first months after treatment initiation [118,139], which suggests a potential selection of small, pre-existing RT subclones missed during routine analyses [140]. This hypothesis is in line with a study suggesting that clonally related DLBCL-type RT could originate from an early CLL cell already present in the initial phases of lymphomagenesis [141]. A recent study using single-cell DNA and RNA sequencing analyses of longitudinal samples collected over the disease course has revealed that small RT subclones can be detected decades before its final expansion, including at time of CLL diagnosis, in a remarkable fraction of the cases studied [17]. Intriguingly, these small RT subclones remained stable for up to 19 years until they rapidly expand before the diagnosis of RT. These early RT cells already harbored the driver mutations in genes such as *TP53*, the complex chromothriptic events affecting driver genes such as *SPEN* and *TRAF3*, and the mutations in the IGHV gene observed at time of diagnosis of RT. In addition, the transcriptomic identity of clonally related



**Fig. 2.** Clonal evolution dynamics of Richter transformation. Schematic representation of the proposed subclonal diversification and evolution of RT based on reference [17]. RT cells might be present in initial phases of the CLL course and might already carry the immunoglobulin mutations, driver gene mutations, genomic complexity and transcriptomic identity of the RT cells expanded at time of diagnosis of RT years after [left]. RT cells might acquire mutations genome-wide associated to the exposure to alkylating agents and antiviral drugs given to the patients during their CLL course, which are recognized through mutational signature analysis. Mutational signatures (SBS) shown from top to bottom: SBS-RT associated to bendamustine and chlorambucil, SBS-ganciclovir associated to ganciclovir, and SBS-melphalan linked to melphalan therapy [middle]. A single RT cell might drive the clonal explosion associated with the clinical transformation leading to the diagnosis of RT [right].

DLBCL-type RT, including the OXP<sup>high</sup>-BCR<sup>low</sup> axis, was identified in the early RT cells [17]. These results show that CLL evolution towards RT is characterized by an early tumor diversification that might lead to the emergence of RT subclones with genomic, immunogenetic and transcriptomic profiles of overt RT years before its clinical manifestation (Fig. 2). In line with these results, analysis of cell-free DNA obtained months before the diagnosis of RT also allowed the early detection of mutations and copy number alterations of the RT [18].

The longitudinal analysis of clonally related RT has also uncovered that their genome might carry hundreds of mutations associated with therapies of the CLL phase (up to 7 years prior to the diagnosis of RT) such as melphalan (used as a conditioning of allogeneic stem-cell transplant) and ganciclovir (given to patients due to cytomegalovirus reactivation) [17]. These analyses also identified that the exposure of cells to the alkylating agents bendamustine and chlorambucil might introduce hundreds of mutations in their genomes, which were recognized as a specific mutational signature in RT cells (mutational signature: combination of mutation types arising from a specific mutagenic process) (Fig. 2). These therapy-related mutations might account for >25 % (i.e. >1,000) of the mutations found genome-wide in some RT, a few of them within the coding region of driver genes [17]. Together with the single-cell evolutionary dynamics of RT subclones mentioned above, the identification of hundreds of random mutations associated with treatment regimens of the CLL phase present in all RT-cells at time of RT diagnosis demonstrates that the clonal expansion of an early single RT cell drives this aggressive transformation; a clonal expansion that can start years before its clinical consequences.

### Clinical features and diagnosis

Features that may raise suspicion of RT in a patient with CLL include the appearance of B-symptoms, such as fever without evidence of infection, night sweats, or weight loss, as well as the rapid growth of asymmetric lymph nodes. Additional laboratory findings, such as an increase of serum lactate dehydrogenase (LDH) levels or hypercalcemia, may also be indicative of RT. However, it is important to note that these features are non-specific, and a definitive diagnosis of RT can only be made through biopsy of lymph node or other extranodal lesions biopsy.

In the context of RT in patients with CLL, PET/CT can be a useful tool to identify lesions that are suitable for biopsy to confirm the diagnosis. Studies have evaluated the predictive value of the PET/CT for diagnosing RT [142,45–47], with findings suggesting that an increased 18F-fluorodeoxyglucose (FDG) uptake with a SUV<sub>max</sub> > 5 has high sensitivity (88–91 %) and negative predictive value (92–97 %) for detecting RT. However, the specificity (47–80 %) and positive predictive value (38–53 %) of this approach are less consistent, and alternative diagnosis such as other malignancies, accelerated CLL, or infections should be ruled out [45–47]. In this context, a SUV<sub>max</sub> value below 5 can almost confidently exclude the diagnosis of RT and may avoid the need for a biopsy. On the other hand, an abnormal PET/CT with a SUV<sub>max</sub> value > 5 may raise suspicion of RT, but it should not be considered as a substitute for a biopsy.

To enhance the predictive value of the PET/CT in the diagnosis of RT, various SUV<sub>max</sub> cutoffs have been evaluated. Michallet et al. proposed a SUV<sub>max</sub> threshold of ≥10 as more discriminative method for diagnosing

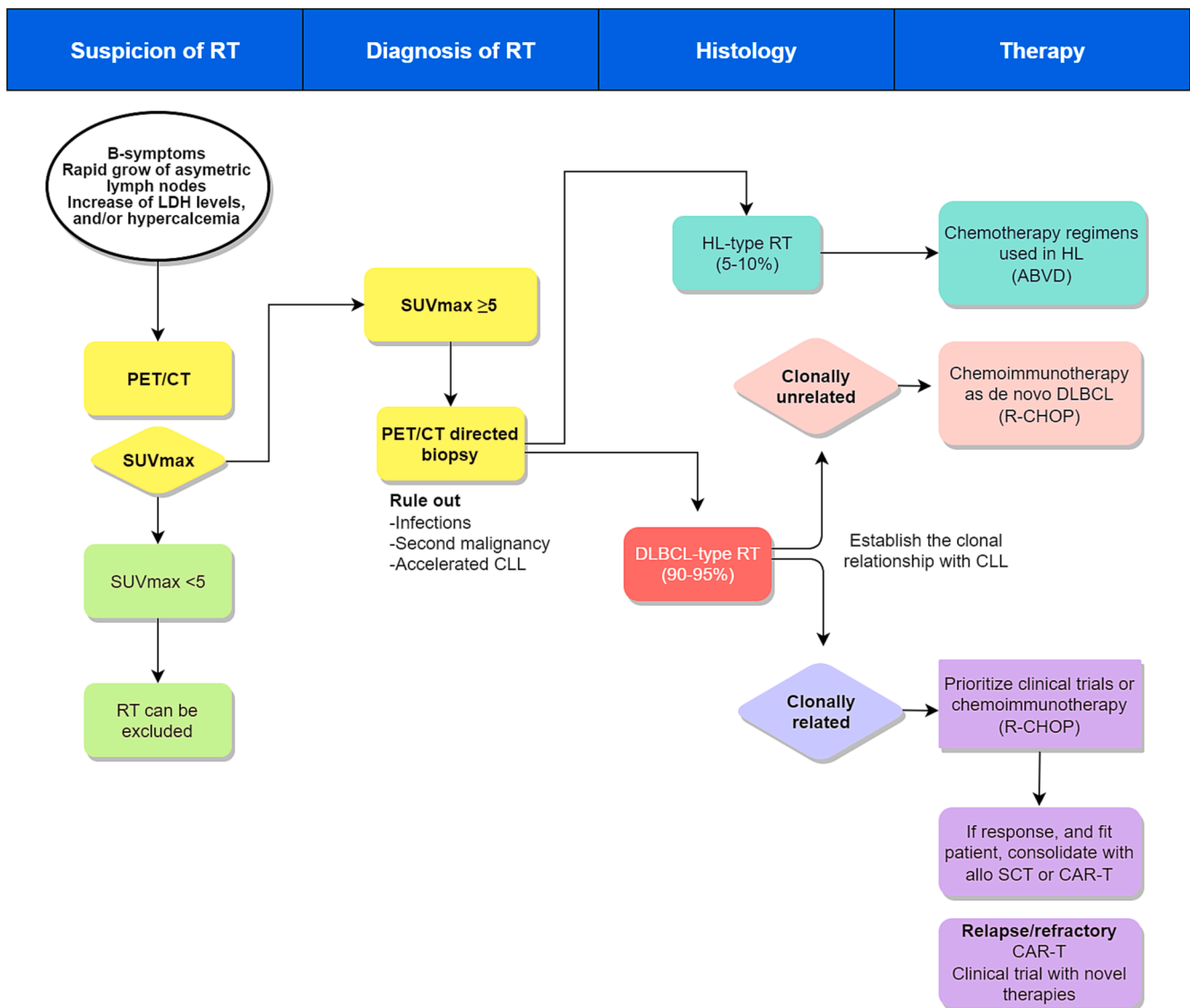


**Table 1**  
Summary of studies evaluating chemoimmunotherapy in RT.

RT type	Regimen	Author, year	Study desing, phase	Trial ID	Status	RT pts (n)	Median age (years)	TP53 aberr. (%)	IGHV UM (%)	CK (%)	Prior lines (range)	ORR (%)	CR (%)	Median PFS (mo)	Median OS (mo)	G 3-4 Anemia (%)	G 3-4 Neutropenia (%)	G 3-4 Thrombopenia (%)	G 3-4 Infection (%)	TRM (%)
DLBCL	CHOP	Abrisqueta, 2020 [19]	R	NA	NA	15	66*	45*	77*	56*	1 (0-7)*	20	13	2.6	3.3	NR	NR	NR	NR	NR
DLBCL	R-CHOP	Langerbeins, 2014 [21]	CT, II	NCT00309881	Completed	15	69	33	67	NA	2 (0-4)	67	7	10	21	75*	55*	65*	28*	5*
DLBCL	O-CHOP	Eyre, 2016 [22]	CT, II	NCT01171378	Completed	37	66.2	43	NA	NA	1 (0-4)	46	27	6.2	11.4	NR	33	26	51	0
DLBCL	R-EPOCH	Rogers, 2018 [144]	R	NA	NA	46	67	49	84	67	3 (0-12)	37	20	3.5	5.9	NR	NR	NR	NR	NR
DLBCL	Hyper-CVXD	Dabaja, 2001 [23]	CT, II	NA	Completed	29	61	NA	NA	NA	2 (0-3)	41	38	NA	10	NR	100	41	50	14
DLBCL	R-Hyper-CVXD + GM-CSF/R + HDM-Ara-C + GM-CSF	Tsimberidou, 2003 [24]	CT, II	NA	Completed	30	59*	NA	NA	11*	4 (NR)*	43	27	NA	8.5*	NR	100*	40*	39*	22*
DLBCL	OFAR1	Tsimberidou, 2008 [146]	CT, I/II	NCT00452374	Completed	20	66	33	11	NR	2 (0-10)*	50	20	4	8	54*	85*	95*	8*	3
DLBCL	OFAR2	Tsimberidou, 2013 [25]	CT, I/II	NCT00472849	Completed	35	63*	23	85	NR	3 (0-9)*	39	6	3	6.6	50	89	77	17	8
DLBCL	DHAP, ESHAP	Durot, 2015 [147]	R	NA	NA	28	63	40	80	61	3 [1-7]*	43	25	6.9	8.3	72*	83*	82*	43*	16*
HL	ABVD, CVPP, CVPP/ABVD, CHOP, RCHOP, other, no therapy	Tsimberidou, 2006 [148]	R	NA	NA	18	72	NR	NR	17	2 (0-7)	44	19	4.8	9.6	NR	NR	NR	NR	NR
HL	ABVD, MOPP, CHOP, other	Bockorny, 2011 [68]	R	NA	NA	86	65.7	NR	NR	NR	NR	53	27	NR	20.4	NR	NR	NR	NR	NR
HL	ABVD, MOPP + ABV, BEACOPP, escalated BEACOPP, ESHAP, DVIP, ABMT	Tadmor, 2014 [149]	R	NA	NA	16	58	NR	NR	NR	NR	NR	37	NR	39.5	NR	NR	NR	NR	NR

\*: global cohort results, RT cohort data not reported.

Aberr.: aberrations; ABMT: autologous bone marrow transplantation; ABVD: doxorubicin, bleomycin, vinblastine; ABVD: doxorubicin, bleomycin, vinblastine, and dacarbazine; BEACOPP: bleomycin, etoposide, adriamycin, cyclophosphamide, oncovin, procarbazine, prednisone; CHOP: cyclophosphamide, doxorubicin, vincristine, and prednisone; CVPP: cyclophosphamide, vinblastine, procarbazine, and prednisone; CK: complex karyotype; CR: complete response; CT: *clinical trial*; DHAP: dexamethasone, cytarabine, and cisplatin; DLBCL: *Diffuse large B-cell lymphoma*; DVIP: dexamethasone, etoposide, ifosfamide, cisplatin; ESHAP: etoposide, methylprednisolone, cytarabine, and cisplatin; G: grade; GM-CSF: granulocyte macrophage-colony-stimulating factor; HL: Hodgkin lymphoma; hyper-CVXD: fractionated cyclophosphamide, vincristine, liposomal daunorubicin, and dexamethasone; mo: months; MOPP: mechlorethamine, vincristine, procarbazine, and prednisone; n: number; NA: *not apply*; NR: *not reported*; O-CHOP: CHOP plus ofatumumab; OFAR: oxaliplatin, fluradabine, ara-C, and rituximab; ORR: overall response rate; OS: overall survival; PFS: progression free survival; pts: patients; prior lines of treatment; R: *retrospective*; R-CHOP: rituximab, CHOP; R-EPOCH: rituximab, etoposide, prednisone, vincristine, cyclophosphamide, doxorubicin; R-hyper-CVXD + GM-CSF/R + HDM-ara-C + GM-CSF: rituximab, fractionated cyclophosphamide, vincristine, liposomal daunorubicin, dexamethasone and GM-CSF alternating with rituximab, methotrexate, ara-C and GM-CSF; RT: Richter transformation; TRM: treatment-related mortality; UM: unmutated.



**Fig. 3.** Algorithm for Richter Transformation (RT) diagnosis and treatment. If clinical (B symptoms, rapid growth of asymmetric lymph nodes) and/or analytical (increasing LDH, hypercalcemia) suspicion of RT is present, an imaging study with FDG-PET/CT must be performed. If SUVmax is  $\geq 5$ , a guided biopsy of the most intense region should be made to confirm RT and rule out second malignancy, infection, or accelerated CLL. Histologically, the most common types of RT are Diffuse Large B Cell Lymphoma (DLBCL) and Hodgkin Lymphoma (HL). In the former, evaluating the clonal relationship with CLL cells is necessary. The frontline treatment of HL-RT and no clonally related DLBCL-RT is typically based on established regimens ABVD and R-CHOP, respectively. By contrast, the best therapy for DLBCL-RT clonally related is currently an unsolved medical condition and, if possible, patients should be treated under clinical trials and novel therapies and consolidated with cellular therapies.

RT. Using this threshold, the sensitivity and specificity of PET/CT in their study were found to be 91 % and 95 %, respectively. Furthermore, the inferred positive predictive value and negative predictive value were 28.7 % and 99.8 % when considering a RT prevalence of 2.2 %, and of 60.6 % and 99.2 % when considering an 8 % RT prevalence [142].

Recently, the utility of PET/CT in the diagnosis of RT has been evaluated in the context of CLL treated with targeted therapies, specifically ibrutinib and/or idelalisib [143]. The results of this study indicated moderate sensitivity and specificity in comparison to previous studies that assessed PET/CT in untreated CLL or treated with chemoimmunotherapy-based regimens. Using a SUVmax threshold of  $\geq 10$ , sensitivity and specificity were 71 % and 50 %, respectively. Additionally, the PPV and NPV for the detection of RT were 26 % and 88 %, respectively. These findings suggest that relapses following BCR inhibitors exposure may be more metabolically active in comparison to progression after chemoimmunotherapy [143]. Nevertheless, additional data are needed to establish the precise role of PET/CT in the diagnosis

of RT in the context of targeted therapies.

**Prognosis**

RT is associated with a dismal prognosis with median survival consistently reported inferior to 1 year in the different series, despite notable variations in the timeframe covered by these studies [19,20,37,40,58]. Although no direct comparison evaluating outcomes of HL-type RT vs DLBCL-type RT is available, patients diagnosed with HL-type RT seem to present a better overall survival (OS) than DLBCL-type RT although inferior to those with de novo HL, with median OS reported of 2.6–3.9 years [14,19].

Several clinical and biological factors have been described, mainly in the context of DLBCL-type RT, to predict the outcome of patients with RT. This is including the Eastern Cooperative Oncology Group Performance Status (ECOG), the number of lines of treatment received for CLL prior to the diagnosis of RT, laboratory values such as the platelet



**Table 2**  
Summary of studies evaluating chemoimmunotherapy in RT.

RT type	Regimen	Main target	Author, year	Study desing, phase	Trial ID	Status	RT pts (n)	Median age (years)	TP53 Aber (%)	IGHV UM (%)	CK (%)	Prior lines (range)	ORR (%)	CR (%)	Median PFS (mo)	Median OS (mo)	G 3–4 Anemia (%)	G 3–4 Neutropenia (%)	G 3–4 Thrombopenia (%)	G 3–4 Infection (%)
DLBCL	Ibrutinib	BTK	Tsang, 2015 [208]	R	NA	NA	4	71	25	100	NR	2 (0–3)	75	50	NR	NR	NR	NR	NR	NR
DLBCL	Ibrutinib	BTK	Visentin, 2018 [156]	R	NA	NA	4	69	25	75	NR	2 (NR)	25	0	Nr	Nr	25	100	75	25
DLBCL	Ibrutinib	BTK	Winter, 2017 [209]	R	NA	NA	13	61	NR	NR	NR	3 [1–11]	46.2	7.7	3	7.2	NR	NR	NR	NR
DLBCL	Ibrutinib + Ofatumumab	BTK	Jagłowski, 2015 [153]	CT, Ib/II	NCT01217749	Completed	3	64*	44*	NR	NR	3 [2–13]*	33	0	NR	NR	0	24*	NR	17*
DLBCL	Ibrutinib + Nivolumab	BTK, PD-1	Jain, 2018 [165]	CT, II	NCT02420912	Completed	23	65	NR	NR	NR	3 (0–10)	43	35	NR	13.8	NR	NR	NR	NR
DLBCL	Ibrutinib + Nivolumab	BTK, PD-1	Younes, 2019 [166]	CT, I/IIa	NCT02329847	Completed	20	67.5	NR	NR	NR	2 [1–3]	65	10	5	10.3	35	25	10	0
DLBCL	Acalabrutinib	BTK	Eyre, 2021 [31]	CT, I/II	NCT02029443	Active, not recruiting	25	66	42	78	43	1	40	8	3.2	NA	20	28	12	4
DLBCL	R-CHOP +/- Acalabrutinib	BTK	Appleby, 2019 [154]	CT, II	NCT03899337	Not yet recruiting	NA	NA	NA	NA	NA	NA	NA	NA	NA	NA	NA	NA	NA	NA
DLBCL	Pirtobrutinib	BTK	Mato, 2020 [155]	CT, I/II	NCT03740529	Recruiting	9	64	NR	NR	NR	6 [2–9]	75	0	NR	NR	4*	10*	NR	NR
DLBCL	Idelalisib	PI3K	Visentin, 2018 [156]	R	NA	NA	4	68	75	50	NR	2.5 (NR)	75	25	Nr	Nr	25	25	25	25
DLBCL	Venetoclax	BCL2	Dauids, 2017 [29]	CT, I	NCT01328626	Completed	7	73	NR	NR	NR	3 [2–7]	43	0	NR	NR	15*	11*	NR	2*
DLBCL	Venetoclax	BCL2	Bouclet, 2021 [158]	R	NA	NA	7	67*	74*	NR	58*	4 (0–7)*	28.6	NR	NR	1.1	NR	NR	NR	24*
DLBCL	Venetoclax	BCL2	Dauids, 2022 [159]	CT, II	NCT03054896	Recruiting	26	63	42	NR	52	NR	62	50	10.1	19.6	NR	65	50	38
DLBCL	Venetoclax + Duvelisib	BCL2, PI3K	Crombie, 2020 [161]	CT, I/II	NCT03534323	Recruiting	3	69*	45*	91*	NR	3 [1–6]	33	0	NR	NR	23*	68*	14*	NR
DLBCL	Venetoclax + Obinutuzumab + Atezolizumab	BCL2, PD-L1	Jain, 2021 [160]	CT, II	NCT02846623	Recruiting	7	70	57	86	43	NR	100	71.4	NR	NR	NR	NR	NR	NR
DLBCL	Selinexor	XPO1	Kuruville, 2014 [162]	CT, I	NCT01607892	Completed	6	62*	NR	NR	NR	3 (NR)*	33	0	NR	NR	7*	22*	31*	NR
DLBCL	Pembrolizumab	PD1	Ding, 2017 [32]	CT, II	NCT02332980	Active, not recruiting	9	69	55	78	NR	5 [1–10]	44	11	5.4	10.7	20*	20*	20*	8*

\*: global cohort results, RT cohort data not reported.

Aberr.: aberrations; BTK: Bruton tyrosine kinase; CK: complex karyotype; CR: complete response; CT: clinical trial; DLBCL: Diffuse large B-cell lymphoma; G: grade; mo: months; NA: not apply; n: number; NR: not reported; Nr: not reached; ORR: overall response rate; OS: overall survival; PFS: progression free survival; PD-1: programmed death 1; PD-L1: programmed death ligand 1; PI3K: phosphatidylinositol-3 kinase; pts: patients; prior lines of treatment; R: retrospective; R-CHOP: rituximab, cyclophosphamide, doxorubicin, vincristine, and prednisone; RT: Richter transformation; UM: unmutated.

counts, LDH and  $\beta$ 2-microglobulin levels, genetic abnormalities, particularly *TP53* alterations, and the clonal relationship between the preexisting CLL and the RT [8,20,45,58]. This latter factor is strongly associated with a shorter OS of patients with RT. Despite < 20 % of cases are clonally unrelated, these patients have a significantly better outcome, underlining the concept that these cases represent *de novo* lymphomas and not true transformations of the preceding CLL [8,19].

*TP53* alterations is another factor with a major impact on survival in RT. Different studies have shown the negative impact of *TP53* disruption, including *TP53* mutations and/or *TP53* deletions, in the outcome of patients with RT [8,19,21,22,58,144].

Beyond these pathological features associated with the prognosis of RT, patients who are treatment naïve for CLL exhibit a significantly better outcome than those previously treated for CLL [19,37,58], with medians of OS reported in the GELLC study and in the Mayo Clinic series of 35.4–46.3 months vs 4.2–7.8 months for patients with prior treatment for CLL, respectively [19,58].

Finally, different efforts have been attempted to integrate these variables in prognostic index for RT. The first score index in RT was developed by the MD Anderson Cancer Center (MDACC), including ECOG performance status (PS) [2–4], LDH levels (<1.5 $\times$  normal vs >1.5 $\times$  normal), platelet count (>100  $\times$  10<sup>9</sup>/L vs <100  $\times$  10<sup>9</sup>/L), tumor size (<5 cm vs >5 cm), and prior therapies for CLL (0–1 vs >1). According to the number of presenting risk factors (0 or 1, low risk; 2, low-intermediate risk; 3, high-intermediate risk; or 4 or 5, high risk) patients were assigned to one of four risk groups with differentiated survival outcomes. Lately, and integrating biological features associated with the outcome of patients with RT, Rossi et al. developed a model that included *TP53* status, response to RT induction treatment, and ECOG PS that improved the discriminate value of the model over a score based only on clinical parameters [8]. Finally, in our study from the GELLC, platelet count of <100  $\times$  10<sup>9</sup>/L, prior CLL therapy and *TP53* alterations in the CLL clone were the variables most strongly associated with OS. Considering these three variables, we were able to identify a subgroup of patients with DLBCL-type RT (17.5 %) with a better clinical outcome (median OS of 75.3 months), while patients with one or two or more of these factors presented a median OS of 25.5 and 3 months, respectively [19].

## Treatment

### Chemoimmunotherapy

The frontline treatment of DLBCL-type RT is typically based on established regimens commonly utilized in DLBCL, particularly anthracycline-based combinations such as R-CHOP or R-EPOCH (Table 1). (Fig. 3) Chemotherapy alone with CHOP regimen has demonstrated a limited overall response rate (ORR) ranging from 20 to 30 % and median OS inferior to 8 months [19,20,145]. The addition of rituximab to the CHOP regimen (R-CHOP) has resulted in a significant improvement in ORR and survival. Specifically, R-CHOP exhibits an ORR of 67 %, with complete responses (CR) of 7 %, a median progression free survival (PFS) of 10 months, and median OS of 21 months [21,52]. The substitution of rituximab for ofatumumab, a second generation anti-CD20 monoclonal antibody, within the CHOP scheme (O-CHOP) did not improve R-CHOP outcomes [22].

More aggressive CIT regimens have not provided a benefit over R-CHOP and were associated with higher hematological and infectious toxicity. For example, the R-EPOCH regimen obtained an ORR of 37 % (CR 20 %), with a median PFS of 3.5 months and median OS of 5.9 months [144]. Hyper-CVXD regimen, including liposomal daunorubicin, resulted in ORR of 41 % (CR 38 %) and median OS of 10 months. However, this regimen caused severe hematological toxicity (100 % and 41 % of grade 3–4 neutropenia and thrombopenia, respectively) and infectious complications in 50 % of patients, with a treatment-related mortality (TRM) of 14 % [23]. HyperCVAD plus rituximab in

alternating combination with methotrexate and ARA-C has shown an ORR of 43 % (CR 38 %), and a median OS of 8.5 months, but with severe hematological toxicity and a treatment-related mortality rate nearly 20 % [24].

Schemes based on platinum-containing regimens have also been explored in the treatment of DLBCL-type RT. The OFAR 1 and OFAR 2 trials evaluated the combination of oxaliplatin, fludarabine, ARA-C and rituximab at different dosages to prevent toxicities. The results showed an ORR ranging from 39 % to 50 % (CR 6 %–20 %), with a median PFS of 3 months and a median OS of 6–8 months [25,146]. Other platinum-containing regimens evaluated in the context of RT have been ESHAP (based on etoposide, methylprednisolone, cytarabine and cisplatin) and DHAP (dexamethasone, cytarabine and cisplatin), with an ORR of 43 % (CR 25 %) and a median OS of 8 months. These regimens caused high hematological toxicity, but also acute renal insufficiency in 44 % of cases (grade III–IV in 12 %), infections (43 %) and a considerable TRM (16 %) [147].

Finally, regarding the treatment of HL subtype, ABVD regimen has been the most used regimen, with an ORR of 40 to 60 % and a median OS of 4 years [68,148,149].

### Novel treatment strategies

In the past last 5 years, several novel agents have emerged as promising therapeutic options for patients with B-cell malignancies and have been evaluated in treating patients with RT. These include targeted small molecules inhibitors, novel monoclonal antibodies, and strategies based on inducing an anti-tumor immune response, particularly chimeric antigen receptor (CAR) T-cell therapy and T-cell-engaging bispecific antibodies.

#### Small-molecule targeted therapies

The most relevant small molecule inhibitors being evaluated for the treatment of RT include BTK, PI3K and BCL-2 inhibitors [145,150,151].

Ibrutinib, a first-in-class covalent irreversible BTK-inhibitor, was tested in monotherapy in the treatment of small cohorts of DLBCL-type RT with limited activity and acceptable tolerability (Table 2). Ibrutinib has been explored in combination with rituximab or ofatumumab in a limited number of cases with limited activity [152,153]. Acalabrutinib, a second-generation of covalent BTK inhibitor, showed preliminary efficacy results as a single agent in 25 patients with DLBCL-type RT with an ORR of 40 % (CR 8 %), a median PFS of 3 months and a median DOR of 6.2 months [31]. Acalabrutinib is currently being tested in combination with R-CHOP followed by acalabrutinib maintenance in a prospective, phase II randomized study for patients with newly diagnosed RT [154]. Finally, pirtobrutinib (Loxo-305), a next generation non-covalent BTK inhibitor, induced a promising ORR of 67 % in 15 evaluable patients with RT included in the phase 1/2 BRUIN study [155].

Idelalisib is a selective inhibitor of the kinase PI3K $\delta$  that abrogates PI3K/Akt signaling and promotes apoptosis. Idelalisib administered in monotherapy obtained an ORR of 75 % (CR 25 %) in four patients with RT [156], and a short duration of response in a case treated with idelalisib and rituximab [157].

The BCL2 inhibitor venetoclax has been evaluated for its therapeutic potential in monotherapy and in combination with chemoimmunotherapy (R-EPOCH) for the treatment of patients with DLBCL-type RT (Table 2). Venetoclax as a single agent obtained partial responses in three out of seven patients with RT in a phase I study, with a median time to first response of 100 days [29]. Moreover, a retrospective analysis (FILO study) found that two out of seven patients treated with venetoclax monotherapy achieved an objective response (ORR 28.6 %), with a response duration of 7 and 14 months in these responding patients [158]. On the other hand, the combination of venetoclax with R-EPOCH has yielded promising results in a study involving 26 RT patients, with an ORR of 62 % and a CRR of 50 %, despite the expected toxicities from this combination [159]. Additionally, other



**Table 3**  
Main retrospective studies reviewing transplant outcomes in RT patients.

Author, year (Ref)	N	OS	PFS	Relapse	NRM
Tsimberidou AM, 2006 [17]	17 allo-HCT (88 % RIC) 3 auto-HCT	75 % at 3y (CR/PR at HCT) 21 % at 3y (PD at HCT)	–	–	–
Cwynarski K, 2012 [23]	34 auto-HCT 25 allo-HCT (72 % RIC)	36 % at 3y (allo) 59 % at 3y (auto)	27 % at 3y (allo) 45 % at 3y (auto)	47 % at 3y (allo) 43 % at 3y (auto)	26 % at 3y (allo) 12 % at 3y (auto)
Kharfan-Dabaja MA, 2018 [25]	10 allo-HCT (30 % RIC)	50 % at 4y	50 % at 4y	10 % at 4y	40 % at 4y
Herrera AF, 2021 [184]	53 auto-HCT 118 allo-HCT (72 % RIC)	57 % at 3y (auto) 52 % at 3y (allo)	48 % at 3y (auto) 43 % at 3y (allo)	37 % at 3y (auto) 30 % at 3y (allo)	10 % at 1y (auto) 23 % at 1y (allo)
Lahoud OB, 2021 [185]	23 allo-HCT (100 % RIC)	74 % at 2y	65 % at 2y	–	13 % at 2y
Kim HT, 2021	28 allo-HCT	53 % at 4y	39 % at 4y	32 % at 4y	29 % at 4y

Abbreviations: Ref, reference; N, number of patients; OS, overall survival; PFS, progression-free survival; NRM, non-relapse mortality; auto-HCT, autologous hematopoietic cell transplantation; allo-HCT, allogeneic hematopoietic cell transplantation; y, years; RIC, reduced intensity conditioning.

combinations currently being tested include venetoclax, obinutuzumab and atezolizumab, venetoclax plus duvelisib, and venetoclax with obinutuzumab and ibrutinib (NCT04939363) [160,161].

Finally, selinexor has also been tested in patients with RT. This agent inhibits XPO1, a nucleo-cytoplasmic transporter of tumor suppressor proteins, leading to increased nuclear retention of major tumor suppressor proteins and selective apoptosis in cancer cells [162]. An initial ORR of 33 % was observed in the phase 1 study, with no complete responses reported. However, a subsequent phase II study (NCT02138786) in R/R RT was terminated prematurely due to lack of efficacy.

#### PD-1/PD-L1 pathway

It has been observed that, in comparison to DLBCL NOS, patients with RT exhibit a higher expression of programmed death receptor-1 (PD-1) on T-cells and PD-ligand 1 (PD-L1) on RT cells [61]. These observations suggested that targeting the PD-1 pathway may be a suitable therapeutic option. Nevertheless, pembrolizumab and nivolumab have shown modest efficacy in prospective clinical trials including a limited number of RT patients [163,164]. Currently, ongoing trials are exploring the combination of PD-1 targeting antibodies with other signaling pathways (NCT04271956, NCT02535286). The combination of nivolumab and ibrutinib has shown preliminary promising efficacy in the treatment of RT patients, with an ORR ranging from 43 to 65 % and a DOR ranging from 6.9 to 9.3 months [165,166]. Other PD-1/PD-L1 inhibitors that are being evaluated in patients with RT include tislelizumab, a PD-1 inhibitor engineered to minimize binding to FcγR on macrophages, which is currently being studied in combination with zanubrutinib [167], and durvalumab, a PD-L1 inhibitor, in combination with acalabrutinib and venetoclax (NCT05388006).

#### Stem cell transplant

Allogeneic hematopoietic cell transplant (HCT) is a recommended consolidation strategy for RT patients who respond to induction therapy, given the high relapse risk and poor overall survival following progression (Table 3). Unfortunately, this procedure is only accessible to a

limited subset of young, fit patients who have an adequate response to treatment [19,20,40,168].

The largest study to date of HCT in RT was a retrospective report from the Center for International Blood and Marrow Transplant Research (CIBMTR) registry including 55 patients who underwent an autologous HCT (auto-HCT) and 118 who underwent an allogeneic HCT (allo-HCT). The 3-year PFS and OS were 48 % and 57 % for patients who received an auto-HCT, 43 % and 52 % in allo-HCT recipients. The study found that a deeper pretreatment response had a significant impact on long-term outcomes; conversely, high-risk cytogenetic abnormalities and previous novel agents did not influence survival [169]. Another important retrospective study analyzed patients from the European Society for Blood and Marrow Transplantation (EBMT) database. Of 59 patients registered from 1997 to 2007, 34 had received an auto-HCT and 25 an allo-HCT (72 % with a reduced intensity conditioning [RIC]). The 3-year relapse-free survival (RFS) and OS was 59 % and 45 % for the auto-HCT, 36 % and 27 % for the allo-HCT group, respectively. A younger age, chemotherapy-sensitive disease and RIC were associated with superior RFS after allo-SCT [26]. Additional retrospective studies observed favorable outcomes with a RIC for allo-HCT recipients and treatment-sensitive disease prior to transplant. High-risk cytogenetics and previous novel agents did not impact results [20,28,170,171]. Finally, a systematic review and meta-analysis including four studies with 72 RT patients that underwent allo-HCT identified a pooled OS, PFS, NRM and relapse rates of 49 %, 30 %, 24 % and 28 %, respectively [172].

Taking all of this into account, allo-HCT is still a valid post-remission therapy for young, fit patients achieving a response to chemoimmunotherapy or targeted agents.

#### Chimeric antigen receptor T-cell therapy

Chimeric antigen receptor (CAR) T-cell therapy is a standard approach for patients with relapsed/refractory large B-cell lymphoma, based on the pivotal phase II trials ZUMA-1, JULIET and TRANSCEND which led to the approval of axicabtagene ciloleucel (axi-cel), tisa-genlecleucel and lisocabtagene maraleucel, respectively [173–175]. However, DLBCL-type RT patients were excluded from the first 2 trials and only 5 (2 %) patients with DLBCL transformed from CLL/SLL were included in the latter.

Focusing on studies which included RT patients, initial data from the Seattle group reported some durable responses in high-risk R/R CLL and RT patients after CD19-targeted CAR T-cell therapy [176]. Toxicity was mainly low-grade with no unexpected safety signals. A follow-up study from this group with R/R CLL and RT patients maintained ibrutinib through apheresis, bridging and infusion, aiming to increase efficacy and ameliorate toxicity. Four patients with RT were included but results were reported together with the CLL patients. Survival outcomes were comparable between the ibrutinib and previous non-ibrutinib cohorts, but rates of severe CRS and CRS-related cytokines were lower [177]. Another trial with a CD28 second-generation CAR-T included 6 patients with DLBCL-type RT. Patients received a median of 1 prior line of RT-directed therapy, mainly with R-CHOP, while previous treatment for CLL included ibrutinib in 5/6 and venetoclax in 4/6 patients. Best response included 4/6 patients in CR, of which 2 underwent an allo-HCT consolidation. Toxicity was mostly low grade [178].

Recently, a Spanish trial with an academic CD19-targeted CAR-T (ARI-0001) reported data in 8 CLL patients, 5 with concomitant RT. Of the latter group, 3 (60 %) patients achieved a CR, ongoing at data cutoff, and the other 2 achieved a PR and SD, respectively. Measurable residual disease (MRD) was undetectable in all patients, both in peripheral blood and bone marrow. Both cases who did not achieve a CR progressed with CD19-negative disease. Regarding toxicity, 4 out of 5 patients presented cytokine release syndrome (CRS), grade 1–2 in all cases; no patients experienced neurotoxicity [179]. Finally, a single-center retrospective report included 9 RT patients treated with off-label commercial axi-cel. Eight patients had prior BTKi therapy, and 7 patients received this agent

**Table 4**  
Summary of studies evaluating novel therapies and combinations of novel agents in patients with RT.

Trial ID	Status	Disease	N° of patients	Treatments	Phase
NCT04271956	Recruiting	RT	48	Zanubrutinib, Tislelizumab	Phase II
NCT03121534	Completed	RT	10	Blinatumumab	Phase II
NCT04992377	Not yet recruiting	RT (of CLL)	30	R-EPOCH, Ibrutinib	Phase II
NCT03931642	Active, not recruiting	RT	41	R-CHOP, Blinatumumab	Phase II
NCT04679012	Recruiting	RT	20	R-EPCH, Polatuzumab	Phase II
NCT03054896	Recruiting	RT	67	DA-R-EPOCH, R-CHOP, Venetoclax	Phase II
NCT02535286	Completed	RT, R/R CLL	27	Ublituximab Umbralisisb	Phase I
NCT03899337	Not yet recruiting	RT	105	R-CHOP, Acalabrutinib	Phase II
NCT04939363	Recruiting	RT	15	Obinutuzumab, Ibrutinib, Venetoclax	Phase II
NCT05388006	Recruiting	RT	33	Acalabrutinib, Durvalumab, Venetoclax	Phase II
NCT03113695	Completed	RT	4	Obinutuzumab, HDMP, Lenalidomide	Phase I
NCT04623541	Recruiting	RT, R/R CLL	102	Epcoritamab	Phase Ib/ II
NCT04781855	Not yet recruiting	RT, R/R CLL	50	Ipilimumab, Ibrutinib, Nivolumab	Phase I
NCT03884998	Recruiting	RT, Transformed iNHL	21	Copanlisib, Nivolumab	Phase I
NCT04082897	Recruiting	RT	28	Obinutuzumab, Atezolizumab, Venetoclax	Phase II
NCT02846623	Recruiting	RT, R/R CLL	65	Atezolizumab, Obinutuzumab, Venetoclax	Phase II
NCT03892044	Active, not recruiting	RT, Transformed FL	7	Duvelisib, Nivolumab	Phase I
NCT04978779	Recruiting	RT, R/R CLL	54	VIP152	Phase I
NCT00304005	Completed	RT, R/R CLL	35	VNP40101M	Phase I/ II
NCT02029443	Active, not recruiting	RT, R/R CLL	306	Acalabrutinib	Phase I/ II
NCT02005289	Active, not recruiting	RT, R/R CLL	41	MOR00208, Lenalidomide	Phase II
NCT05458297	Recruiting	RT, R/R CLL, R/R MCL, R/R FL	260	Zilovertamab Vedotin (MK-2140), Nemtabrutinib (MK-1026)	Phase II
NCT04305444	Recruiting	RT, R/R CLL, R/R DLBCL, R/R FL	120	DTRM-555	Phase II
NCT04771572	Recruiting	RT, R/R CLL, R/R MDS, R/R AML, R/R ALL, R/R MF	100	LP-118	Phase I
NCT04806035	Recruiting	RT, R/R B-CL	60	TG-1801, Ublituximab	Phase I
NCT05107674	Recruiting	RT, R/R CLL, R/R DLBCL, EOC, GEJ, HNSCC, NSCLC, mCRPC, MPM, TNBC, MSS CRC	268	NX-1607	Phase I
NCT03162536	Active, not recruiting	RT, R/R B-CL	190	Nemtabrutinib (MK-1026)	Phase I/ II
NCT03833180	Recruiting	RT, R/R CLL, R/R B-CL, R/R T-CL, R/R AML, R/R ALL	330	Zilovertamab Vedotin (MK-2140)	Phase I
NCT03263637	Completed	RT, R/R CLL, R/R B-CL, R/R T-CL, R/R MM, R/R MDS, R/R AML, R/R ALL	44	AZD4573	Phase I
NCT05025800	Recruiting	RT, R/R B-CL	52	ALX148	Phase I/ II
NCT05176691	Recruiting	RT, R/R CLL, R/R B-CL	168	HMPL-760	Phase I
NCT02362035	Active, not recruiting	RT, R/R B-CL, R/R MM,	161	Acalabrutinib, Pembrolizumab	Phase I/ II
NCT03479268	Active, not recruiting	RT, R/R CLL, R/R B-CL	18	Pevedonistat, Ibrutinib	Phase I
NCT03010358	Completed	RT, R/R CLL, R/R B-CL	24	Entospletinib, Obinutuzumab	Phase I/ II
NCT02530515	Completed	RT, R/R CLL	8	Ex vivo-activated autologous lymph node lymphocytes infusion	Phase II
NCT02332980	Active, not recruiting	RT, R/R CLL, R/R B-CL	65	Ibrutinib, Idelalisib, Pembrolizumab	Phase II
NCT02924402	Recruiting	RT, R/R CLL, R/R B-CL	160	XmAb13676	Phase I



ALL, acute lymphoblastic leukemia; AML, acute myeloid leukemia; B-CL, B-cell lymphoma; CLL, chronic lymphocytic leukemia; DLBCL, diffuse large B-cell lymphoma; EOC, epithelial ovarian cancer, FL, follicular lymphoma; GEJ, gastric/gastroesophageal junction; HNSCC, squamous cell carcinoma of the head and neck; iNHL, indolent non-Hodgkin lymphoma; MCL, mantle cell lymphoma; mCRPC, metastatic castration-resistant prostate cancer; MDS, myelodysplastic syndrome; MF, myelofibrosis; MM, multiple myeloma; MPM, malignant pleural mesothelioma; MSS CRC, microsatellite stable colorectal cancer; NSCLC, non-small lung cancer RT, richter transformation; R/R, relapsed/refractory; T-CL, T-cell lymphoma; TNBC, triple-negative breast cancer.

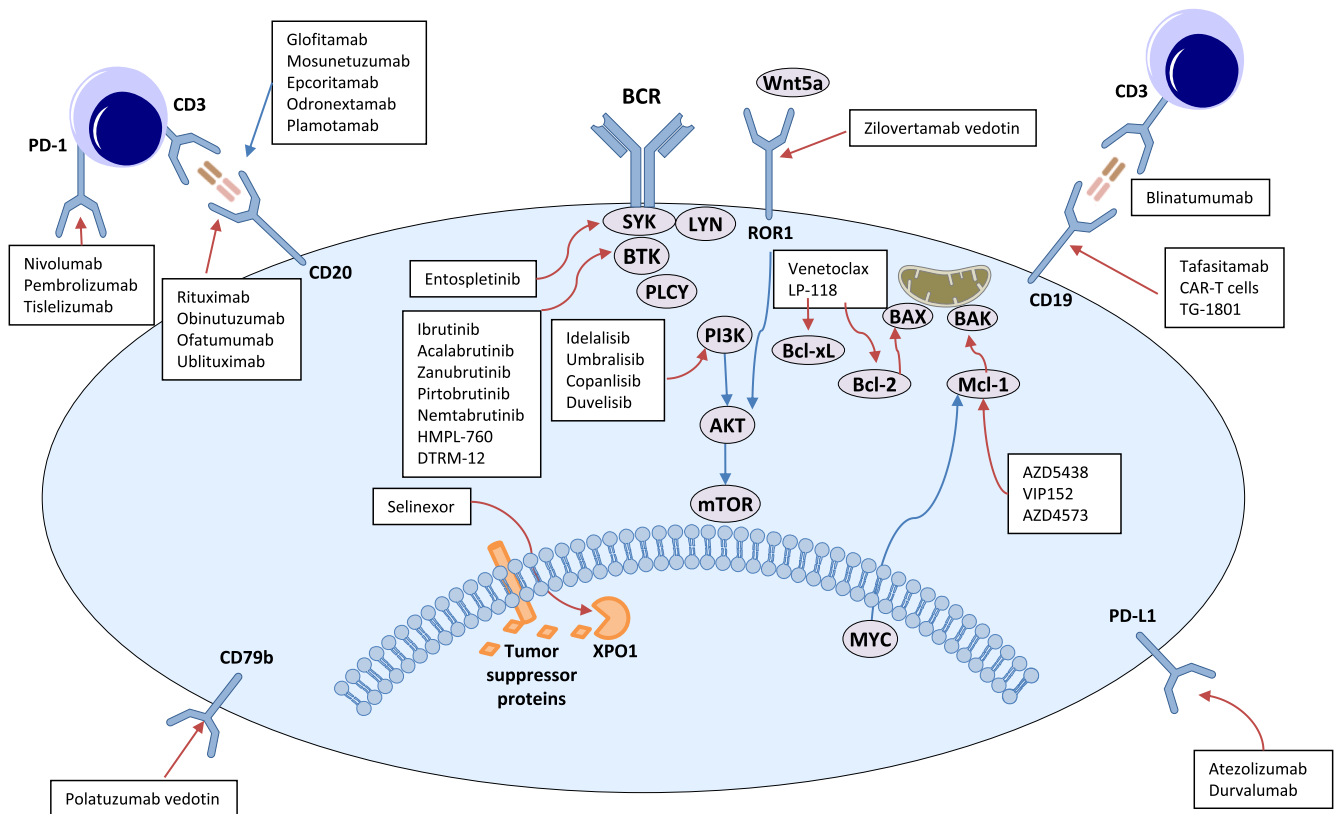


Fig. 4. Novel therapeutic targets in Richter transformation.

through CAR T-cell infusion. Regarding efficacy, ORR was 89 % (56 % CR). Cytokine release syndrome was low grade but there were 3 patients with grade  $\geq 3$  immune effector cell-associated neurotoxicity syndrome (ICANS) [34].

These studies include small numbers and limited follow-up but are proof-of-concept that CAR T-cell therapy is a treatment strategy with significant potential in RT patients, even if high-risk cytogenetics are present.

**Bispecific antibodies**

There is limited data on the use of bispecific antibodies in the specific setting of RT, and much of the available data is usually embedded in trials exploring many LBCL subtypes.

Blinatumomab, a CD19/CD3 bispecific antibody constructed out of two single-chain variable fragments (scFv), was tested in 9 patients with R/R RT. Four patients had a reduction in nodal disease and 1 patient achieved a durable CR. Interestingly, the patient who achieved CR had the lowest levels of immune checkpoint expression [180]. There is also data in the front-line setting from a phase 2 multicenter study reporting results of 18 RT patients who failed to achieve a CR after 2 cycles of R-CHOP. In terms of efficacy, ORR was 44 %, with 4 (22 %) patients in CR. Regarding toxicity, fever was reported in 4 (22 %) patients and 5 (28 %) experienced reversible neurotoxicity [181].

Glofitamab has extensive data from a phase I trial supporting its role in aggressive NHL. This trial included 10 patients with RT and efficacy results appeared similar to the overall population [182]. Mosunetuzumab, another CD20/CD3 bispecific, also has reported activity from a

phase I trial which included 5 patients with RT, with data not specifically described for this subgroup [183]. Finally, another CD20-CD3 bispecific antibody that has recently demonstrated encouraging results is epcoritamab (NCT04623541). Preliminary efficacy results of epcoritamab in monotherapy in LBCL-RT showed high overall and complete response rates (60 % and 50 %, respectively), with a tolerable safety profile [184].

**Future therapies**

A myriad of novel therapies and the combination of different mechanisms of action of new agents are currently under investigation in patients with RT (summarized in Table 4 and Fig. 4). Most of the treatments are combining new targeted therapies affecting relevant pathways in CLL with conventional chemoimmunotherapies [185–195]

**RT in the era of new targeted therapies**

Over the course of the last decade, there has been a profound transformation in the therapeutic milieu for patients with CLL [196]. At present, a substantial proportion of patients are receiving targeted therapies as their initial treatment modality. The data regarding the incidence of RT in patients receiving targeted therapies for CLL is limited, particularly in respect to the follow-up of these studies. Initial studies with targeted therapies, including those involving R/R CLL patients, reported higher rates of RT ranging from 6 % to 12 % [118,197–200]. However, data from clinical studies utilizing Bruton’s Tyrosine Kinase (BTK) or venetoclax inhibitors as first-line therapy

suggests similar frequencies as previously reported in the context of chemoimmunotherapy, with rates ranging from 0 to 3 % [201–207]. These observations suggest that the excessive incidence of RT identified in the initial studies with targeted therapies was probably due to that these treatments unmasked pre-existing transformations rather than direct-induced transformations. Finally, it should be acknowledged that new cases of RT will appear in patients receiving newer therapies for the CLL, therapies that can exert (see above) a selective pressure on certain clones. Consequently, in the management of these emerging cases, it is advisable to consider the use of alternative therapeutic approaches such as CAR-T or bispecific antibodies.

### Concluding remarks

During the last five years, a monumental progress has been made dissecting the genetics of the RT, identifying patterns of clonal evolution, clinical progression, and therapeutic resistance. Also, criteria for diagnosis and assessment of this severe complication has been clarified, thus simplifying the evaluation of future therapeutic strategies. Treatment of RT remains a medical need, with few patients attaining durable responses with therapeutic strategies currently available. The progress in understanding the biology of the disease and in the emergence of targeted therapies is opening the door to a better management of this complication, particularly in the setting of CAR-T therapies and T-cell engagers. Finally, the recent evidence that minute clones of RT are present at early stages of the CLL opens the door to conduct early interventions in these patients, when the heterogeneity and abundance of different subclones is still reduced. These early interventions should be carefully assess considering that some patients can develop RT under targeted therapies.

### Authors' disclosures

P.A. has received honoraria from Janssen, Roche, Celgene, AbbVie, Incyte, Beigene and AstraZeneca. F.N. has received honoraria from Janssen, AbbVie, and SOPHiA GENETICS for speaking at educational activities. G.I. Honoraria: Novartis, Roche, Kite/Gilead, Bristol-Myers Squibb, Abbvie, Janssen, Sandoz, Miltenyi, AstraZeneca. A.C. has received honoraria from AstraZeneca, Janssen and Jazz Pharmaceuticals. F.B. has received honoraria and research grants from Roche, Celgene, Takeda, AstraZeneca, Novartis, AbbVie, Lilly, Beigene, and Janssen.

All remaining authors have declared no conflicts of interest.

### Authors' contributions

All authors wrote and revised the manuscript.

### CRediT authorship contribution statement

**Pau Abrisqueta:** Conceptualization, Project administration, Supervision, Validation, Writing – original draft, Writing – review & editing. **Francesc Bosch:** Conceptualization, Data curation, Supervision, Validation, Writing – original draft, Writing – review & editing.

### Declaration of Competing Interest

The authors declare that they have no known competing financial interests or personal relationships that could have appeared to influence the work reported in this paper.

### Acknowledgements

This work was supported in part by the Instituto de Salud Carlos III, Fondo de Investigaciones Sanitarias [PI17/00943, F.B, PI18/01392, P. A.], and Gilead Fellowships, United States [GLD18/00047, F.B.] and

Fundació la Marató de TV3, Spain [201905-30-31 F.B.]. F.N. acknowledges research support from the American Association for Cancer Research (2021 AACR-Amgen Fellowship in Clinical/Translational Cancer Research, 21-40-11-NADE), the European Hematology Association (EHA Junior Research Grant 2021, RG-202012-00245), the Lady Tata Memorial Trust, India (International Award for Research in Leukaemia 2021–2022, LADY\_TATA\_21\_3223).

### References

- [1] Swerdlow SH, Campo E, Pileri SA, Harris NL, Stein H, Siebert R, et al. The 2016 revision of the World Health Organization classification of lymphoid neoplasms. *Blood* 2016;127(20):2375–90.
- [2] Richter MN. Generalized reticular cell sarcoma of lymph nodes associated with lymphatic leukemia. *Am J Pathol* 1928;4(4):285–92.7.
- [3] WHO classification of tumours of haematopoietic and lymphoid tissues. Lyon: International Agency for Research on Cancer; 2017.
- [4] Alaggio R, Amador C, Anagnostopoulos I, Attygalle AD, Araujo IBO, Berti E, et al. The 5th edition of the World Health Organization classification of haematolymphoid tumours: lymphoid neoplasms. *Leukemia* 2022;36(7):1720–48.
- [5] Campo E, Jaffe ES, Cook JR, Quintanilla-Martinez L, Swerdlow SH, Anderson KC, et al. The International Consensus Classification of Mature Lymphoid Neoplasms: a report from the Clinical Advisory Committee. *Blood* 2022;140(11):1229–53.
- [6] Parikh SA, Rabe KG, Call TG, Zent CS, Habermann TM, Ding W, et al. Diffuse large B-cell lymphoma (Richter syndrome) in patients with chronic lymphocytic leukaemia (CLL): a cohort study of newly diagnosed patients. *Br J Haematol* 2013;162(6):774–82.
- [7] Chigrinova E, Rinaldi A, Kwee I, Rossi D, Rancoita PM, Strefford JC, et al. Two main genetic pathways lead to the transformation of chronic lymphocytic leukemia to Richter syndrome. *Blood* 2013;122(15):2673–82.
- [8] Rossi D, Spina V, Deambrogi C, Rasi S, Laurenti L, Stamatopoulos K, et al. The genetics of Richter syndrome reveals disease heterogeneity and predicts survival after transformation. *Blood* 2011;117(12):3391–401.
- [9] Rossi D, Spina V, Cerri M, Rasi S, Deambrogi C, De Paoli L, et al. Stereotyped B-cell receptor is an independent risk factor of chronic lymphocytic leukemia transformation to Richter syndrome. *Clin Cancer Res* 2009;15(13):4415–22.
- [10] Rossi D, Rasi S, Spina V, Fangazio M, Monti S, Greco M, et al. Different impact of NOTCH1 and SF3B1 mutations on the risk of chronic lymphocytic leukemia transformation to Richter syndrome. *Br J Haematol* 2012;158(3):426–9.
- [11] Mao Z, Quintanilla-Martinez L, Raffeld M, Richter M, Krugmann J, Burek C, et al. IgVH mutational status and clonality analysis of Richter's transformation: diffuse large B-cell lymphoma and Hodgkin lymphoma in association with B-cell chronic lymphocytic leukemia (B-CLL) represent 2 different pathways of disease evolution. *Am J Surg Pathol* 2007;31(10):1605–14.
- [12] Chan KL, Blombery P, Jones K, Lade S, Carney D, Tran H, et al. Plasmablastic Richter transformation as a resistance mechanism for chronic lymphocytic leukaemia treated with BCR signalling inhibitors. *Br J Haematol* 2017;177(2):324–8.
- [13] Martinez D, Valera A, Perez NS, Sua Villegas LF, Gonzalez-Farre B, Sole C, et al. Plasmablastic transformation of low-grade B-cell lymphomas: report on 6 cases. *Am J Surg Pathol* 2013;37(2):272–81.
- [14] Parikh SA, Habermann TM, Chaffee KG, Call TG, Ding W, Leis JF, et al. Hodgkin transformation of chronic lymphocytic leukemia: Incidence, outcomes, and comparison to de novo Hodgkin lymphoma. *Am J Hematol* 2015;90(4):334–8.
- [15] Stephens DM, Boucher K, Kander E, Parikh SA, Parry EM, Shadman M, et al. Hodgkin lymphoma arising in patients with chronic lymphocytic leukemia: outcomes from a large multi-center collaboration. *Haematologica* 2021;106(11):2845–52.
- [16] Fabbri G, Khiabanian H, Holmes AB, Wang J, Messina M, Mullighan CG, et al. Genetic lesions associated with chronic lymphocytic leukemia transformation to Richter syndrome. *J Exp Med* 2013;210(11):2273–88.
- [17] Nadeu F, Royo R, Massoni-Badosa R, Playa-Albinyana H, Garcia-Torre B, Duran-Ferrer M, et al. Detection of early seeding of Richter transformation in chronic lymphocytic leukemia. *Nat Med* 2022;28(8):1662–71.
- [18] Parry EM, Leshchiner I, Guièze R, Johnson C, Tausch E, Parikh SA, et al. Evolutionary history of transformation from chronic lymphocytic leukemia to Richter syndrome. *Nat Med* 2023;29(1):158–69.
- [19] Abrisqueta P, Delgado J, Alcoceba M, Oliveira AC, Loscertales J, Hernández-Rivas JA, et al. Clinical outcome and prognostic factors of patients with Richter syndrome: real-world study of the Spanish Chronic Lymphocytic Leukemia Study Group (GELLC). *Br J Haematol* 2020;190(6):854–63.
- [20] Tsimberidou AM, O'Brien S, Khouri I, Giles FJ, Kantarjian HM, Champlin R, et al. Clinical outcomes and prognostic factors in patients with Richter's syndrome treated with chemotherapy or chemoimmunotherapy with or without stem-cell transplantation. *J Clin Oncol* 2006;24(15):2343–51.
- [21] Langerbeins P, Busch R, Anheier N, Dürrig J, Bergmann M, Goebeler ME, et al. Poor efficacy and tolerability of R-CHOP in relapsed/refractory chronic lymphocytic leukemia and Richter transformation. *Am J Hematol* 2014;89(12):E239–43.
- [22] Eyre TA, Clifford R, Bloor A, Boyle L, Roberts C, Cabes M, et al. NCRI phase II study of CHOP in combination with ofatumumab in induction and maintenance in newly diagnosed Richter syndrome. *Br J Haematol* 2016;175(1):43–54.

- [23] Dabaja BS, O'Brien SM, Kantarjian HM, Cortes JE, Thomas DA, Albitar M, et al. Fractionated cyclophosphamide, vincristine, liposomal daunorubicin (daunoXome), and dexamethasone (hyperCVXD) regimen in Richter's syndrome. *Leuk Lymphoma* 2001;42(3):329–37.
- [24] Tsimberidou AM, Kantarjian HM, Cortes J, Thomas DA, Faderl S, Garcia-Manero G, et al. Fractionated cyclophosphamide, vincristine, liposomal daunorubicin, and dexamethasone plus rituximab and granulocyte-macrophage-colony stimulating factor (GM-CSF) alternating with methotrexate and cytarabine plus rituximab and GM-CSF in patients with Richter syndrome or fludarabine-refractory chronic lymphocytic leukemia. *Cancer* 2003;97(7):1711–20.
- [25] Tsimberidou AM, Wierda WG, Wen S, Plunkett W, O'Brien S, Kipps TJ, et al. Phase I-II clinical trial of oxaliplatin, fludarabine, cytarabine, and rituximab therapy in aggressive relapsed/refractory chronic lymphocytic leukemia or Richter syndrome. *Clin Lymphoma Myeloma Leuk* 2013;13(5):568–74.
- [26] Cwynarski K, van Biezen A, de Wreede L, Stilgenbauer S, Bunjes D, Metzner B, et al. Autologous and allogeneic stem-cell transplantation for transformed chronic lymphocytic leukemia (Richter's syndrome): a retrospective analysis from the chronic lymphocytic leukemia subcommittee of the chronic leukemia working party and lymphoma working party of the European Group for Blood and Marrow Transplantation. *J Clin Oncol* 2012;30(18):2211–7.
- [27] El-Asmar J, Kharfan-Dabaja MA. Hematopoietic cell transplantation for Richter syndrome. *Biol Blood Marrow Transplant* 2016;22(11):1938–44.
- [28] Kharfan-Dabaja MA, Kumar A, Stingo FE, Khimani F, Hussaini M, Ayala E, et al. Allogeneic hematopoietic cell transplantation for Richter syndrome: a single-center experience. *Clin Lymphoma Myeloma Leuk* 2018;18(1):e35–9.
- [29] Davids MS, Roberts AW, Seymour JF, Pagel JM, Kahl BS, Wierda WG, et al. Phase I first-in-human study of venetoclax in patients with relapsed or refractory non-Hodgkin lymphoma. *J Clin Oncol* 2017;35(8):826–33.
- [30] Iannello A, Vitale N, Coma S, Arruga F, Chadburn A, Di Napoli A, et al. Synergistic efficacy of the dual PI3K- $\delta/\gamma$  inhibitor duvelisib with the Bcl-2 inhibitor venetoclax in Richter syndrome PDX models. *Blood* 2021;137(24):3378–89.
- [31] Eyre TA, Schuh A, Wierda WG, Brown JR, Ghia P, Pagel JM, et al. Acalabrutinib monotherapy for treatment of chronic lymphocytic leukaemia (ACE-CL-001): analysis of the Richter transformation cohort of an open-label, single-arm, phase 1–2 study. *Lancet Haematol* 2021;8(12):e912–21.
- [32] Ding W, LaPlant BR, Call TG, Parikh SA, Leis JF, He R, et al. Pembrolizumab in patients with CLL and Richter transformation or with relapsed CLL. *Blood* 2017;129(26):3419–27.
- [33] Gauthier J, Hirayama AV, Purushe J, Hay KA, Lymp J, Li DH, et al. Feasibility and efficacy of CD19-targeted CAR T cells with concurrent ibrutinib for CLL after ibrutinib failure. *Blood* 2020;135(19):1650–60.
- [34] Kittai AS, Bond DA, William B, Saad A, Penza S, Efebera Y, et al. Clinical activity of axicabtagene ciloleucel in adult patients with Richter syndrome. *Blood Adv* 2020;4(19):4648–52.
- [35] Benjamini O, Shimoni A, Besser M et al. Safety and efficacy of CD19-CAR T cells in Richter's transformation after targeted therapy for chronic lymphocytic leukemia. In: American Society of hematology 62nd annual meeting and exposition. Abstract 545.2020.
- [36] Ben-Dali Y, Hleuhel MH, da Cunha-Bang C, Brieghel C, Poulsen CB, Clasen-Linde E, et al. Richter's transformation in patients with chronic lymphocytic leukaemia: a Nationwide Epidemiological Study. *Leuk Lymphoma* 2020;61(6):1435–44.
- [37] Elnair R, Ellithi M, Kallam A, Shostrom V, Bociek RG. Outcomes of Richter's transformation of chronic lymphocytic leukemia/small lymphocytic lymphoma (CLL/SLL): an analysis of the SEER database. *Ann Hematol* 2021;100(10):2513–9.
- [38] Lenartova A, Randen U, Johannesen TB, Tjønnfjord GE. Richter syndrome epidemiology in a large population based chronic lymphocytic leukemia cohort from Norway. *Cancer Epidemiol* 2019;60:128–33.
- [39] Maurer C, Langerbeins P, Bahlo J, Cramer P, Fink AM, Pflug N, et al. Effect of first-line treatment on second primary malignancies and Richter's transformation in patients with CLL. *Leukemia* 2016;30(10):2019–25.
- [40] Al-Sawaf O, Robrecht S, Bahlo J, Fink AM, Cramer P, Tresckow V, et al. Richter transformation in chronic lymphocytic leukemia (CLL)-a pooled analysis of German CLL Study Group (GCLLSG) front line treatment trials. *Leukemia* 2021;35(1):169–76.
- [41] Villamor N, Conde L, Martínez-Trillos A, Cazorla M, Navarro A, Beà S, et al. NOTCH1 mutations identify a genetic subgroup of chronic lymphocytic leukemia patients with high risk of transformation and poor outcome. *Leukemia* 2013;27(5):1100–6.
- [42] Visentin A, Bonaldi L, Rigolin GM, Mauro FR, Martines A, Frezzato F, et al. The complex karyotype landscape in chronic lymphocytic leukemia allows the refinement of the risk of Richter syndrome transformation. *Haematologica* 2022;107(4):868–76.
- [43] Federmann B, Mueller MR, Steinhilber J, Horger MS, Fend F. Diagnosis of Richter transformation in chronic lymphocytic leukemia: histology tips the scales. *Ann Hematol* 2018.
- [44] Allan JN, Furman RR. Current trends in the management of Richter's syndrome. *Int J Hematol Oncol* 2018;7(4):LJH09.
- [45] Bruzzi JF, Macapinlac H, Tsimberidou AM, Truong MT, Keating MJ, Marom EM, et al. Detection of Richter's transformation of chronic lymphocytic leukemia by PET/CT. *J Nucl Med* 2006;47(8):1267–73.
- [46] Falchi L, Keating MJ, Marom EM, Truong MT, Schlette EJ, Sargent RL, et al. Correlation between FDG/PET, histology, characteristics, and survival in 332 patients with chronic lymphoid leukemia. *Blood* 2014;123(18):2783–90.
- [47] Mauro FR, Chauvie S, Paoloni F, Biggi A, Cimino G, Rago A, et al. Diagnostic and prognostic role of PET/CT in patients with chronic lymphocytic leukemia and progressive disease. *Leukemia* 2015;29(6):1360–5.
- [48] Parikh SA, Kay NE, Shanafelt TD. How we treat Richter syndrome. *Blood* 2014;123(11):1647–57.
- [49] Wang Y, Ding W. Richter transformation of chronic lymphocytic leukemia in the era of novel agents. *Clin Adv Hematol Oncol* 2020;18(6):348–57.
- [50] Petrakova A, Turcsanyi P, Papajik T, Kriegova E. Revisiting Richter transformation in the era of novel CLL agents. *Blood Rev* 2021;49:100824.
- [51] Gascoyne RDXIV. The pathology of transformation of indolent B cell lymphomas. *Hematol Oncol* 2015;33(Suppl. 1):75–9.
- [52] Rossi D, Spina V, Gaidano G. Biology and treatment of Richter syndrome. *Blood* 2018;131(25):2761–72.
- [53] Soilleux EJ, Wotherspoon A, Eyre TA, Clifford R, Cabes M, Schuh AH. Diagnostic dilemmas of high-grade transformation (Richter's syndrome) of chronic lymphocytic leukaemia: results of the phase II National Cancer Research Institute CHOP-OR clinical trial specialist haemato-pathology central review. *Histopathology* 2016;69(6):1066–76.
- [54] Fan L, Wang L, Zhang R, Fang C, Zhu DX, Wang YH, et al. Richter transformation in 16 of 149 Chinese patients with chronic lymphocytic leukemia. *Leuk Lymphoma* 2012;53(9):1749–56.
- [55] Woroniecka R, Rymkiewicz G, Grygalewicz B, Blachnio K, Rygiel J, Jarmuż-Szymczak M, et al. Cytogenetic and flow cytometry evaluation of Richter syndrome reveals MYC, CDKN2A, IGH alterations with loss of CD52, CD62L and increase of CD71 antigen expression as the most frequent recurrent abnormalities. *Am J Clin Pathol* 2015;143(1):25–35.
- [56] Agbay RL, Jain N, Loghavi S, Medeiros LJ, Khoury JD. Histologic transformation of chronic lymphocytic leukemia/small lymphocytic lymphoma. *Am J Hematol* 2016;91(10):1036–43.
- [57] Wang L, Aghel A, Peterson B, Wang-Rodriguez J, Wang HY, Zhao XF. Richter transformation with c-MYC overexpression: report of three cases. *Int J Clin Exp Path* 2015;8(6):7540–6.
- [58] Wang Y, Tschauschner MA, Rabe KG, Call TG, Leis JF, Kenderian SS, et al. Clinical characteristics and outcomes of Richter transformation: experience of 204 patients from a single center. *Haematologica* 2019.
- [59] Matolcsy A, Chadburn A, Knowles DM. De novo CD5-positive and Richter's syndrome-associated diffuse large B cell lymphomas are genotypically distinct. *Am J Pathol* 1995;147(1):207–16.
- [60] He R, Ding W, Viswanatha DS, Chen D, Shi M, Van Dyke D, et al. PD-1 Expression in Chronic Lymphocytic Leukemia/Small Lymphocytic Lymphoma (CLL/SLL) and Large B-cell Richter Transformation (DLBCL-RT): A Characteristic Feature of DLBCL-RT and Potential Surrogate Marker for Clonal Relatedness. *Am J Surg Pathol* 2018;42(7):843–54.
- [61] Behdad A, Griffin B, Chen YH, Ma S, Kelemen K, Lu X, et al. PD-1 is highly expressed by neoplastic B-cells in Richter transformation. *Br J Haematol* 2019;185(2):370–3.
- [62] Cordone I, Matutes E, Catovsky D. Monoclonal antibody Ki-67 identifies B and T cells in cycle in chronic lymphocytic leukemia: correlation with disease activity. *Leukemia* 1992;6(9):902–6.
- [63] Giné E, Martínez A, Villamor N, López-Guillermo A, Camos M, Martínez D, et al. Expanded and highly active proliferation centers identify a histological subtype of chronic lymphocytic leukemia ("accelerated" chronic lymphocytic leukemia) with aggressive clinical behavior. *Haematologica* 2010;95(9):1526–33.
- [64] Karlsson C, Norin S, Kimby E, Sander B, Porwit Macdonald A, Nilsson B, et al. Alemtuzumab as first-line therapy for B-cell chronic lymphocytic leukemia: long-term follow-up of clinical effects, infectious complications and risk of Richter transformation. *Leukemia* 2006;20(12):2204–7.
- [65] Lepretre S, Aurran T, Mahé B, Gazin B, Tournilhac O, Maisonneuve H, et al. Excess mortality after treatment with fludarabine and cyclophosphamide in combination with alemtuzumab in previously untreated patients with chronic lymphocytic leukemia in a randomized phase 3 trial. *Blood* 2012;119(22):5104–10.
- [66] Quinquenel A, Aurran-Schleinitz T, Clavert A, Cymbalista F, Dartigeas C, Davi F, et al. Diagnosis and Treatment of Chronic Lymphocytic Leukemia: Recommendations of the French CLL Study Group (FILO). *Hemasphere*. 2020;4(5):e473.
- [67] Jamrozik K, Grzybowska-Izydorczyk O, Jesionek-Kupnicka D, Gora-Tybor J, Robak T. Poor prognosis of Hodgkin variant of Richter transformation in chronic lymphocytic leukemia treated with cladribine. *Br J Haematol* 2012;158(2):286–8.
- [68] Bockorny B, Codreanu I, Dasanu CA. Hodgkin lymphoma as Richter transformation in chronic lymphocytic leukaemia: a retrospective analysis of world literature. *Br J Haematol* 2012;156(1):50–66.
- [69] Xiao W, Chen WW, Sorbara L, Davies-Hill T, Pittaluga S, Raffeld M, et al. Hodgkin lymphoma variant of Richter transformation: morphology, Epstein-Barr virus status, clonality, and survival analysis-with comparison to Hodgkin-like lesion. *Hum Pathol* 2016;55:108–16.
- [70] de Leval L, Vivario M, De Prijck B, Zhou Y, Boniver J, Harris NL, et al. Distinct clonal origin in two cases of Hodgkin's lymphoma variant of Richter's syndrome associated With EBV infection. *Am J Surg Pathol* 2004;28(5):679–86.
- [71] King RL, Gupta A, Kurtin PJ, Ding W, Call TG, Rabe KG, et al. Chronic lymphocytic leukemia (CLL) with Reed-Sternberg-like cells vs Classic Hodgkin lymphoma transformation of CLL: does this distinction matter? *Blood Cancer J* 2022;12(1):18.
- [72] Pan Z, Xie Q, Repertinger S, Richendollar BG, Chan WC, Huang Q. Plasmablastic transformation of low-grade CD5+ B-cell lymphoproliferative disorder with MYC gene rearrangements. *Hum Pathol* 2013;44(10):2139–48.



- [73] Robak T, Urbańska-Rys H, Strzelecka B, Krykowski E, Bartkowiak J, Błoński JZ, et al. Plasmablastic lymphoma in a patient with chronic lymphocytic leukemia heavily pretreated with cladribine (2-CdA): an unusual variant of Richter's syndrome. *Eur J Haematol* 2001;67(5-6):322-7.
- [74] Gasljevic G, Grat M, Kloboves Prevodnik V, Grcar Kuzmanov B, Gazic B, Lovrecic L, et al. Chronic lymphocytic leukemia with divergent Richter's transformation into a clonally related classical Hodgkin's and plasmablastic lymphoma: a case report. *Case Rep Oncol* 2020;13(1):120-9.
- [75] Mohamed AN, Compean R, Dan ME, Smith MR, Al-Katib A. Clonal evolution of chronic lymphocytic leukemia to acute lymphoblastic leukemia. *Cancer Genet Cytogenet* 1996;86(2):143-6.
- [76] Chakhachiro Z, Yin CC, Abruzzo LV, Aladily TN, Barron LL, Banks HE, et al. B-lymphoblastic leukemia in patients with chronic lymphocytic leukemia: a report of four cases. *Am J Clin Pathol* 2015;144(2):333-40.
- [77] Pistoia V, Roncella S, Di Celle PF, Sessarego M, Cutrona G, Cerruti G, et al. Emergence of a B-cell lymphoblastic lymphoma in a patient with B-cell chronic lymphocytic leukemia: evidence for the single-cell origin of the two tumors. *Blood* 1991;78(3):797-804.
- [78] Archimbaud E, Charrin C, Gentilhomme O, Rimokh R, Guyotat D, Fiere D, et al. Initial clonal acute lymphoblastic transformation of chronic lymphocytic leukemia with (11;14) and (8;12) chromosome translocations and acquired homozygosity. *Acta Haematol* 1988;79(3):168-73.
- [79] Skala SL, Ye JC, Stumph J, Macon WR, Quinones FR, Khachaturov V, et al. Combined tumors in hematology neoplasms: case series of histiocytic and Langerhans cell sarcomas arising from low-grade B-cell lymphoma. *Clin Pathol* 2019;12:2632010X19878410.
- [80] Fraser CR, Wang W, Gomez M, Zhang T, Mathew S, Furman RR, et al. Transformation of chronic lymphocytic leukemia/small lymphocytic lymphoma to interdigitating dendritic cell sarcoma: evidence for transdifferentiation of the lymphoma clone. *Am J Clin Pathol* 2009;132(6):928-39.
- [81] Shao H, Xi L, Raffeld M, Feldman AL, Ketterling RP, Knudson R, et al. Clonally related histiocytic/dendritic cell sarcoma and chronic lymphocytic leukemia/small lymphocytic lymphoma: a study of seven cases. *Mod Pathol* 2011;24(11):1421-32.
- [82] Skala SL, Lucas DR, Dewar R. Histiocytic sarcoma: review, discussion of transformation from B-cell lymphoma, and differential diagnosis. *Arch Pathol Lab Med* 2018;142(11):1322-9.
- [83] Rossi D, Gaidano G. Richter syndrome: pathogenesis and management. *Semin Oncol* 2016;43(2):311-9.
- [84] Quintanilla-Martinez L. The 2016 updated WHO classification of lymphoid neoplasias. *Hematol Oncol* 2017;35(Suppl 1):37-45.
- [85] Ciccone M, Agostinelli C, Rigolin GM, Piccaluga PP, Cavazzini F, Righi S, et al. Proliferation centers in chronic lymphocytic leukemia: correlation with cytogenetic and clinicobiological features in consecutive patients analyzed on tissue microarrays. *Leukemia* 2012;26(3):499-508.
- [86] Hampel PJ, Cherg HJ, Call TG, Ding W, Khanlari M, McPhail ED, et al. Incidental Richter transformation in chronic lymphocytic leukemia patients during temporary interruption of ibrutinib. *Blood Adv* 2020;4(18):4508-11.
- [87] Barnea Slonim L, Ma S, Behdad A, Chen Q. Pseudo-Richter transformation of chronic lymphocytic leukaemia/small lymphocytic lymphoma following ibrutinib interruption: a diagnostic pitfall. *Br J Haematol* 2020;191(1):e22-5.
- [88] Eling DJ, Johnson PA, Sharma S, Tufaro F, Kipps TJ. Chronic lymphocytic leukemia B-cells are highly sensitive to infection by herpes simplex virus-1 via herpesvirus-entry-mediator A. *Gene Ther* 2000;7(14):1210-6.
- [89] Gaffey MJ, Ben-Ezra JM, Weiss LM. Herpes simplex lymphadenitis. *Am J Clin Pathol* 1991;95(5):709-14.
- [90] Epstein JI, Ambinder RF, Kujahda FP, Pearlman SH, Reuter VE, Mann RB. Localized herpes simplex lymphadenitis. *Am J Clin Pathol* 1986;86(4):444-8.
- [91] Hodgson YA, Jones SG, Knight H, Sovani V, Fox CP. Herpes simplex necrotic lymphadenitis masquerading as Richter's transformation in treatment-naïve patients with chronic lymphocytic leukemia. *J Hematol* 2019;8(2):79-82.
- [92] Oo K, Xiao W, Hameed A, Xiao P. Concurrent herpes simplex viral lymphadenitis and chronic lymphocytic leukemia/small lymphocytic lymphoma, mimicking large-cell (Richter) transformation. *Leuk Lymphoma* 2009;50(9):1535-7.
- [93] Salem A, Loghavi S, Khoury JD, Agbay RL, Jorgensen JL, Medeiros LJ. Herpes simplex infection simulating Richter transformation: a series of four cases and review of the literature. *Histopathology* 2017;70(5):821-31.
- [94] Joseph L, Scott MA, Schichman SA, Zent CS. Localized herpes simplex lymphadenitis mimicking large-cell (Richter's) transformation of chronic lymphocytic leukemia/small lymphocytic lymphoma. *Am J Hematol* 2001;68(4):287-91.
- [95] Parmar V, Bayya M, Kak V. Herpes simplex virus causing necrotizing granulomatous lymphadenitis. *Cureus* 2022;14(3):e23709.
- [96] Boyer DF, Lindeman NI, Harris NL, Ferry JA. Peripheral T-cell lymphomas with cytotoxic phenotype in patients with chronic lymphocytic leukemia/small lymphocytic lymphoma. *Am J Surg Pathol* 2014;38(2):279-88.
- [97] Trimech M, Letourneau A, Missiaglia E, De Prijck B, Nagy-Hulliger M, Somja J, et al. Angioimmunoblastic T-Cell lymphoma and chronic lymphocytic leukemia/small lymphocytic lymphoma: a novel form of composite lymphoma potentially mimicking Richter syndrome. *Am J Surg Pathol* 2021;45(6):773-86.
- [98] Alomari A, Hui P, Xu M. Composite peripheral T-cell lymphoma not otherwise specified, and B-cell small lymphocytic lymphoma presenting with hemophagocytic lymphohistiocytosis. *Int J Surg Pathol* 2013;21(3):303-8.
- [99] Ibrahim F, Al Sabbagh A, Amer A, Soliman DS, Al Sabah H. Composite chronic lymphocytic leukemia/small lymphocytic lymphoma and mantle cell lymphoma; small cell variant: a real diagnostic challenge. Case presentation and review of literature. *Am J Case Rep* 2020;21:e921131.
- [100] Hoeller S, Zhou Y, Kanagal-Shamanna R, Xu-Monette ZY, Hoehn D, Bihl M, et al. Composite mantle cell lymphoma and chronic lymphocytic leukemia/small lymphocytic lymphoma: a clinicopathologic and molecular study. *Hum Pathol* 2013;44(1):110-21.
- [101] Mass J, Alobeid B. Composite mantle cell lymphoma and small lymphocytic lymphoma in a lymph node. *Blood* 2021;137(2):282.
- [102] Sun Y, Wang SA, Sun T. Composite mantle cell lymphoma and chronic lymphocytic leukemia/small lymphocytic lymphoma. *Cytometry B Clin Cytom* 2018;94(1):148-50.
- [103] Sokol L, Agosti SJ. Simultaneous manifestation of chronic lymphocytic leukemia (CLL) and hairy cell leukemia (HCL). *Am J Hematol* 2004;75(2):107-9.
- [104] Giné E, Bosch F, Villamor N, Rozman M, Colomer D, López-Guillermo A, et al. Simultaneous diagnosis of hairy cell leukemia and chronic lymphocytic leukemia/small lymphocytic lymphoma: a frequent association? *Leukemia* 2002;16(8):1454-9.
- [105] Obiorah IE, Francischetti IMB, Wang HW, Ahn IE, Wang W, Raffeld M, et al. Concurrent chronic lymphocytic leukemia/small lymphocytic lymphoma and hairy cell leukemia: clinical, pathologic and molecular features. *Leuk Lymphoma* 2020;61(13):3177-87.
- [106] Verma V, Giri S, Bhatt VR, Amador-Ortiz C, Armitage JO. Synchronous or metachronous hairy cell leukemia and chronic lymphocytic leukemia: a case series and literature review. *Front Oncol* 2016;6:270.
- [107] Bustoros M, Liechty B, Zagzag D, Liu C, Shepherd T, Gruber D, et al. A Rare case of composite dual extranodal marginal zone lymphoma and chronic lymphocytic leukemia/small lymphocytic lymphoma. *Front Neurol* 2018;9:267.
- [108] Ingen-Housz-Oro S, Franck N, Beneton N, Fauconneau A, Do-Pham G, Carlotti A, et al. Folliculotropic T-cell infiltrates associated with B-cell chronic lymphocytic leukaemia or MALT lymphoma may reveal either true mycosis fungoides or pseudolymphomatous reaction: seven cases and review of the literature. *J Eur Acad Dermatol Venereol* 2015;29(1):77-85.
- [109] Liu YA, Finn AJ, Subtil A. Primary cutaneous lymphomas in patients with chronic lymphocytic leukemia/small lymphocytic lymphoma (CLL/SLL): a series of 12 cases. *J Cutan Pathol* 2021;48(5):617-24.
- [110] Maughan C, Kolker S, Markus B, Young J. Leukemia cutis coexisting with dermatofibroma as the initial presentation of B-cell chronic lymphocytic leukemia/small lymphocytic lymphoma. *Am J Dermatopathol* 2014;36(1):e14-5.
- [111] Hull PR, Saxena A. Mycosis fungoides and chronic lymphocytic leukaemia-composite T-cell and B-cell lymphomas presenting in the skin. *Br J Dermatol* 2000;143(2):439-44.
- [112] Favini C, Talotta D, Almasri M, Andorno A, Rasi S, Adhineni R, et al. Clonally unrelated Richter syndrome are truly de novo diffuse large B-cell lymphomas with a mutational profile reminiscent of clonally related Richter syndrome. *Br J Haematol* 2022;198(6):1016-22.
- [113] Beà S, López-Guillermo A, Ribas M, Puig X, Pinyol M, Carrió A, et al. Genetic imbalances in progressed B-cell chronic lymphocytic leukemia and transformed large-cell lymphoma (Richter's syndrome). *Am J Pathol* 2002;161(3):957-68.
- [114] Scandurra M, Rossi D, Deambroggi C, Rancoita PM, Chigrinova E, Mian M, et al. Genomic profiling of Richter's syndrome: recurrent lesions and differences with de novo diffuse large B-cell lymphomas. *Hematol Oncol* 2010;28(2):62-7.
- [115] De Paoli L, Cerri M, Monti S, Rasi S, Spina V, Brusca A, et al. MGA, a suppressor of MYC, is recurrently inactivated in high risk chronic lymphocytic leukemia. *Leuk Lymphoma* 2013;54(5):1087-90.
- [116] Klintman J, Appleby N, Stamatopoulos B, Ridout K, Eyre TA, Robbe P, et al. Genomic and transcriptomic correlates of Richter transformation in chronic lymphocytic leukemia. *Blood* 2021;137(20):2800-16.
- [117] Miller CR, Ruppert AS, Heerema NA, Maddocks KJ, Labanowska J, Breidenbach H, et al. Near-tetraploidy is associated with Richter transformation in chronic lymphocytic leukemia patients receiving ibrutinib. *Blood Adv* 2017;1(19):1584-8.
- [118] Ahn IE, Underbayev C, Albitar A, Herman SE, Tian X, Maric I, et al. Clonal evolution leading to ibrutinib resistance in chronic lymphocytic leukemia. *Blood* 2017;129(11):1469-79.
- [119] Kadri S, Lee J, Fitzpatrick C, Galanina N, Sukhanova M, Venkataraman G, et al. Clonal evolution underlying leukemia progression and Richter transformation in patients with ibrutinib-relapsed CLL. *Blood Adv* 2017;1(12):715-27.
- [120] Herling CD, Abedpour N, Weiss J, Schmitt A, Jachimowicz RD, Merkel O, et al. Clonal dynamics towards the development of venetoclax resistance in chronic lymphocytic leukemia. *Nat Commun* 2018;9(1):727.
- [121] Kanagal-Shamanna R, Jain P, Patel KP, Routbort M, Bueso-Ramos C, Alhalouli T, et al. Targeted multigene deep sequencing of Bruton tyrosine kinase inhibitor-resistant chronic lymphocytic leukemia with disease progression and Richter transformation. *Cancer* 2019;125(4):559-74.
- [122] Knisbacher BA, Lin Z, Hahn CK, Nadeu F, Duran-Ferrer M, Stevenson KE, et al. Molecular map of chronic lymphocytic leukemia and its impact on outcome. *Nat Genet* 2022.
- [123] Schmitz R, Wright GW, Huang DW, Johnson CA, Phelan JD, Wang JQ, et al. Genetics and Pathogenesis of Diffuse Large B-Cell Lymphoma. *N Engl J Med* 2018;378(15):1396-407.
- [124] Chapuy B, Stewart C, Dunford AJ, Kim J, Kamburov A, Redd RA, et al. Molecular subtypes of diffuse large B cell lymphoma are associated with distinct pathogenic mechanisms and outcomes. *Nat Med* 2018;24(5):679-90.
- [125] Chakraborty S, Martinez C, Porro F, Fortunati I, Bonato A, Dimishkovska M, et al. B-cell receptor signaling and genetic lesions in TP53 and CDKN2A/CDKN2B cooperate in Richter transformation. *Blood* 2021;138(12):1053-66.

- [126] Martines C, Chakraborty S, Vujovikj M, Gobessi S, Vaisitti T, Deaglio S, et al. Macrophage- and BCR- but not TLR-derived signals support the growth of CLL and Richter Syndrome murine models in vivo. *Blood* 2022.
- [127] Kohlhaas V, Blakemore SJ, Al-Maarri M, Nickel N, Pal M, Roth A, et al. Active Akt signaling triggers CLL toward Richter transformation via overactivation of Notch1. *Blood* 2021;137(5):646–60.
- [128] Ten Hacken E, Sewastianik T, Yin S, Hoffmann GB, Gruber M, Clement K, et al. In vivo modeling of CLL transformation to Richter syndrome reveals convergent evolutionary paths and therapeutic vulnerabilities. *Blood Cancer Discov* 2023;4(2):150–69.
- [129] Broséus J, Hergalant S, Vogt J, Tausch E, Kreuz M, Mottok A, et al. Molecular characterization of Richter syndrome identifies de novo diffuse large B-cell lymphomas with poor prognosis. *Nat Commun* 2023;14(1):309.
- [130] Monti S, Savage KJ, Kutok JL, Feuerhake F, Kurtin P, Mihm M, et al. Molecular profiling of diffuse large B-cell lymphoma identifies robust subtypes including one characterized by host inflammatory response. *Blood* 2005;105(5):1851–61.
- [131] Caro P, Kishan AU, Norberg E, Stanley IA, Chapuy B, Ficarro SB, et al. Metabolic signatures uncover distinct targets in molecular subsets of diffuse large B cell lymphoma. *Cancer Cell* 2012;22(4):547–60.
- [132] Marvynin K, Tjønnfjord EB, Breland UM, Tjønnfjord GE. Transformation to plasmablastic lymphoma in CLL upon ibrutinib treatment. *BMJ Case Rep* 2020;13(9).
- [133] Gángó A, Kiss R, Farkas P, Hanna E, Demeter J, Deák B, et al. Morphologic and molecular analysis of Richter syndrome in chronic lymphocytic leukaemia patients treated with ibrutinib or venetoclax. *Pathology* 2022;54(1):95–103.
- [134] Li F, Wang Y, Zeller KI, Potter JJ, Wonsey DR, O'Donnell KA, et al. Myc stimulates nuclearly encoded mitochondrial genes and mitochondrial biogenesis. *Mol Cell Biol* 2005;25(14):6225–34.
- [135] Graves JA, Wang Y, Sims-Lucas S, Cherok E, Rothermund K, Branca MF, et al. Mitochondrial structure, function and dynamics are temporally controlled by c-Myc. *PLoS One* 2012;7(5):e37699.
- [136] Varano G, Raffel S, Sormani M, Zanardi F, Lonardi S, Zasada C, et al. The B-cell receptor controls fitness of MYC-driven lymphoma cells via GSK3 $\beta$  inhibition. *Nature* 2017;546(7657):302–6.
- [137] Donati G, Ravà M, Filipuzzi M, Nicoli P, Cassina L, Verrecchia A, et al. Targeting mitochondrial respiration and the BCL2 family in high-grade MYC-associated B-cell lymphoma. *Mol Oncol* 2022;16(5):1132–52.
- [138] Molina JR, Sun Y, Protopopova M, Gera S, Bandi M, Bristow C, et al. An inhibitor of oxidative phosphorylation exploits cancer vulnerability. *Nat Med* 2018;24(7):1036–46.
- [139] Anderson MA, Tam C, Lew TE, Juneja S, Juneja M, Westerman D, et al. Clinicopathological features and outcomes of progression of CLL on the BCL2 inhibitor venetoclax. *Blood* 2017;129(25):3362–70.
- [140] Landau DA, Sun C, Rosebrock D, Herman SEM, Fein J, Sivina M, et al. The evolutionary landscape of chronic lymphocytic leukemia treated with ibrutinib targeted therapy. *Nat Commun* 2017;8(1):2185.
- [141] Rossi D, Spina V, Forconi F, Capello D, Fangazio M, Rasi S, et al. Molecular history of Richter syndrome: origin from a cell already present at the time of chronic lymphocytic leukemia diagnosis. *Int J Cancer* 2012;130(12):3006–10.
- [142] Michallet AS, Sesques P, Rabe KG, Itti E, Tordot J, Tychyj-Pinel C, et al. An 18F-FDG-PET maximum standardized uptake value >10 represents a novel valid marker for discerning Richter's syndrome. *Leuk Lymphoma* 2016;57(6):1474–7.
- [143] Mato AR, Wierda WG, Davids MS, Cheson BD, Coutre SE, Choi M, et al. Utility of positron emission tomography-computed tomography in patients with chronic lymphocytic leukemia following B-cell receptor pathway inhibitor therapy. *Haematologica* 2019;104(11):2258–64.
- [144] Rogers KA, Huang Y, Ruppert AS, Salem G, Stephens DM, Heerema NA, et al. A single-institution retrospective cohort study of first-line R-EPOCH chemoimmunotherapy for Richter syndrome demonstrating complex chronic lymphocytic leukaemia karyotype as an adverse prognostic factor. *Br J Haematol* 2018;180(2):259–66.
- [145] Iannello A, Deaglio S, Vaisitti T. Novel approaches for the treatment of patients with Richter's syndrome. *Curr Treat Options Oncol* 2022;23(4):526–42.
- [146] Tsimberidou AM, Wierda WG, Plunkett W, Kurzrock R, O'Brien S, Wen S, et al. Phase I-II study of oxaliplatin, fludarabine, cytarabine, and rituximab combination therapy in patients with Richter's syndrome or fludarabine-refractory chronic lymphocytic leukemia. *J Clin Oncol* 2008;26(2):196–203.
- [147] Durot E, Michallet AS, Leprêtre S, Le QH, Leblond V, Delmer A. Platinum and high-dose cytarabine-based regimens are efficient in ultra high/high-risk chronic lymphocytic leukemia and Richter's syndrome: results of a French retrospective multicenter study. *Eur J Haematol* 2015;95(2):160–7.
- [148] Tsimberidou AM, O'Brien S, Kantarjian HM, Koller C, Hagemester FB, Fayad L, et al. Hodgkin transformation of chronic lymphocytic leukemia: the M. D. Anderson Cancer Center experience. *Cancer* 2006;107(6):1294–302.
- [149] Tadmor T, Shvidel L, Goldschmidt N, Ruchlemer R, Fineman R, Bairey O, et al. Hodgkin's variant of Richter transformation in chronic lymphocytic leukemia; a retrospective study from the Israeli CLL study group. *Anticancer Res* 2014;34(2):785–90.
- [150] Mouhssine S, Gaidano G. Richter syndrome: from molecular pathogenesis to druggable targets. *Cancers (Basel)* 2022;14(19).
- [151] Condoluci A, Rossi D. Biology and treatment of richter transformation. *Front Oncol* 2022;12:829983.
- [152] Lamar Z, Kennedy L, Kennedy B, Lynch M, Goad A, Hurd D, et al. Ibrutinib and rituximab induced rapid response in refractory Richter syndrome. *Clin Case Rep* 2015;3(7):615–7.
- [153] Jaglowski SM, Jones JA, Nagar V, Flynn JM, Andritsos LA, Maddocks KJ, et al. Safety and activity of BTK inhibitor ibrutinib combined with ofatumumab in chronic lymphocytic leukemia: a phase 1b/2 study. *Blood* 2015;126(7):842–50.
- [154] Appleby N, Eyre TA, Cabes M, Jackson A, Boucher R, Yates F, et al. The STELLAR trial protocol: a prospective multicentre trial for Richter's syndrome consisting of a randomised trial investigation CHOP-R with or without acalabrutinib for newly diagnosed RS and a single-arm platform study for evaluation of novel agents in relapsed disease. *BMC Cancer* 2019;19(1):471.
- [155] Mato AR, Shah NN, Jurczak W, Cheah CY, Pagel JM, Woyach JA, et al. Pirtobrutinib in relapsed or refractory B-cell malignancies (BRUIN): a phase 1/2 study. *Lancet* 2021;397(10277):892–901.
- [156] Visentin A, Imbergamo S, Scomazon E, Pravato S, Frezzato F, Bonaldi L, et al. BCR kinase inhibitors, idelalisib and ibrutinib, are active and effective in Richter syndrome. *Br J Haematol* 2018.
- [157] Bagacean C, Zdrenghea M, Saad H, Berthou C, Renaudineau Y, Tempescul A. Rapid and complete response to idelalisib in a case of Richter syndrome. *Oncol Targets Ther* 2019;12:1181–4.
- [158] Bouclet F, Calleja A, Dilhuydy MS, Véronèse L, Pereira B, Amorim S, et al. Real-world outcomes following venetoclax therapy in patients with chronic lymphocytic leukemia or Richter syndrome: a FILO study of the French compassionate use cohort. *Ann Hematol* 2021;100(4):987–93.
- [159] Davids MS, Rogers KA, Tyekuceva S, Wang Z, Pazienza S, Renner SK, et al. Venetoclax plus dose-adjusted R-EPOCH for Richter syndrome. *Blood* 2022;139(5):686–9.
- [160] Jain N, Ferrajoli A, Thompson P, et al. Venetoclax, Obinutuzumab and Atezolizumab (PD-L1 Checkpoint Inhibitor) for Treatment for Patients with Richter Transformation. *Blood* 2021;138:1550.
- [161] Crombie J, Tyekuceva S, Wang Z, et al. Updated results from a phase I/II study of duvelisib and venetoclax in patients with relapsed or refractory CLL/SLL or Richter's syndrome. *Blood* 2020;136.
- [162] Kuruvilla J, Savona M, Baz R, Mau-Sorensen PM, Gabrail N, Garzon R, et al. Selective inhibition of nuclear export with selinexor in patients with non-Hodgkin lymphoma. *Blood* 2017;129(24):3175–83.
- [163] Armand P, Murawski N, Molin D, Zain J, Eichhorst B, Gulbas Z, et al. Pembrolizumab in relapsed or refractory Richter syndrome. *Br J Haematol* 2020;190(2):e117–20.
- [164] Rogers KA, Huang Y, Dotson E, Lundberg J, Andritsos LA, Awan FT, et al. Use of PD-1 (PDCD1) inhibitors for the treatment of Richter syndrome: experience at a single academic centre. *Br J Haematol* 2019;185(2):363–6.
- [165] Jain N, Ferrajoli A, Basu S, et al. A phase II trial of nivolumab combined with ibrutinib for patients with Richter transformation. *Blood* 2018;132(Suppl. 1):296.
- [166] Younes A, Brody J, Carpio C, Lopez-Guillermo A, Ben-Yehuda D, Ferhanoglu B, et al. Safety and activity of ibrutinib in combination with nivolumab in patients with relapsed non-Hodgkin lymphoma or chronic lymphocytic leukaemia: a phase 1/2a study. *Lancet Haematol* 2019;6(2):e67–78.
- [167] Shen L, Guo J, Zhang Q, Pan H, Yuan Y, Bai Y, et al. Tislelizumab in Chinese patients with advanced solid tumors: an open-label, non-comparative, phase 1/2 study. *J Immunother Cancer* 2020;8(1).
- [168] Wang Y, Tschautscher MA, Rabe KG, Call TG, Leis JF, Kenderian SS, et al. Clinical characteristics and outcomes of Richter transformation: experience of 204 patients from a single center. *Haematologica* 2020;105(3):765–73.
- [169] Herrera AF, Ahn KW, Litovich C, Chen Y, Assal A, Bashir Q, et al. Autologous and allogeneic hematopoietic cell transplantation for diffuse large B-cell lymphoma-type Richter syndrome. *Blood Adv* 2021;5(18):3528–39.
- [170] Lahoud OB, Devlin SM, Maloy MA, Roeker LE, Dahi PB, Ponce DM, et al. Reduced-intensity conditioning hematopoietic stem cell transplantation for chronic lymphocytic leukemia and Richter's transformation. *Blood Adv* 2021;5(14):2879–89.
- [171] Kim HT, Baker PO, Parry E, Davids M, Aleya EP, Ho VT, et al. Allogeneic hematopoietic cell transplantation outcomes in patients with Richter's transformation. *Haematologica* 2021;106(12):3219–22.
- [172] Aulakh S, Reljic T, Yassine F, Ayala E, Chavez JC, Chanan-Khan A, et al. Allogeneic hematopoietic cell transplantation is an effective treatment for patients with Richter syndrome: a systematic review and meta-analysis. *Hematol Oncol Stem Cell Ther* 2021;14(1):33–40.
- [173] Neelapu SS, Locke FL, Bartlett NL, Lekakis LJ, Miklos DB, Jacobson CA, et al. Axicabtagene Ciloleucel CAR T-Cell Therapy in Refractory Large B-Cell Lymphoma. *N Engl J Med* 2017;377(26):2531–44.
- [174] Schuster SJ, Bishop MR, Tam CS, Waller EK, Borchmann P, McGuirk JP, et al. Tisagenlecleucel in adult relapsed or refractory diffuse large B-cell lymphoma. *N Engl J Med* 2019;380(1):45–56.
- [175] Abramson JS, Palomba ML, Gordon LI, Lunning MA, Wang M, Arnason J, et al. Lisocabtagene maraleucel for patients with relapsed or refractory large B-cell lymphomas (TRANSCEND NHL 001): a multicentre seamless design study. *Lancet* 2020;396(10254):839–52.
- [176] Turtle CJ, Hay KA, Hanafi LA, Li D, Cherian S, Chen X, et al. Durable molecular remissions in chronic lymphocytic leukemia treated With CD19-specific chimeric antigen receptor-modified T cells after failure of ibrutinib. *J Clin Oncol* 2017;35(26):3010–20.
- [177] Gauthier J, Hirayama AV, Purushe J, Hay KA, Lymp J, Li DH, et al. Feasibility and efficacy of CD19-targeted CAR T cells with concurrent ibrutinib for CLL after ibrutinib failure. *Blood* 2020;135(19):1650–60.
- [178] Benjamini O, Shimoni A, Besser M, Shem-Tov N, Danylesko I, Yerushalmi R, et al. Safety and efficacy of CD19-CAR T cells in Richter's transformation after targeted therapy for chronic lymphocytic leukemia. *Blood* 2020;136(Suppl. 1):40.

- [179] Ortiz-Maldonado V, Frigola G, Español-Rego M, Balagué O, Martínez-Cibrián N, Magnano L, et al. Results of ARI-0001 CART19 cells in patients with chronic lymphocytic leukemia and Richter's transformation. *Front Oncol* 2022;12: 828471.
- [180] Thompson PA, Jiang X, Banerjee P, Basar R, Garg N, Chen K, et al. A phase two study of high dose blinatumomab in Richter's syndrome. *Leukemia* 2022;36(9): 2228–32.
- [181] Guieze R, Ysebaert L, Roos-Weil D, Molina L, Fornecker LM, Aurran T, et al. Blinatumomab for patients with Richter's syndrome: a multicenter phase 2 trial from the Filo Group. *Blood* 2021;138(Suppl. 1):3570.
- [182] Hutchings M, Morschhauser F, Iacoboni G, Carlo-Stella C, Offner FC, Sureda A, et al. Glofitamab, a novel, bivalent CD20-targeting T-cell-engaging bispecific antibody, induces durable complete remissions in relapsed or refractory B-cell lymphoma: a phase I trial. *J Clin Oncol* 2021;39(18):1959–70.
- [183] Budde LE, Assouline S, Sehn LH, Schuster SJ, Yoon SS, Yoon DH, et al. Single-agent mosunetuzumab shows durable complete responses in patients with relapsed or refractory B-cell lymphomas: phase I dose-escalation study. *J Clin Oncol* 2022;40(5):481–91.
- [184] Kater AP, Ye JC, Sandoval-Sus J, Bellido M, Christensen JH, Mato AT et al. Subcutaneous epcoritamab in patients with Richter's syndrome: early results from phase 1b/2 trial (EPCORE CLL-1). *Blood* 2022;140(Suppl. 1):850–1.
- [185] Werner M, Hobeika E, Jumaa H. Role of PI3K in the generation and survival of B cells. *Immunol Rev* 2010;237(1):55–71.
- [186] Liu P, Cheng H, Roberts TM, Zhao JJ. Targeting the phosphoinositide 3-kinase pathway in cancer. *Nat Rev Drug Discov* 2009;8(8):627–44.
- [187] Cotchett KR, Dittel BN, Obeidat AZ. Comparison of the efficacy and safety of anti-CD20 B cells depleting drugs in multiple sclerosis. *Mult Scler Relat Disord* 2021; 49:102787.
- [188] Huntington S, Schuster S, He W, et al. Phase I study of first-in-class oral triplet therapy DTRM-555 in relapsed/refractory lymphoma patients through fixed-dose combination and synthetic lethality. *Blood* 2018;132(1):5384.
- [189] Awan FT, Thirman MJ, Patel-Donnelly D, Assouline S, Rao AV, Ye W, et al. Entospletinib monotherapy in patients with relapsed or refractory chronic lymphocytic leukemia previously treated with B-cell receptor inhibitors: results of a phase 2 study. *Leuk Lymphoma* 2019;60(8):1972–7.
- [190] Ravikrishnan J, Muhowski E, Lai T, et al. Characterization of LP-118, a novel small molecule inhibitor of Bcl-2 and Bcl-Xl in chronic lymphocytic leukemia resistant to venetoclax. *Blood* 2021;138: 1:679.
- [191] Barlaam B, Casella R, Cidado J, Cook C, De Savi C, Dishington A, et al. Discovery of AZD4573, a potent and selective inhibitor of CDK9 that enables short duration of target engagement for the treatment of hematological malignancies. *J Med Chem* 2020;63(24):15564–90.
- [192] Wang M, Barrientos J, Furman R, et al. Zilovertamab vedotin targeting of ROR1 as therapy for lymphoid cancers. *NEJM Evid* 2021;1(1).
- [193] Kauder SE, Kuo TC, Harrabi O, Chen A, Sangalang E, Doyle L, et al. ALX148 blocks CD47 and enhances innate and adaptive antitumor immunity with a favorable safety profile. *PLoS One* 2018;13(8):e0201832.
- [194] Sharp A, Williams A, Blagden S, et al. A first-in-human phase 1 trial of Nx-1607, a first-in-class oral CBL-B inhibitor, inpatients with advanced solid tumor malignancies. *J Clin Oncol* 40(16 suppl):TPS2691.
- [195] de Weerd I, Hofland T, Lameris R, Endstra S, Jongejan A, Moerland PD, et al. Improving CLL V $\gamma$ 9V $\delta$ 2-T-cell fitness for cellular therapy by ex vivo activation and ibrutinib. *Blood* 2018;132(21):2260–72.
- [196] Burger JA. Treatment of chronic lymphocytic leukemia. *N Engl J Med* 2020;383 (5):460–73.
- [197] Munir T, Brown JR, O'Brien S, Barrientos JC, Barr PM, Reddy NM, et al. Final analysis from RESONATE: up to six years of follow-up on ibrutinib in patients with previously treated chronic lymphocytic leukemia or small lymphocytic lymphoma. *Am J Hematol* 2019;94(12):1353–63.
- [198] O'Brien S, Jones JA, Coutre SE, Mato AR, Hillmen P, Tam C, et al. Ibrutinib for patients with relapsed or refractory chronic lymphocytic leukaemia with 17p deletion (RESONATE-17): a phase 2, open-label, multicentre study. *Lancet Oncol* 2016;17(10):1409–18.
- [199] Stilgenbauer S, Eichhorst B, Schetelig J, Coutre S, Seymour JF, Munir T, et al. Venetoclax in relapsed or refractory chronic lymphocytic leukaemia with 17p deletion: a multicentre, open-label, phase 2 study. *Lancet Oncol* 2016;17(6): 768–78.
- [200] Seymour JF, Ma S, Brander DM, Choi MY, Barrientos J, Davids MS, et al. Venetoclax plus rituximab in relapsed or refractory chronic lymphocytic leukaemia: a phase 1b study. *Lancet Oncol* 2017;18(2):230–40.
- [201] Barr PM, Owen C, Robak T, Tedeschi A, Bairey O, Burger JA, et al. Up to 8-year follow-up from RESONATE-2: first-line ibrutinib treatment for patients with chronic lymphocytic leukemia. *Blood Adv* 2022;6(11):3440–50.
- [202] Shanafelt TD, Wang XV, Hanson CA, Paietta EM, O'Brien S, Barrientos J, et al. Long-term outcomes for ibrutinib-rituximab and chemoimmunotherapy in CLL: updated results of the E1912 trial. *Blood* 2022;140(2):112–20.
- [203] Woyach JA, Ruppert AS, Heerema NA, Zhao W, Booth AM, Ding W, et al. Ibrutinib regimens versus chemoimmunotherapy in older patients with untreated CLL. *N Engl J Med* 2018;379(26):2517–28.
- [204] Moreno C, Greil R, Demirkan F, Tedeschi A, Anz B, Larratt L, et al. First-line treatment of chronic lymphocytic leukemia with ibrutinib plus obinutuzumab. *Haematologica* 2022;107(9):2108–20.
- [205] Sharman JP, Egyed M, Jurczak W, Skarbnik A, Pagel JM, Flinn IW, et al. Acalabrutinib with or without obinutuzumab versus chlorambucil and obinutuzumab for treatment-naive chronic lymphocytic leukaemia (ELEVATE TN): a randomised, controlled, phase 3 trial. *Lancet* 2020;395(10232):1278–91.
- [206] Fischer K, Al-Sawaf O, Bahlo J, Fink AM, Tandon M, Dixon M, et al. Venetoclax and obinutuzumab in patients with CLL and coexisting conditions. *N Engl J Med* 2019;380(23):2225–36.
- [207] Tam CS, Brown JR, Kahl BS, Ghia P, Giannopoulos K, Jurczak W, et al. Zanubrutinib versus bendamustine and rituximab in untreated chronic lymphocytic leukaemia and small lymphocytic lymphoma (SEQUOIA): a randomised, controlled, phase 3 trial. *Lancet Oncol* 2022;23(8):1031–43.
- [208] Tsang M, Shanafelt TD, Call TG, Ding W, Chanan-Khan A, Leis JF, et al. The efficacy of ibrutinib in the treatment of Richter syndrome. *Blood* 2015;125(10): 1676–8.
- [209] Winter AM, Landsburg DJ, Mato AR, Isaac K, Hernandez-Ilizaliturri FJ, Reddy N, et al. A multi-institutional outcomes analysis of patients with relapsed or refractory DLBCL treated with ibrutinib. *Blood* 2017;130(14):1676–9.