

Is long-term follow-up solely by imaging tests safe in non-operated pancreatic neuroendocrine tumors?

Daniela Polette¹, Juli Busquets^{1,2}, Lluís Secanella¹, María Sorribas¹, Núria Peláez¹, Catalina Uribe³, Laura Martínez-Carnicero⁴, Silvia Salord⁵, Fernando Guerrero-Pérez⁶, José Luis Vercher-Conejero⁷, Alex Teulé⁸, Joan Fabregat¹

¹Department of Hepatobiliary and Pancreatic Surgery. Bellvitge University Hospital. Research Group of Hepato-Biliary and Pancreatic Diseases. Bellvitge Biomedical Research Institute (IDIBELL). Universidad de Barcelona. L'Hospitalet de Llobregat, Barcelona. Spain. ²Department of Clinical Sciences. Faculty of Medicine and Health Sciences. Universidad de Barcelona. Barcelona, Spain. ³General and Digestive Surgery Service. Fundació Hospital Sant Joan de Déu de Martorell. Martorell, Spain. ⁴Radiology Service, Departments of ⁵Digestive Diseases and ⁶Endocrinology and Nutrition and ⁷Nuclear Medicine Service – PET Unit. Hospital Universitario de Bellvitge. IDIBELL. L'Hospitalet de Llobregat, Barcelona. Spain. ⁸Department of Medical Oncology. Catalan Institute of Oncology. IDIBELL. L'Hospitalet de Llobregat, Barcelona. Spain

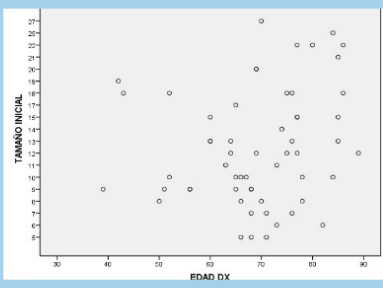
Received: 18/11/2022 · Accepted: 13/09/2023

Correspondence: Juli Busquets. Department of Hepatobiliary and Pancreatic Surgery. Hospital Universitari de Bellvitge. Research Group of Hepato-Biliary and Pancreatic Diseases. Bellvitge Biomedical Research Institute (IDIBELL). Avinguda de la Granvia de L'Hospitalet, 199. 08907 L'Hospitalet de Llobregat, Barcelona. Spain. **e-mail:** jbusquets@bellvitge-hospital.cat

Is long-term follow-up solely by imaging tests safe in non-operated pancreatic neuroendocrine tumors (PNET)?

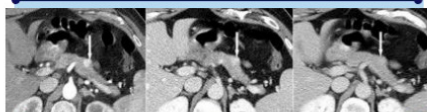
Methods

58 PNET (2008-2020), follow-up 2023
No patient developed metastasis or died from PNET progression.



Results

The mean age of the patients was 69 years (39-89).
The mean follow-up time was 82.41 months (12-164).



We observed growth in lesions larger than 2cm, without statistically significant differences.
We found no differences in the behaviour of the lesion in relation to the patient's age.

Outcomes

Conservative management of patients with small and asymptomatic NF-PNETs is reasonable in previously selected patients.

The follow-up of neuroendocrine tumors of small size can be done safely through imaging tests.

Polette D & Busquets J, et al.

Revista Española de Enfermedades Digestivas (REED)
The Spanish Journal of Gastroenterology



Lay summary

Conservative management of patients with small and asymptomatic NF-PNETs is reasonable in previously selected patients.
The follow-up of neuroendocrine tumors of small size can be done safely through imaging tests.

ABSTRACT

Introduction: the diagnosis of asymptomatic sporadic non-functioning pancreatic neuroendocrine tumors (NF-PNETs) has increased significantly due to the widespread use of high-resolution imaging tests, which is why the most appropriate management at the time of diagnosis is the subject of debate, as is how to follow-up patients.

Aims: the objective of this study was to analyze the frequency of imaging and endoscopic studies performed during long-term follow-up.

Methods: a retrospective review was performed of a database collected between January 2008 and December 2020 of patients with an incidental diagnosis of small NF-PNETs; follow-up was closed in March 2023. The imaging tests performed at the time of diagnosis and long-term follow-up were recorded. Growing less than 1 mm per year has not been considered as a worrisome feature. Follow-up was performed through imaging tests, considering endoscopic cytology for lesions with a faster grow rate.

Results: fifty-eight patients were included; the median age was 69 years. The initial mean size of the lesions studied was 12.79 mm (5-27). Follow-up was carried out only with computed tomography (CT) or magnetic resonance imaging (MRI). The initial size did not influence the behavior of the lesion in a statistically significant manner. Twenty-eight tumors (45 %) increased in size, with a growth equal to or less than 4 mm in 24 cases. The mean follow-up time was 82.41 months (12-164). No patient developed metastasis or died from PNET progression.

Conclusions: the follow-up of neuroendocrine tumors of small size can be performed safely with only imaging tests.

Keywords: Pancreatic neuroendocrine tumor. Conservative treatment. Surveillance. Small tumors.

INTRODUCTION

The diagnosis of pancreatic neuroendocrine tumors (PNETs) has increased significantly due to the widespread use of high-resolution imaging tests for the study of multiple pathologies. Recent studies of the population have shown an increasing incidence, rising from 3.2 cases per million inhabitants in 2003 to eight cases per million inhabitants in 2012 (1,2). Likewise, a high occurrence of PNET in pancreatic resection samples and in autopsy studies suggests a high prevalence of PNET in the undiagnosed general population (3). The above observations suggest an underestimation of the problem until the improvement of radiological techniques (3), especially with regard to small and asymptomatic lesions (4). Studies carried out on various

groups demonstrated that follow-up without resection is acceptable in incidental lesions smaller than 2 cm, which has been accepted by the international community (5-9). However, a dilemma arises: what is the most appropriate management for this type of patient? (10) Should we perform a pancreatic resection in these patients based on an incidental diagnosis, with the associated morbidity? (11). Finally, what tests should we perform at the time of diagnosis, and which ones should we use during follow-up? The objective of this study was to analyze the frequency of imaging and endoscopic studies performed during long-term follow-up.

MATERIALS AND METHODS

A retrospective analysis was performed with a prospective database of patients with an incidental diagnosis of non-functioning PNET, including patients diagnosed from January 2008 to December 2020 in the Hepatobiliarypancreatic Surgery Unit of our center, follow-up was closed in March 2023. Each patient was analyzed at the time of diagnosis, and the study was performed during long-term follow-up. All patients with suspected small non-functioning PNET are referred to our unit. The initial study was based on a 4-phase computed tomography (CT) and octreotide scintigraphy, incorporating the study with positron emission tomography (PET) Gallium-68-DOTATOC in 2019. Subsequently, all the cases were commented during a clinical-radiological session for discussion. In case of suspicion of hormonal functionalism or multifocality, the patient was referred to the Endocrinology Service. An endoscopic ultrasound and fine needle aspiration (EUS-FNA) study was not carried out systematically; these were only indicated in cases of a doubtful diagnosis.

PNET size < 2 cm was considered as eligible for medical follow-up using imaging tests. In patients under 60 years of age and lesions smaller than 1 cm, follow-up is considered. For lesions between 1-2 cm, EUS and subsequent follow-up are considered. In all these cases, a directed meeting is held informing the patient and joint decision-making is proposed. In our opinion, an exquisite process of information and awareness of the disease on the part of the patient is essential. In case of distrust in the proposed follow-up or cancerphobia, surgery would be considered. In the case of PNET size > 2 cm, patients were referred for surgical resection. However, in elderly or fragile patients, with lesions between of 2 and 3 cm, the treatment was determined individually (Fig. 1). In these cases, an informative meeting is also held to make the patient aware of the proposed follow-up. The presented series encompasses all patients undergoing follow-up with lesions < 3 cm. The location of the lesion has not affected the decision making.

Author contributions: J. Busquets and J. Fabregat are joint senior authors. D. Polette and J. Busquets have contributed equally to the work.

Conflict of interest: the authors declare no conflict of interest.

Acknowledgments: we thank Bellvitge University Hospital, IDIBELL and CERCA Program/Generalitat de Catalunya for institutional support.

Artificial intelligence: the authors declare that they did not use artificial intelligence (AI) or any AI-assisted technologies in the elaboration of the article.

Polette D, Busquets J, Secanella LI, Sorribas M, Peláez N, Uribe C, Martínez-Carnicero L, Salord S, Guerrero-Pérez F, Vercher-Conejero JL, Teulé A, Fabregat J. Is long-term follow-up solely by imaging tests safe in non-operated pancreatic neuroendocrine tumors? *Rev Esp Enferm Dig* 2024;116(4): 209-215

DOI: 10.17235/reed.2023.9293/2022

Follow-up was the same for all patients, with an abdominal CT scan with contrast or MRI being performed every six months for the first two years, and annually thereafter. Changes in size, characteristics of the lesion in the radiological study, and ductal dilation were recorded, as were clinical changes observed in the patient which were noted at check-ups or periodic visits to the hospital with imaging tests or clinical monitoring. The procedure in the presence of lesion growth depends on the change evidenced and the final size of the lesion. Endoscopic puncture would be considered in case of a growth of more than 1 mm per year or diagnostic doubts.

The data were entered in a Microsoft Office Access and Microsoft Office Excel database and processed using SPSS. A descriptive statistical analysis of the results was carried out. The continuous variables were compared using the Student's t-test and the Mann-Whitney test, according to the type of distribution. The series was divided according to the initial size of the diagnosed lesion (smaller than and larger than 15 mm, 20 mm) and the age of the patient (more than and less than 65, 70, and 75 years old) at the time of diagnosis. Likewise, changes in size of the lesions and the relationship with the variables recorded in the study were analyzed. A value of $p < 0.05$ was considered to be significant.

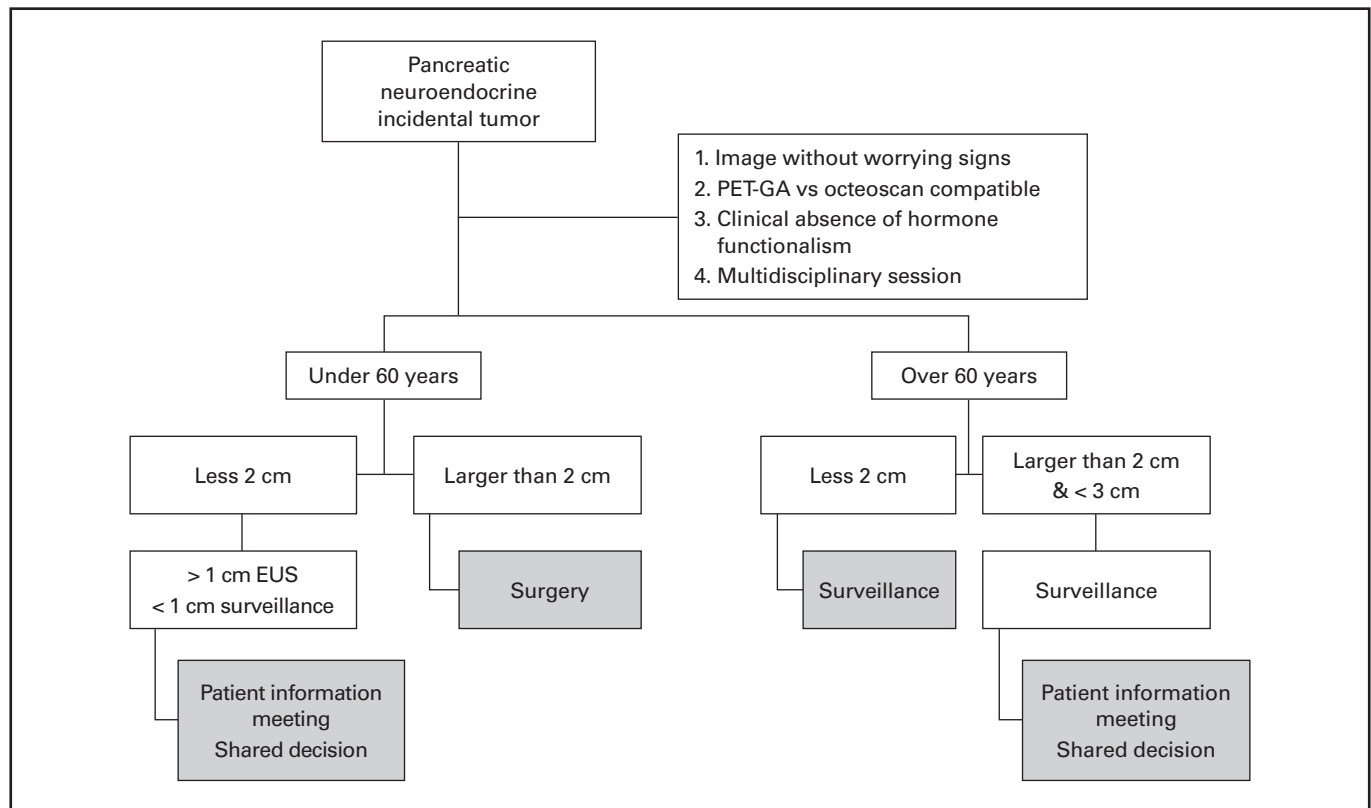


Fig. 1. Algorithm for the treatment of incidental pancreatic neuroendocrine tumors (NF-PNETs) (PET-GA: positron emission tomography Gallium-68-DOTATOC; EUS: endoscopic ultrasound).

RESULTS

Fifty-eight patients were included in the study, with NF-PNET < 3 cm, all diagnosed via CT. Fifty-seven per cent were female (Table 1). Regarding the imaging technique used for diagnosis, 100 % of the patients underwent abdominal CT, subsequently completing the study in 67.2 % of the cases with MRI. Octreotide scintigraphy was performed in 74.1 % of cases, being positive for somatostatin receptors in 53.5 % of the cases. EUS-FNA was performed in ten patients (17.24 %), being PNET-positive in nine (90 %) and inconclusive in one (10 %) of the cases. Of the ten patients in whom EUS-FNA was performed, a Ki 67 < 2 % was seen in four patients, between 2-10 % in one case, and inconclusive results were observed in five cases. Sixty-nine percent of the patients presented a PNET located in the pancreatic

body or tail, while the PNET was located in the pancreatic head or neck in 31 %. Three cases were associated with ductal dilation, none of them with biliary dilation.

Initial study

The mean size of the PNET at the time of diagnosis was 12.7 mm (5-27), with six cases (10 %) > 2 cm. The lesion was in the pancreatic body-tail in 70 % of cases. The mean age of the patients in the series was 69 (39-89) years, eight were younger than 60 years old (Table 2). No statistically significant differences were seen between PNET size and gender, despite the fact that 83 % (5/6) of the patients with PNET > 2 cm were female. The size was slightly larger in

cases > 70 years compared to the youngest cases (14 mm \pm 6.1 vs 11 mm \pm 4.2, $p = 0.058$). Furthermore, these patients had a higher percentage of large tumors (> 2 cm) than did younger patients (19 % vs 3 %, $p = 0.05$) (Fig. 2).

Table 1. Small incidental non-functioning pancreatic non-functioning neuroendocrine tumors. Bellvitge University Hospital

Patient characteristics	
Number of patients	58
Mean age in years	69 (39-89)
Sex (%)	
Female	57 %
Male	43 %
Localization (%)	
Head/uncinate	31 %
Body/tail	69 %
Duct dilatation	5 % (3/58)
Initial size (mm)	12.7 (5-27)
Increase in lesion size	45 %
Follow-up time (months)	55.95 (3-149)

Evolution of the lesion

When studying the evolution of the lesion, 45 % increased in size. The recorded growth was equal to or less than 4 mm in most cases, while in five cases it was 11 mm, 8 mm, 6 mm, and 5 mm, respectively. The final mean size was 14.07 mm (5-32). The initial size did not influence the behavior of the lesion in a statistically significant manner; however, there was 43 % growth of the tumors < 2 cm and 67 % of those > 2 cm. The age of the patient did not influence tumor growth. Thus, we can conclude that the growth of the lesions was similar between the groups of patients younger and older than 70 years (47 % [15/32] vs 42 % [11/26]), respectively (Fig. 3).

Long-term follow-up

The long-term study was performed with CT or MRI, performing between three and 12 examinations per patient. The mean follow-up time was 82.41 months (12-164). At the end of follow-up, eleven patients had died, eight due to a medical cause and three due to various neoplasms. The causes of death were respiratory failure (five), heart failure (one), liver cirrhosis decompensation (one) and severe acute cholecystitis (one). Of the three patients who died from neoplasm progression, one died from progression of lung cancer and one from urinary bladder cancer. One 84-year-old patient who was being followed up for a pancreatic head PNET (25 mm) developed pancreatic tail adenocarcinoma with stability of the pancreatic head lesion.

The study of the initial size showed that 37 % of the patients with lesions > 2 cm died during follow-up, compared to 10 % of the patients with lesions < 2 cm ($p = 0.039$),

Table 2.

Sex	Age at diagnosis	Year of previous illness with radiological studies	Year of diagnosis	Initial size (mm)	Follow up	Final size (mm)	Number of total studies (CT + NMR)	Octreoscan	PET-GA	EUS/FNA
Male	52	-	2020	10	04/11/2022	11	2 + 3	Not performed	Positive	Not performed
Female	50	-	2018	8	27/01/2023	11	4 + 0	Negative	Positive	Not performed
Female	51	2018 Colon cancer	2018	7	13/01/2023	7	8 + 4	Positive	Not performed	Not performed
Male	43	Tuberous sclerosis	2014	18	31/03/2022	12	4 + 4	Positive	Not performed	Not performed
Male	56	2009 Colon cancer	2012	9	18/10/2022	9	9 + 1	Negative	Pending	Not performed
Male	39	2013 Crohn's disease	2013	9	22/12/2022	13	3 + 5	Inconclusive	Positive	Performed Low grade neuroendocrine tumor
Female	42	2011 Colon cancer	2011	18	01/02/2023	12	11 + 2	Not performed	Negative	Not performed
Male	56	2011 Colon cancer	2011	9	28/10/2021	11	10 + 1	Negative	Not performed	Not performed

CT: computed tomography; NMR: nuclear magnetic resonance; PET-GA: positron emission tomography Gallium-68-DOTATOC; EUS: endoscopic ultrasound; FNA: fine needle aspiration.

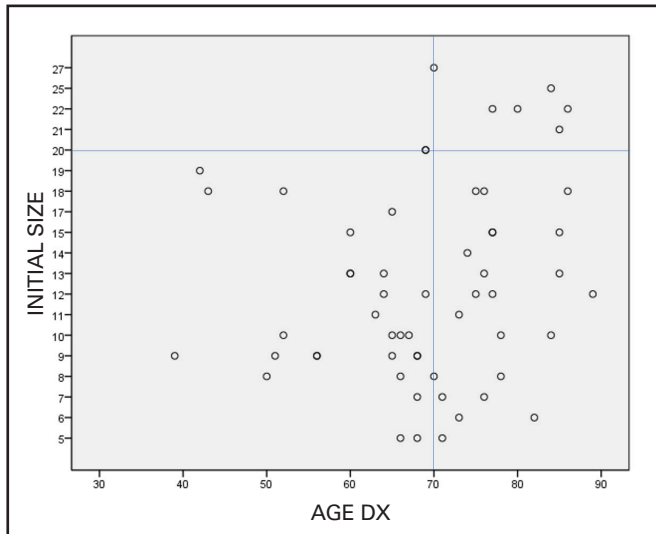


Fig. 2. Size of the pancreatic lesion (mm) at the time of diagnosis depending on the age of the patient (age dx). The size was slightly higher in those > 70 years compared to the youngest cases ($14 \text{ mm} \pm 6.1$ vs $11 \text{ mm} \pm 4.2$, $p = 0.058$). Furthermore, these patients had a higher percentage of large tumors (> 2 cm) than the younger patients (19 % vs 3 %, $p = 0.05$).

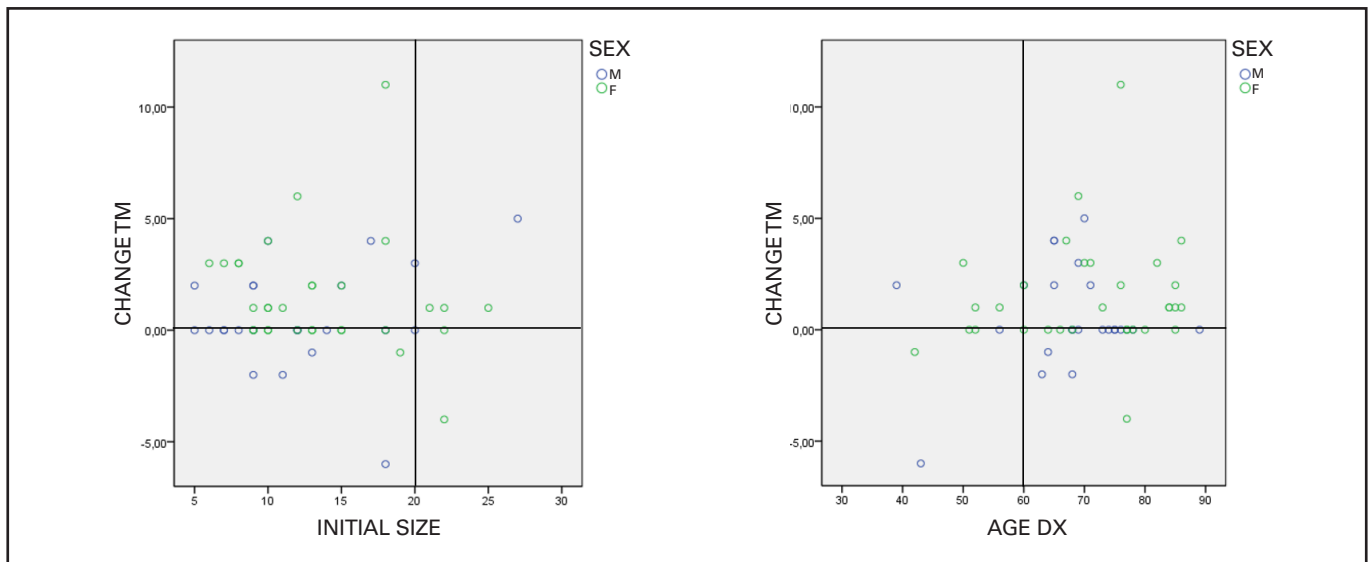


Fig. 3. Change in size of the pancreatic neuroendocrine tumor according to the patient's age and the initial size of the lesion (mm). Tumors that presented tumor growth are expressed with change in size (TM) greater than 0, those with no growth presented growth equal to 0, and those with decrease are expressed with change in TM less than 0. Growth was observed in lesions larger than 2 cm at the time of diagnosis, without statistically significant differences. There were no differences in the behavior of the lesion in relation to the patient's age. M: male; F: female.

probably in relation to the advanced age in the group of patients with PNET > 2 cm. The causes of death were not related to the lesion size. No patient developed metastasis during follow-up. The growth rate was very low in all cases with registered growth. Only two cases grew more than 1 mm per year, which we will discuss below among the large lesions. Four patients presented growth of more than 4 mm during follow-up. One patient was diagnosed at 70 years of age with a 27 mm PNET, presented growth of 5 mm in nine years, and died due to medical causes already mentioned and associated dementia, without a cytology puncture. A 69-year-old patient with a 20 mm lesion presented worrisome growth (6 mm/4 years) and underwent surgery (pancreatoduodenectomy). Histology showed a PNET (well differentiated pT2N0). A 69-year-old female patient with a 20 mm lesion presented sustained growth

(8 mm/4 years) without other radiological changes. This case is currently pending the information meeting and the shared decision, endoscopic puncture or surgery will be advised if in doubt. A 76-year-old patient with an 18 mm lesion presented 11 mm growth in 13 years. The patient remains asymptomatic and has not undergone puncture during follow-up; she is currently 89 years old.

DISCUSSION

After the initial experiences, published between 2011 and 2016, by the MSKCC American groups from New York and the Mayo Clinic and the European groups of Paris and Verona (5,6,12,13), it became accepted as valid practice to follow-up patients with small incidental NF-PNET. Years later,

various sets of clinical guidelines included the possibility of follow-up as an acceptable strategy in this type of lesion (7,8,14,15). Resected PNETs < 2 cm are rarely associated with lymph node metastasis or G3 neuroendocrine carcinoma (13,16), and it has been determined that aggressive tumor behavior and lymph node metastasis are present in only 5 % of small PNETs (4,17). Therefore, the risk of dissemination was shown to be related to tumor size (16,18). In the present study, a total of 58 patients were followed up for more than four years, and none of them had distant disease progression. None of the included cases died due to progression of the disease. Therefore, it seems safe to follow up patients with a small incidental PNET, although the size threshold for indicating resection remains controversial (13,18).

We have shown that large tumors (larger than 2 cm) corresponded to older patients with higher mortality during long-term follow-up, even though the causes of death were not related to the pancreatic lesion. These findings seem to be consistent with the philosophy discussed in our algorithm. Thus, being more aggressive among the younger population, it seems logical to have large lesions among the older population. Our series seems to have a clear aggregation among the older population, as shown by a mean age close to 70 years.

Follow-up of PNET

There is controversy regarding which tests to carry out during follow-up in these patients. In our center, due to the growth of the lesion, the interval between imaging tests is reduced until the measurement stabilizes, without any case of hepatic or extrapancreatic progression arising to date (19). EUS-FNA was not indicated in any cases. Partelli (20) et al. reviewed their experience with 101 PNET < 2 cm. Four patients underwent surgery for a PNET-G2 compatible cytology; however, it was only confirmed in one of these cases. The authors maintain that its use should be restricted so as not to indicate unnecessary surgery, which is consistent with our way of thinking. Recently, Barenboim (21) et al. published a series of PNET < 2 cm with EUS-FNA in all those cases undergoing follow-up, and in 89 % of those that underwent surgery. The two patients who presented growth during follow-up were referred to surgery, confirming that they had a low potential for malignancy, without presenting distant disease. This group, in contrast to ours, proposed EUS-FNA for all patients, and referring younger patients to surgery. The PANDORA study protocol (22) included a strict follow-up every three months alternating among clinical follow-up, imaging tests, and EUS. However, the authors concluded that the use of EUS was excessive, and that it should be indicated only in carefully selected cases. As we noted previously, in our series we did not perform EUS-FNA in a systematic way. We carried out follow-up with only CT or MRI in a systematic way, reserving EUS for doubtful cases, all of them performed at diagnosis. In half of the cases, an increase in the size of the lesion was observed, being more frequent in large lesions, which was not statistically significant, and independent of the patient's age. According to our management, the patient with a growth less than 1 mm per year could be followed by imaging tests. Evidence of growth greater than 1 mm per year must be considered on an individual basis.

Limitations

Our study has limitations, such as the fact that it is a retrospective study in a single center and with a small sample size. Another limitation is the scarce performance of PET-Ga in our series, which is now being carried out in all patients as from 2020.

CONCLUSIONS

With the data we have so far, we can conclude that the conservative management of patients with small and asymptomatic NF-PNETs is reasonable in previously selected patients. In addition, follow-up of this type of lesion, with imaging tests only and in experienced centers, is an option to be considered in subsequent studies.

FUNDING

This research did not receive any specific grants from any funding agency in the public, commercial, or not-for-profit sectors. This study was funded by the investigator's personal funds. The costs of the surgical procedures and complementary tests were paid by the Catalan Institute of Health, and no additional costs were incurred. The investigators did not receive any economic compensation to conduct the study. Therefore, the study design, data collection, analysis, interpretation, and the original draft's writing, review, and editing were performed by members of the study team. The corresponding author had full access to all the study data and was responsible for submitting the paper for publication.

REFERENCES

1. Yao JC, Hassan M, Phan A, et al. One hundred years after "carcinoid": epidemiology of and prognostic factors for neuroendocrine tumors in 35,825 cases in the United States. *J Clin Oncol* 2008;26(18):3063-72. DOI: 10.1200/JCO.2007.15.4377
2. Dasari A, Shen C, Halperin D, et al. Trends in the incidence, prevalence, and survival outcomes in patients with neuroendocrine tumors in the United States. *JAMA Oncol* 2017;3(10):1335-42. DOI: 10.1001/jamaoncol.2017.0589
3. Partelli S, Giannone F, Schiavo Lena M, et al. Is the real prevalence of pancreatic neuroendocrine tumors underestimated? A retrospective study on a large series of pancreatic specimens. *Neuroendocrinology* 2019;109(2):165-70. DOI: 10.1159/000499606
4. Kuo EJ, Salem RR. Population-level analysis of pancreatic neuroendocrine tumors 2 cm or less in size. *Ann Surg Oncol* 2013;20(9):2815-21. DOI: 10.1245/s10434-013-3005-7
5. Bettini R, Partelli S, Boninsegna L, et al. Tumor size correlates with malignancy in nonfunctioning pancreatic endocrine tumor. *Surgery* 2011;150(1):75-82. DOI: 10.1016/j.surg.2011.02.022
6. Lee LC, Grant CS, Salomao DR, et al. Small, nonfunctioning, asymptomatic pancreatic neuroendocrine tumors (PNETs): role for nonoperative management. *Surg (United States)* 2012;152(6):965-74. DOI: 10.1016/j.surg.2012.08.038
7. Howe JR, Merchant NB, Conrad C, et al. The North American Neuroendocrine Tumor Society consensus paper on the surgical management of pancreatic neuroendocrine tumors. *Pancreas* 2020;49(1):1-33. DOI: 10.1097/MPA.0000000000001454

8. Falconi M, Eriksson B, Kaltsas G, et al. ENETS consensus guidelines update for the management of patients with functional pancreatic neuroendocrine tumors and non-functional pancreatic neuroendocrine tumors. *Neuroendocrinology* 2016;103(2):153-71. DOI: 10.1159/000443171
9. Uribe Galeano C, Fabregat Prous J, Busquets Barenys J, et al. Tumores neuroendocrinos no funcionantes de páncreas incidentales de pequeño tamaño: resultados de una serie con manejo no quirúrgico. *Cir Esp* 2017;95(2):83-8. DOI: 10.1016/j.ciresp.2016.12.006
10. Panzuto F, Massironi S, Partelli S, et al. Gastro-entero-pancreatic neuroendocrine neoplasia: the rules for non-operative management. *Surg Oncol* 2020;35:141-8. DOI: 10.1016/j.suronc.2020.08.015
11. Heidsma CM, Tsilimigras DI, Van Dieren S, et al. Indications and outcomes of enucleation versus formal pancreatectomy for pancreatic neuroendocrine tumors. *HPB* 2021;23(3):413-21. DOI: 10.1016/j.hpb.2020.06.015
12. Sadot E, Reidy-Lagunes DL, Tang LH, et al. Observation versus resection for small asymptomatic pancreatic neuroendocrine tumors: a matched case-control study. *Ann Surg Oncol* 2016;23(4):1361-70. DOI: 10.1245/s10434-015-4986-1
13. Gaujoux S, Partelli S, Maire F, et al. Observational study of natural history of small sporadic nonfunctioning pancreatic neuroendocrine tumors. *J Clin Endocrinol Metab* 2013;98(12):4784-9. DOI: 10.1210/jc.2013-2604
14. Singh S, Dey C, Kennecke H, et al. Consensus recommendations for the diagnosis and management of pancreatic neuroendocrine tumors: guidelines from a Canadian national expert group. *Ann Surg Oncol* 2015;22(8):2685-99. DOI: 10.1245/s10434-014-4145-0
15. Maker AV, Tran TB, Coburn N, et al. Does attending a Delphi consensus conference impact surgeon attitudes? Survey results from the Americas HepatoPancreatoBiliary Association consensus conference on small asymptomatic pancreatic neuroendocrine tumors. *HPB* 2019;21(5):524-30. DOI: 10.1016/j.hpb.2018.10.001
16. Partelli S, Gaujoux S, Boninsegna L, et al. Pattern and clinical predictors of lymph node involvement in nonfunctioning pancreatic neuroendocrine tumors (NF-PanNETs). *JAMA Surg* 2013;148(10):932-9. DOI: 10.1001/jamasurg.2013.3376
17. Cherenfant J, Stocker SJ, Gage MK, et al. Predicting aggressive behavior in nonfunctioning pancreatic neuroendocrine tumors. *Surg (United States)* 2013;154(4):785-93. DOI: 10.1016/j.surg.2013.07.004
18. Cienfuegos JA, Hurtado-Pardo L, Rotellar F. Small pancreatic neuroendocrine tumors: observing and monitoring or prompt surgical resection. *Rev Esp Enferm Dig* 2022;114(1):1-4. DOI: 10.17235/reed.2021.8419/2021
19. Ramachandran A, Madhusudhan KS. Advances in the imaging of gastroenteropancreatic neuroendocrine neoplasms. *World J Gastroenterol* 2022;28(26):3008-26. DOI: 10.3748/wjg.v28.i26.3008
20. Partelli S, Mazza M, Andreasi V, et al. Management of small asymptomatic nonfunctioning pancreatic neuroendocrine tumors: limitations to apply guidelines into real life. *Surg (United States)* 2019;166(2):157-63. DOI: 10.1016/j.surg.2019.04.003
21. Barenboim A, Lahat G, Nachmany I, et al. Resection versus observation of small asymptomatic nonfunctioning pancreatic neuroendocrine tumors. *J Gastrointest Surg* 2020;24(2):449-50. DOI: 10.1007/s11605-019-04455-y
22. Heidsma CM, Engelsman AF, Van Dieren S, et al. Watchful waiting for small non-functional pancreatic neuroendocrine tumours: nationwide prospective cohort. *Br J Surg* 2021;00(0):1-4. DOI: 10.1093/bjs/znab088