

# Ultrasound-guided interventions in rheumatology

Emili Gómez-Casanovas<sup>1</sup> , Victor Mayoral Rojals<sup>2</sup> , Andres Ponce Fernandez<sup>1</sup> ,  
Manuel Pujol Busquets<sup>3</sup> , Meritxell Sallés Lizarzaburu<sup>4</sup> 

## Abstract

Over the last few years, percutaneous procedures have undergone great advances, thanks to the ultrasound (US) guidance, due to the technical improvements in the US field, combined with the greater availability, good portability, and reduced cost of US devices. The direct target visualization and the real-time imaging performance enabled by US-guidance account for an improved accuracy in needle placement in several rheumatology interventions. So, ultrasound-guided procedures contribute to several diagnostic or therapeutic procedures such as fluid aspiration or treatment instillations of common joints, tendons, and bursas. In clinical practice, this fact is especially important in the case of depth areas like the hip, small anatomical structures as tendon sheaths or nerves in tenosynovitis or nervous blocks, or complex anatomical structures like the spine's facet joints. The US-guide is an essential tool for performing diagnostic procedures as synovial biopsy. US can also be combined with other imaging techniques, like the establishment portal arthroscopy for instance. Compared to older blind procedures, US-guided injections are more accurate and safer, and they result in better clinical outcomes in terms of joints improvement in function and decreased risk of damages caused by needle misplacement. With the ultrasound guided treatment, we can avoid the instillation of therapeutic products outside the predetermined target, which may be sometimes potentially harmful. The aim of this article is to describe the main generalities of ultrasound-guided procedures in rheumatology, their main advantages and disadvantages, and their particularities in joints where they are most frequently used, such as the shoulder, hip, and knee.

**Keywords:** Ultrasound guided, interventions, rheumatology

### ORCID iDs of the authors:

C.E.G. 0000-0001-7504-8429;  
R.V.M. 0000-0001-7504-8429;  
F.A.P. 0000-0003-3068-5752;  
B.M.P. 0000-0003-0676-3191;  
L.M.S. 0000-0002-3721-645X.

**Cite this article as:** Gómez-Casanovas E, Rojals VM, Fernandez AP, Busquets MP, Lizarzaburu MS. Ultrasound-guided interventions in rheumatology. *Eur J Rheumatol.* 2024;11(suppl 3):S323-S333.

## Introduction

Interventional rheumatology is the specialty field dedicated to the execution of minimally invasive procedures for diagnostic or therapeutic purposes.

The origins of interventionism in rheumatology go back to the well-known publications by Hollander<sup>1</sup> in 1951 about corticosteroid infiltrations made using anatomical coordinates.

A very important turning point was the access for rheumatologists to ultrasound (US) in the 1990s, thanks to the high-frequency linear probes development, which have allowed us to see surface anatomical structures with greater resolution. The contributions of Bianchi S., and Martinolli C<sup>2</sup> and working groups such as OMERACT<sup>3</sup> among others, with their extensive musculoskeletal US knowledge led to a qualitative leap, both in diagnostic US and in US-guided procedures of the musculoskeletal system (US-GP).

The advantages of the US use in US-GP, in comparison with anatomic coordinates, are thoroughly described in medical literature.<sup>4-7</sup>

The US is a bloodless technique, without radiation or harmful effects, economical, feasible, reproducible, dynamic, fast, and comfortable, which is performed in real time and does not require contrasts. It can also be complemented using the Doppler mode in interventional procedures to avoid neurovascular injury or drug extravasation at the bloodstream level. The portability of the US equipment and the current low cost have improved the accessibility to this technique.<sup>8</sup>

Echo-guided interventionism allows precise access to the predetermined objective for instilling drugs, isotopes, platelet-rich plasma, fluid aspiration, calcification lavage, biopsy taking, applying neuroablation techniques, and percutaneous surgical procedures.

1 Department of Rheumatology, Hospital Clinic, Barcelona, Spain

2 Clinic of Pain, Anesthesiology Department, Hospital Universitari de Bellvitge, Hospitalet de Llobregat, Barcelona, Spain

3 Department of Rheumatology, Hospital Universitari Mútua Terrassa, Barcelona, Spain

4 Department of Rheumatology, Althaia Xarxa Assistencial Universitària de Manresa, Barcelona, Spain

Corresponding author:  
Emili Gómez-Casanovas  
E-mail: 16900egc@comb.cat

Submitted: November 22, 2020

Accepted: June 14, 2021

Available Online Date: March 9, 2022

Copyright©Author(s) - Available online at  
www.eurjrheumatol.org.

Content of this journal is licensed under a Creative Commons Attribution-NonCommercial 4.0 International License.



Table 1. US Performance Advantages

| Advantages  |
|---|
| Bloodless technique   |
| No radiation or harmful effects   |
| Feasible, reproducible, fast, and comfortable   |
| Dynamic and multiplanar exploration   |
| It does not require contrast  |
| Real-time performance   |
| Economical  |
| Portable  |
| Diagnosis confirmation before the procedure   |
| Objective selection based on the most affected structure, and therefore greater precision, safety, and effectiveness                                  |
| Lesion depth measurement that allows choosing the length of the needle  |
| Real-time visualization of the needle path with a safe reach of the therapeutic objective, being able to aspirate and/or inject in the same procedure |
| Visualization of neurovascular structures to avoid iatrogenesis and pain  |

We can precisely select the specific puncture area in an anatomical region to reach the location of the greatest synovial effusion and avoid septa or osteophytes, and thus infiltrate the most injured area, avoiding the instillation of therapeutic products outside the predetermined target, which may be sometimes potentially harmful.

Preprocedure US allows confirming the diagnosis, planning the best approach, being more direct and less painful as well as avoiding injury to vascular or nerve structures. It

Main Points

- A very important turning point was the access for rheumatologists to ultrasound (US) in the 1990s, thanks to the high-frequency linear probes development, which have allowed us to see surface anatomical structures with greater resolution.
- Echo-guided interventionism allows precise access to the predetermined objective for instilling drugs, isotopes, platelet-rich plasma, fluid aspiration, calcification lavage, biopsy taking, applying neuroablation techniques, and percutaneous surgical procedures.
- Ultrasounds allow us to bring percutaneous procedures in rheumatology closer to excellence in our clinical practice.

Table 2. US Performance Disadvantages

| Disadvantages                                   |
|---|
| Not visible under cortical bone                 |
| Vision difficulty in deep structures or obesity |
| Limitation due to acoustic window               |
| Learning curve                                  |

also allows confirming the depth and characteristics of the lesion and choosing the length of the needle, the thickness of the lumen, and the type of bevel.

US-guided infiltrations have low iatrogenesis, are less painful and time consuming, and are similar to a blind puncture (Table 1).

There are nonetheless some drawbacks, such as the limitation of the bone cortex that does not allow the transmission of US, which limits the acoustic window, causing anatomical areas to be blind to US and limiting the continuous vision of the needle.

Furthermore, in the case of obesity or very deep lesions, the image resolution is lower, and we are forced to use low-frequency convex probes and even opt for other imaging techniques (Table 2).

The decision to perform an US-guided procedure requires a clearly documented clinical diagnosis.

We have to consider that the learning curve for US-guided procedures is not short and can become a limitation. This, however, is currently changing, thanks to media and interactive teaching tools that are being constantly developed. In any case, it is much better being able to see what we are doing than to blindly treat with anatomical coordinates. Furthermore, many experts in performing blind intra-articular infiltrations have been found to consider the advantages of using real-time US monitoring and now perform US-guided infiltrations.<sup>9</sup>

Finally, it is not the objective of this article to address all the possible US-guided procedures in rheumatology. There are several excellent publications that we encourage the reader to consult, and that we mention in the reference section. However, it seemed interesting to us to make known as a sample how the authors approach several pathologies that may affect joint, ligament, tendon, bursa, and peripheral nerve blockade of the upper and lower limbs, specifically shoulder, hip, and knee. We have left the axial structures and others aside, since they deserve a specific approach.

The Shoulder

Shoulder pain has a high prevalence in medical practices. The shoulder is a complex joint, which involves many structures, and for which, US-guided interventional procedures may be very helpful. We review several structures that may be involved; our focus is on the technique of US-guided puncture, not on the technique used to evaluate the structure.

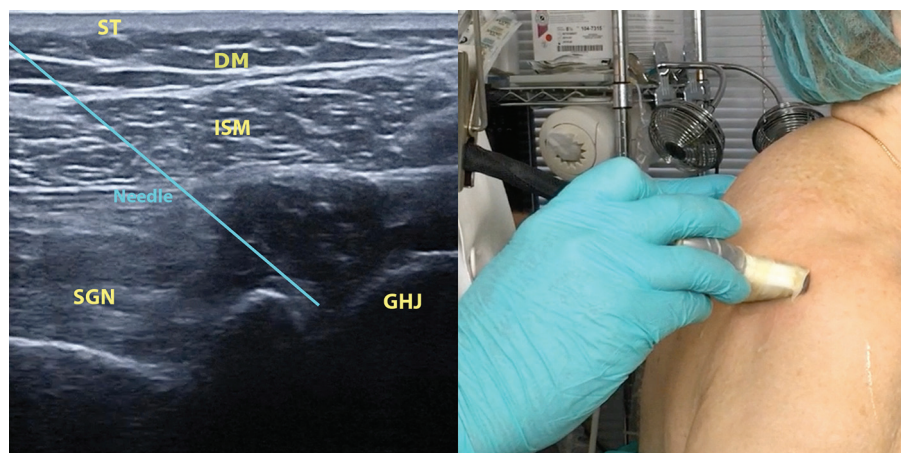
Joints such as the glenohumeral (GH), acromioclavicular (AC), or sternoclavicular (SC) may be involved, and a US-guided puncture may be needed.

GH joint

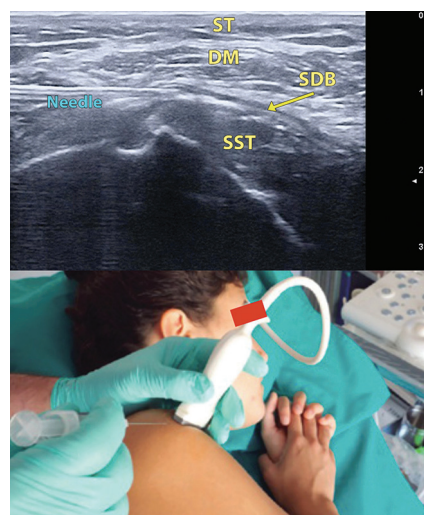
The GH joint has several associated joint recesses: the long head of the biceps brachii tendon sheath (LHBBT), the axillary recess, the subscapular recess, and the posterior recess. Intra-articular joint injections can be performed with either an anterior or a posterior approach, with the posterior approach generally being more feasible. The patient must position the ipsilateral arm facing upward with the hand touching the contralateral shoulder. We use a low-frequency (<10 MHz) curvilinear-array transducer placed parallel and directly caudal to the scapular spine. Common US findings include cortical irregularities, joint effusions, labral tears, and osteophytes. For the posterior plane injection, a 21-25-gauge 40-60 mm needle is used, taking care not to puncture the cartilage and glenoid labrum during the procedure to avoid causing pain. When the position is confirmed, the desired amount of the drug is injected (usually 2-4 mL). According to the pathology, the drug administered may be an anti-inflammatory agent (such as steroids) or a viscosupplement such as hyaluronic acid.<sup>10-12</sup> In the case of adhesive capsulitis, higher volumes of injectate are necessary.<sup>13</sup> US guidance is highly recommended, since blind injection is associated with high failure rate<sup>14</sup> (Figure 1).

AC joint

The AC joint is very superficial and is best visualized using a high-frequency (>10 MHz) linear-array transducer. The patient is seated opposite the examiner in a neutral position, with the hand lying on the thigh. The probe is centered over the joint in the coronal plane. Common US findings are widening and cortical irregularities, joint effusion with synovitis, or capsular distension as well as ganglion cysts. We can perform a US-guided injection using a 25-gauge needle with the desired amount of the drug (usually <1 mL). The needle should be inserted no more than 1 cm deep; if it is inserted too far, the drug injected will be deposited within the



**Figure 1.** US-guided procedure in shoulder joint. ST, subcutaneous tissue; DM, deltoid muscle; ISM, infraspinatus muscle; SGN, spinoglenoid notch; GHJ, glenohumeral joint.



**Figure 2.** US-guided procedure in subacromial-subdeltoid bursa. ST, subcutaneous tissue; DM, deltoid muscle; SDB, subacromial deltoid bursa; SST, supraspinatus tendon.

subacromial bursa or supraspinatus tendon. Care must be taken to avoid excess distension of the joint, which may produce pain.<sup>10-12</sup> US-guided injection of AC joint has shown to improve accuracy vs conventional group.<sup>15</sup>

### SC joint

The SC joint is also a superficial structure best visualized using a high-frequency (>10 MHz) linear-array transducer placed long axis to the clavicle. US findings include cortical irregularities, capsular distension, and hyperemia on low-flow color Doppler in synovitis. The patient is placed in the supine position; once the SC joint is localized, a 25-gauge needle is introduced, and <1 mL of the medication is injected. Care must be taken to avoid excess distension of the joint.<sup>11</sup> US-guided injection of the SC joint has better accuracy than conventional injections.<sup>16</sup> Both in the AC and SC

joints, the use of an in-plane and out-of-plane approach techniques combined may be useful to place the needle tip inside the selected target.

### SASD bursa

Structures other than the joints may also be affected, such as the subacromial-subdeltoid (SASD) bursa and tendons like the LHBBT and rotator cuff tendons.

The SASD bursa is a synovial space that covers the rotator cuff, located in the subacromial region between the inferior surface of the acromion and the supraspinatus. The normal bursa is about 1 mm thick; it is usually collapsed and is rarely visible.

The patient may be seated, and the arm must be supinated and extended, as if the hand were in the back pocket. SASD bursa has a superficial location and is best visualized using a high-frequency (>10 MHz) linear-array transducer placed long axis to the supraspinatus tendon fibers.<sup>10-12</sup>

SASD bursopathy is the most commonly reported finding with diagnostic US for painful shoulder, a condition that may be due to primary or secondary causes.<sup>17</sup> In acute inflammation, we find a bursal enlargement with anechoic fluid and hyperechoic bursal walls; in chronic inflammation, we see thickened and hypoechoic bursal walls with or without effusion in between,<sup>12</sup> and sometimes accompanied by hyperemia on color Doppler.<sup>11</sup> Once localized, a 21-gauge 40-51 mm needle is introduced laterally with respect to the probe. Intra-bursal injections for therapeutic purposes are usually performed with corticosteroids to reduce local inflammation and pain.<sup>18</sup> The needle should not drill the SASD bursa because the steroid might damage the supra-

spinatus tendon.<sup>12</sup> In a randomized controlled trial, the US-guided group showed significantly greater improvement than the conventional group. Only 30% of blinded injections were found to be accurately placed within the subacromial bursa<sup>19</sup> (Figure 2).

### LHBBT

The LHBBT lies in the bicipital groove and is surrounded by a tendon sheath, which communicates directly with the GH joint.

The patient must be in the supine position with the arm in external rotation. We use a high-frequency (>10 MHz) linear-array transducer placed over the bicipital groove and evaluate in long and short axis. US findings are tendinopathy with tenosynovitis, dynamic biceps tendon subluxation, or dislocation and degenerative longitudinal split tearing. Tenosynovitis may be found alone, but it is usually associated with rotator cuff pathology or GH pathology. The presence of a small amount of fluid within the LHBBT sheath is a common finding and is often asymptomatic; conversely, effusion along the LHBBT is usually symptomatic.<sup>20</sup> The best view for making the puncture is the short axis (transversal view), and the synovial tendon sheath is the target for injection. A 21-25-gauge 51 mm needle is inserted laterally to medially and 1-2 mL of the drug is injected, taking care to avoid tendon penetration. Color Doppler can be used to identify the ascending branch of the anterior circumflex artery, so as to avoid puncturing it.<sup>10-12</sup> US-guided injection of LHBBT has better accuracy than conventional injections.<sup>21</sup>

### Rotator cuff

Rotator cuff tendinopathy is a common condition. One form of presentation is degenerative rotator cuff tendinopathy. US appearance is a loss of the typical tendinous fibrillar echotexture and a thickening of the tendon; we may also find a calcific enthesopathy, mostly asymptomatic.<sup>12</sup> If we need to treat it by way of autologous platelet-rich plasma, we make an intralesional injection under US guidance,<sup>22</sup> but to treat it with steroids, we make a SASD bursa injection, avoiding damage to the tendon.

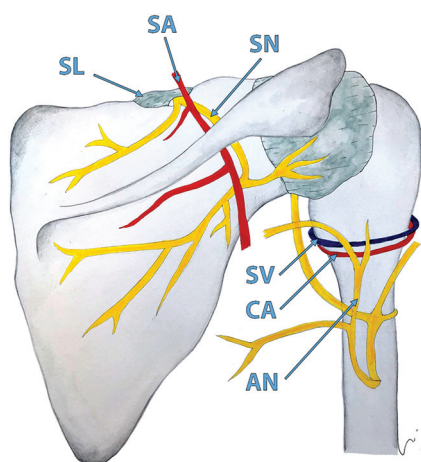
Another form is calcific rotator cuff tendinopathy, characterized by the deposition of hydroxyapatite crystals, a common condition that occurs in up to 20% of all painful shoulders. The supraspinatus muscle is the most commonly affected (in 80% of cases), followed by infraspinatus and subscapularis.<sup>23</sup> According to the US appearance, calcific depositions can be classified as hard (hyperechoic and well-circumscribed with posterior acoustic shadowing), soft (homogeneous hyperechoic



with incomplete shadowing), or fluid (hyperechoic peripheral rim with hypoechoic/anechoic center).<sup>24</sup> When conservative treatment fails, minimally invasive treatments can be used: barbotage (extracting the calcific material using US-guided percutaneous irrigation of calcific tendinopathy (US-PICT)), which is less invasive and presents fewer complications than arthroscopy; fenestration (creating new openings in the calcium deposit by repeated needling procedure to stimulate natural absorption); and steroid injection into the SASD bursa.<sup>10,12,25</sup> Percutaneous treatment is not indicated if the calcification is asymptomatic, is very small (<5 mm), has migrated into the bursal space, or is eroding the humeral cortical bone.<sup>12</sup> Several different techniques of US-PICT have been reported in the literature, using one or two needles to remove calcium. The patient is placed in the supine position, and we perform a sterile preparation of the skin and an US probe. The target calcification is visualized along its major axis, and anesthetic is injected in the SASD bursa and around the calcification. The two-needle technique requires two 16-gauge needles that are inserted into the calcification with continuous US monitoring; a 20 mL syringe filled with saline solution is connected to one of the needles, and we start to push the plunger repeatedly. When the saline is injected into the calcification, the material starts to dissolve and is extracted through the other needle. The process is repeated until the calcium deposit is reduced.<sup>23</sup> The procedure is concluded with steroid injection into the SASD bursa.<sup>13</sup> The single needle technique is very similar: the calcification is punctured, with constant US monitoring using a 21-gauge needle. Once positioned in the center of the calcification, the tip of the needle is gently rotated followed by washing by pushing the syringe plunger to hydrate the deposit; the calcium refluxes back together with saline solution or anesthetic within the same syringe. When the calcification is very hard and no material can be extracted, the calcified deposit can be fragmented by using gentle rotation of the needle tip with the possibility of accelerating the process of spontaneous resorption (fenestration technique). At the end of the process, 20 mg of triamcinolone is injected into the SASD bursa.<sup>26</sup>

#### Suprascapular and axillary nerves blockade

The GH joint is mainly innervated by the suprascapular nerve (SSN), axillary nerve (AN), and the superior subscapular nerve. Other nerves, which contribute to a lesser extent, are the lateral pectoral nerve and branches of the posterior cord of the brachial plexus. The posterosuperior quadrant of the GH joint is innervated by the lateral branches of the SSN



**Figure 3.** Anatomical representation of the partial shoulder innervation. SN, suprascapular nerve; SA, suprascapular artery; AN, axillary nerve; CA, circumflex artery; CV, circumflex vein; SL, suprascapular ligament. The original artwork was created by Tanit Gómez and published with her permission.

that emerge midway between the SSN and the spinoglenoid fossas (branches emerging laterally in an area distal to the spinoglenoid fossa have also been described). The posteroinferior quadrant is innervated by the posterior division of the AN that runs alongside the circumflex artery after passing through the inferior border of the teres minor muscle next to the humeral neck. The anterosuperior quadrant is innervated by the superior subscapular nerve. The anteroinferior quadrant is innervated by the main trunk of the AN, which bears articular branches before its division in the quadrangular space and can be located at the junction of the lower border of the subscapularis muscle and the humeral neck with the help of easy visualization of the anterior circumflex artery<sup>27</sup> (Figure 3).

In clinical practice, the two nerves that are infiltrated or treated with pulsed radiofrequency techniques are SSN and AN. There is very little evidence on the use of radiofrequency ablation of the terminal branches of these nerves, although modifications of the classical techniques have been described for minimizing motor component injury.<sup>28</sup>

The SSN nerve is located sonographically in the SSN fossa that is immediately deep to the superior transverse scapular ligament (STSL). The nerve is not always visible, but the curved shape of the fossa and the visualization of the SSN artery, usually superficial to the STSL, help to locate the nerve (Figure 4). The needle is inserted in plane from medial to lateral, and in its final position, sensory and motor stimulations of the nerve must be performed for more precision in the case of using pulsed

radiofrequency techniques.<sup>29</sup> Another alternative technique, used in infiltrations but not in radiofrequency techniques, is to locate the SSN at the level of the spinoglenoid fossa, where most of the lateral articular branches will have already occurred, but which has the advantage of being able to complete the procedure with an intra-articular technique in a single act (Figure 5). This last technique allows in-plane approach from both medial to lateral and lateral to medial.

The articular branches of the AN accompany the circumflex artery, and we can find it at the level of the humeral neck just below the teres minor in its humeral insertion. We can follow the circumferential path of the artery and locate the nerve branches with a hypoechoic oval appearance at the superficial level of the periosteum (Figure 6). The technique is performed in plane, with a coronal or axial approach according to preferences. In the case of using radiofrequency, we recommend using the pulsed technique to avoid motor injuries. The evidence of this type of techniques on the AN is based on a series of case, so it is advisable to assess the patient individually.<sup>30</sup>

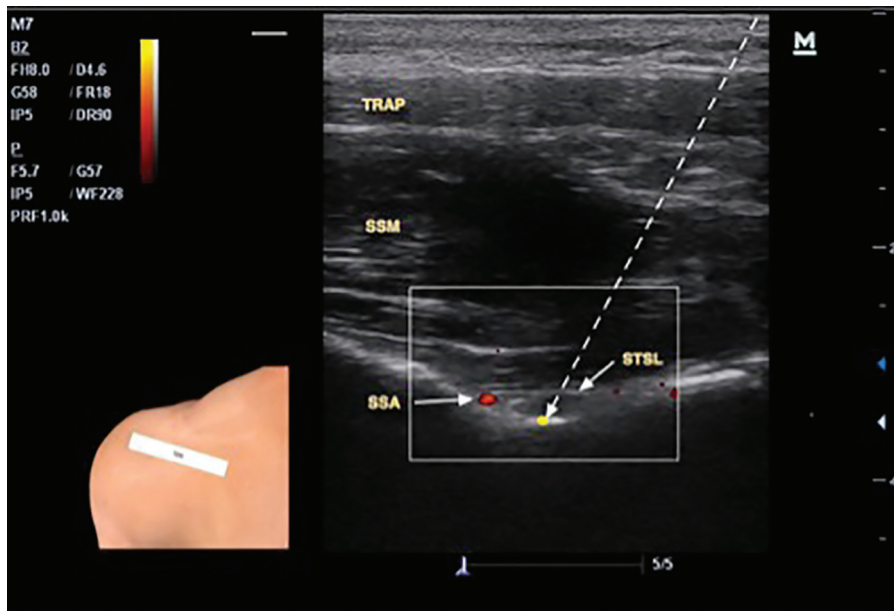
## Hip

### Hip joint

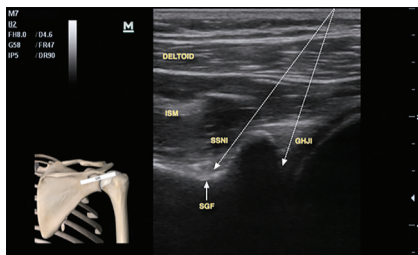
The hip joint can present inflammatory, mechanic, crystalline, or septic pathologies. It is usually necessary to have access to it to perform, on the one hand, diagnostic techniques such as aspiration of synovial fluid for analysis, for example contrast injection for MRI or CT scan, and on the other hand, therapeutic techniques, such as the injection of corticosteroids, radioactive isotopes, or other therapeutic substances in the hip.

Ultrasonographically, we can observe the presence of capsule distension caused by the presence of fluid or synovial hypertrophy, osteophytes, erosions, irregularity of the bone cortex, and the possible presence of the iliopsoas bursa that is usually associated with joint pathology with leakage or synovitis.

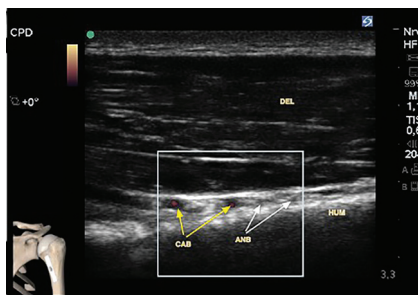
Some of its anatomical particularities make US guidance essential for the correct performance of the access technique. For instance, its depth is especially noticeable in heavily muscled, overweight, or obese patients, and the presence of the circumflex artery in the anterior recess side usually interferes in the path of the needle. In this case, several factors can be contemplated to allow a safe procedure, which is effective and normally painless: the patient in the supine decubitus position, with discreet external rotation of the limb to be treated, the use of a probe, normally



**Figure 4.** Ultrasonographic image for the nerve block or radiofrequency of the suprascapular nerve at the level of the suprascapular fossa. TRAP, trapezius muscle; SSM, supraspinatus muscle; SSA, suprascapular artery; SSTL, superior transverse scapular ligament; dotted line, recommended approach for in-plane puncture from medial to lateral; yellow dot, suprascapular nerve.



**Figure 5.** Ultrasonographic image for localization of the suprascapular nerve at the level of spinoglenoid fossa and its combination with an intra-articular technique. DEL, deltoid muscle; ISM, infraspinatus muscle; SGF, spinoglenoid fossa; GHJI, glenohumeral joint infiltration; SSNI, suprascapular nerve infiltration.



**Figure 6.** Ultrasonographic image for the localization of the posterior branch(es) of the AN at the humeral level. The image is somewhat prior to the insertion of the teres minor muscle, which, together with the circumflex artery, will serve as a guide for the localization of the AN and its branches.

Convex 3-5 HMz, the Doppler to visualize the neighboring vessels, and the use of local anesthesia by planes<sup>31-34</sup> (Figures 7 and 8).

#### Trochanteric pain syndrome

Trochanteric pain syndrome is very common in clinical practice. In the lateral joint side, the trochanteric, the gluteus medius, and minor and fascia lata tendons are inserted and can be seen, together with their bursae, by US. These tendons very frequently present alterations in the form of tendinosis, partial or total breaks, or calcifications in their sinus. The trochanteric bursitis is often associated with degenerative tendon pathology, especially breaks, and it can also appear distended by

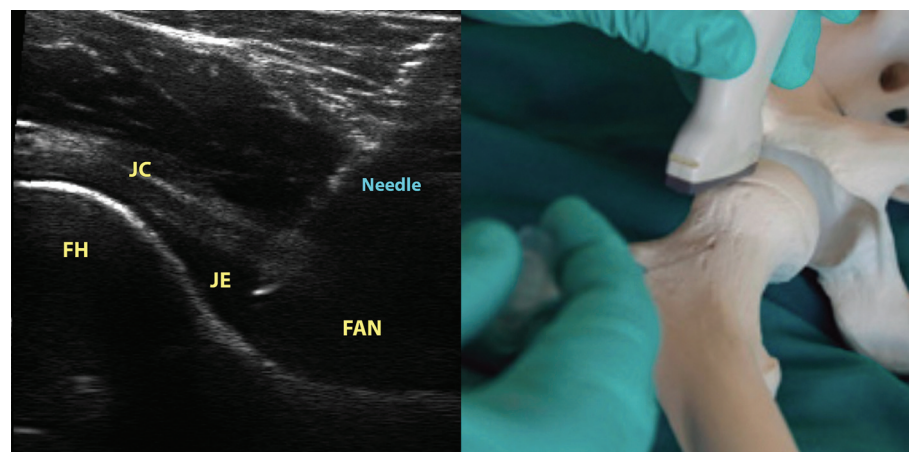
fluid or synovial proliferation in inflammatory pathologies such as polymyalgia rheumatica.

Using the US, we can also treat, with targeted puncture, tendon conditions, including puncture-lavage of calcifications, as well as the different bursae, which can be affected, with complete accuracy. Normally, the position of the patient will be in lateral decubitus on the unaffected side, in which case the 5/12 HMz linear high frequency probe is indicated. We always recommend the use of flat local anesthesia (lidocaine 2% 4mL) for greater patient comfort.<sup>35,36</sup> (Figure 9).

#### Femoral and obturator nerves blockade

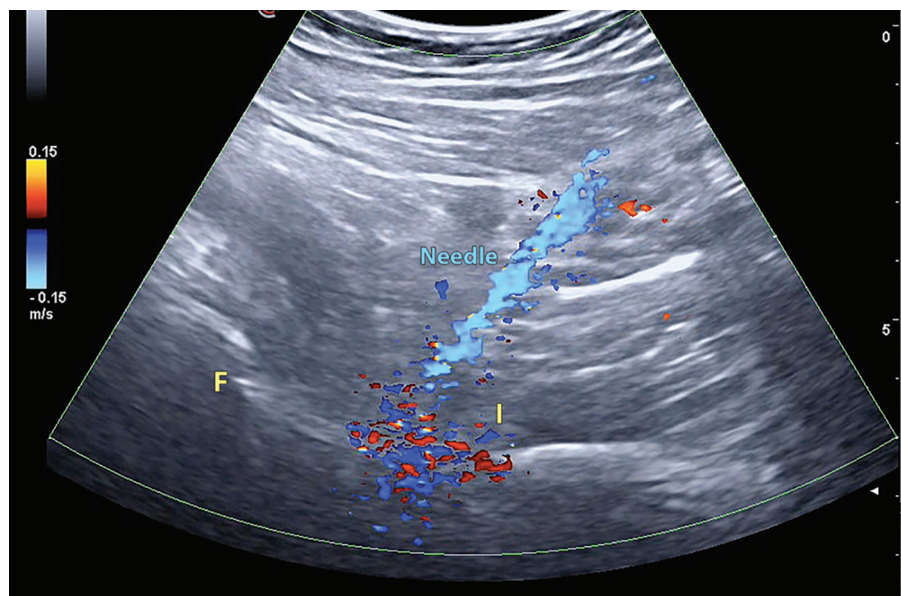
The hip joint and its capsule are mainly innervated by the obturator, the accessory obturator (if present) and femoral nerves on its anterior side, and by the superior gluteal nerve and articular branches for the quadratus femoris on its posterior side (Figure 10). Numerous anatomical variabilities of the nerves involved have been described, so it is recommended to perform diagnostic blocks with local anesthetic before proceeding to radiofrequency lesioning techniques, which should show a significant reduction in the patient's usual pain.<sup>37</sup> The characteristic pain in the inguinal region depends mostly on the obturator nerve, whose articular sensory branch can be blocked or destroyed with radiofrequency without affecting the motor component of the nerve. In patients with pain in the anterolateral side, more typical after hip arthroplasty, we prefer to also treat the articular branches of the femoral nerve.

The obturator sensory branch is located in the acetabular notch formed by the convergence of the pubis and ischium, medial to the femoral head, and lateral to the obturator foramen (Figure 11). With the patient's hip slightly abducted and external rotation and knee

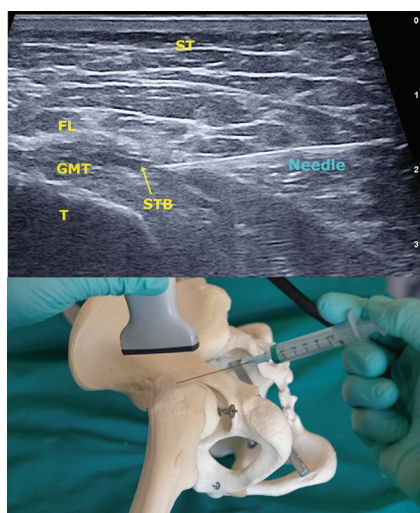


**Figure 7.** US-guided procedure in hip joint. JC, joint capsule; FH, femoral head; JE, joint effusion; FAN, femoral anatomical neck.



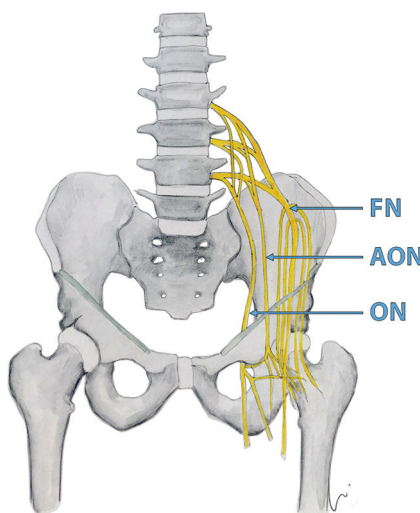


**Figure 8.** US-guided procedure in hip joint using Doppler effect. F, femur; I, injectate.



**Figure 9.** US-guided procedure in trochanter structure. ST, subcutaneous tissue; FL, fascia lata; GMT, gluteus medius tendon; T, trochanter; STB, superficial trochanter bursa.

flexion of 20°, we will move the transducer with an inclination of about 30° caudo-cranial from a cranial position (aligned with the long axis of the acetabulum) to the caudal (femoral head), and we will look for the intersection of both structures on their medial side. We will advance the radiofrequency cannula in a mid-lateral and caudo-cranial orientation to a depth of approximately half of the femoral head, where we will perform a sensory stimulation at 50Hz and <0.5V, which should be consistent with the patient's groin pain, and we should not obtain a motor response at 2Hz and 2.5V. In the case of not obtaining the expected responses, we will reposition the cannula in a more medial, cranial, and



**Figure 10.** Anatomical representation of the partial hip innervation. FN, femoral nerve; ON, obturator nerve; AON, accessory obturator nerve. The original artwork was created by Tanit Gómez and published with her permission.

deeper positions. We will make two lesions of 90° to 80°, which will be enough to obtain the expected analgesic response.

The nearby branches of the femoral nerve (originating above the inguinal ligament) pass between the anterior inferior iliac spine and the ilio-pubic eminence.<sup>38</sup> In normal practice, we will infiltrate the periosteal level of the ilio-pubic eminence, where we will find the accessory obturator nerve branches as well, if present. More distally and at the superficial level of the capsule in the acetabular convergence, we will find the distal branches of the

same femoral nerve (Figures 12 and 13). The closer to the joint capsule, the less motor component we can find. In the event that we need to perform radiofrequency lesioning techniques, we must find sensitive stimuli consistent with the patient's pain in his lateral hip at <0.5V and absence of significant motor stimulus at >2.5V.

Common indications are hip pain that does not respond to infiltrations or chronic postsurgical pain.<sup>37</sup>

Acceptable analgesic and functional results are based on a series of cases, so we must be cautious about recommending these techniques universally. Hemorrhagic complications and loss of skin sensitivity have been described in the dependent territories.<sup>37</sup>

## Knee

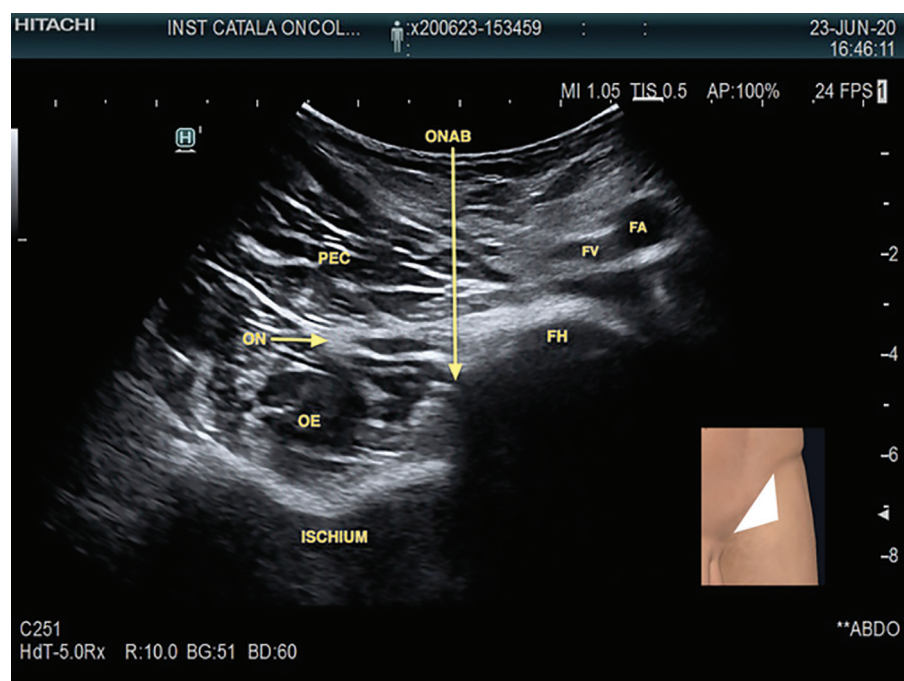
The knee is a large and complex load-bearing joint, which is frequently compromised by pathology. Ultrasonography of the knee allows an excellent study of the majority of its structures: muscles, tendons, ligaments, bursa, nerves, and vessels.<sup>39</sup> In contrast, with the menisci and the posterior and anterior cruciate ligaments, although partially visible by US, this is not the technique of choice.

The US study of the knee is divided into four faces: anterior, posterior, lateral, and medial. In general, multifrequency linear probes of around 10-12 MHz are used. Occasionally, lower frequency probes may be useful for studying the popliteal cavity in obese people, such as a 3-5 HMz convex probe.

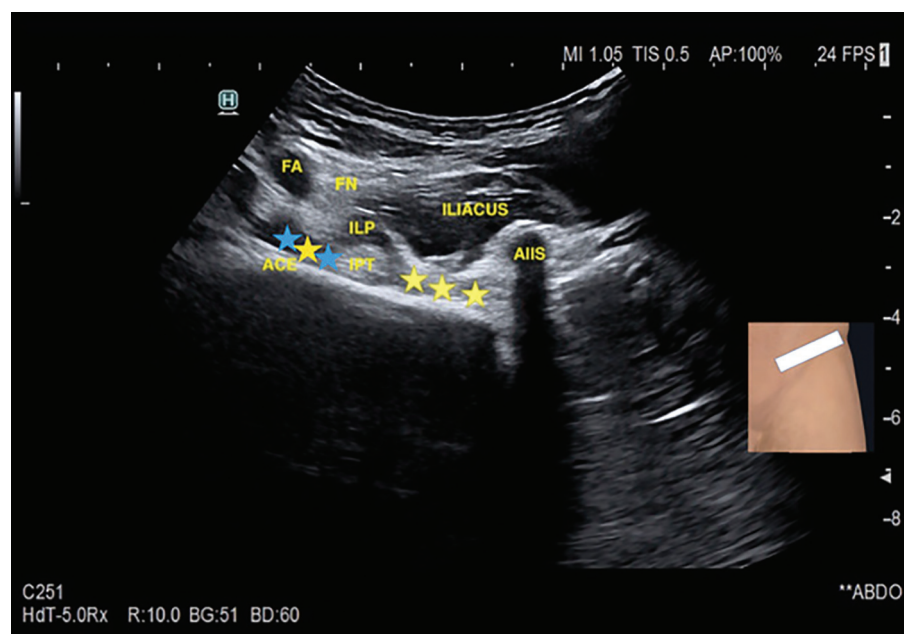
Synovitis of the knee can be caused both by a mechanical pathology and by an inflammatory pathology, either acute or chronic. It is a joint that, due to its accessibility, is always susceptible to arthrocentesis and infiltrations. Although knee joint puncture is a simple technique, the US-guided approach improves precision and cost-effectiveness, avoids puncturing bone or cartilage, and allows selecting the best location for puncture.<sup>40-42</sup>

## Knee joint

Synovitis of the knee can be observed in the supra quadricepsal bursa and in medial and lateral parapatellar recesses as a hypoechoic or anechoic image.<sup>39,43</sup> US-guided puncture is indicated for therapeutic purposes or for fluid analysis. The patient is placed on the stretcher in the supine position with the knee extended or with a slight flexion of about 30° with the knee resting on a pillow for patient comfort. There are several approaches to perform the puncture. Park et al.<sup>44</sup> compared different approaches to the knee of US-guided



**Figure 11.** Ultrasonographic image for blocking or radiofrequency of the articular branch of the obturator nerve. Hip in slight abduction, external rotation and knee flexion of 20°, we will move the transducer distally from an initial position aligned with the iliopubic branch and inclination of about 30° caudo-cranial. We must find an image where we see, on the same plane, the ischium and the femoral head (or the acetabular notch). ONAB, articular branch of the obturator nerve; PEC, pectineus muscle; ON, obturator nerve; FH, femoral head; OE, external oblique muscle; FV, femoral vein; FA, femoral artery.



**Figure 12.** Ultrasonographic image for blocking or radiofrequency of the cranial articular branches of the femoral nerve. Transducer in a 20° oblique position at the level of the anterior inferior iliac spine. AIIS, anterior inferior iliac spine; ACE, acetabulum-iliopubic eminence; ILP, iliopsoas muscle and its tendon; FN, femoral nerve; FA, femoral artery; Stars, points where we will find the superior articular terminal branches of the femoral nerve.

infiltration. Their study showed accuracy rates of 100% for the superolateral approach, 95% for the mediolateral approach, and 75% for the medial approach.<sup>44</sup> The lateral approach

looking for the supra quadricipital bursa is the most widely used route. It is performed with the probe in the transverse axis, which allows the needle to be seen in plane at all times

below the quadriceps tendon and the suprapatellar fat. In general, you should not press with the tube, so that the needle enters easily and does not collapse, although sometimes it can help if you press on the medial side to improve emptying. A 21G intramuscular needle is usually used to infiltrate a mixture of corticosteroids and anesthetic. In the event that the liquid accumulates mainly on the medial side, the approach will be carried out on this side (Figure 14).

### Baker's cyst

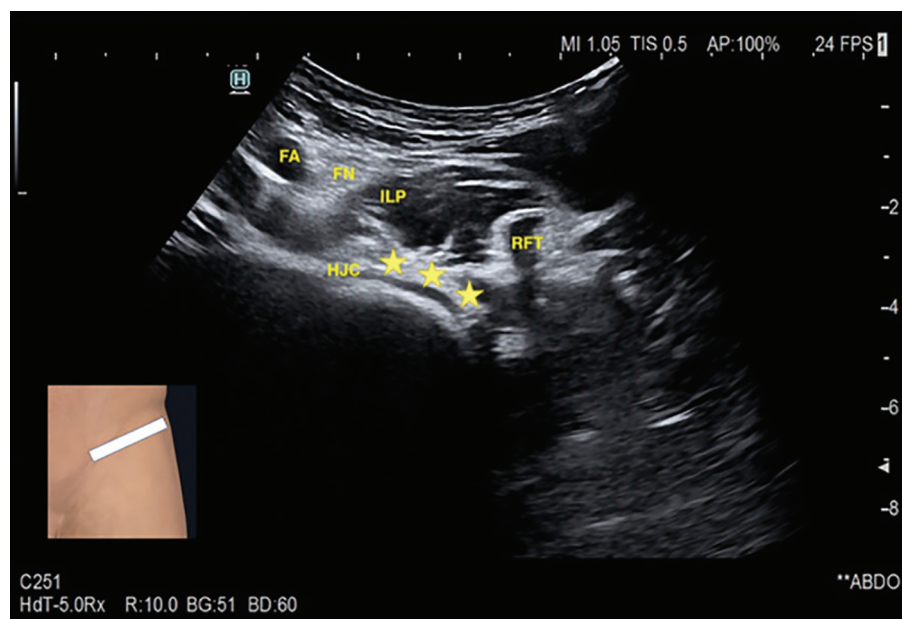
Regarding the knee's posterior face, although the anatomy and US of its examination are complex at a rheumatological level, we are primarily interested in studying the postero-medial part where the popliteal or Baker's cyst is located. The popliteal cyst is formed due to a communication between the knee joint and the semifibrous bursa-gastrocnemia. The cyst has three parts: base, neck, and body. The neck of the cyst acts as a valve and fills the body through pressure of the intra-articular fluid. Its size and its multilobed appearance are usually related to chronicity.<sup>45</sup> The main complication of the popliteal cyst is rupture and swelling of the leg, simulating, sometimes, a false thrombophlebitis.

Interventional US has become the technique of choice for the symptomatic treatment of Baker's cyst. It is an easy and safe procedure with good long-term results.<sup>46</sup> The cyst is visualized very well by US, allowing its shape, size, and internal composition to be defined: fluid, septa, and synovial hypertrophy. The base and neck of the cyst are best seen with the probe in the transverse axis, and the body with the probe in the longitudinal one. The neck of the cyst separates the tendon of the semimembrane from the tendon of the medial gastrocnemius. Symptomatic cysts should only be punctured for diagnostic purposes, when no effusion is observed in the anterior aspect of the knee. In order to perform puncture and emptying of the cyst, the patient's position must be in a prone position, with the knee extended and the foot protruding from the table. The best approach is with the probe in the longitudinal axis entering the plane through the lower pole of the cyst. The tip of the needle is located in the middle of the cyst, away from synovial hypertrophy. Thanks to the US-guided puncture, the cyst can be emptied completely, even though it is multilobed (Figure 15).

### Anserinus bursa

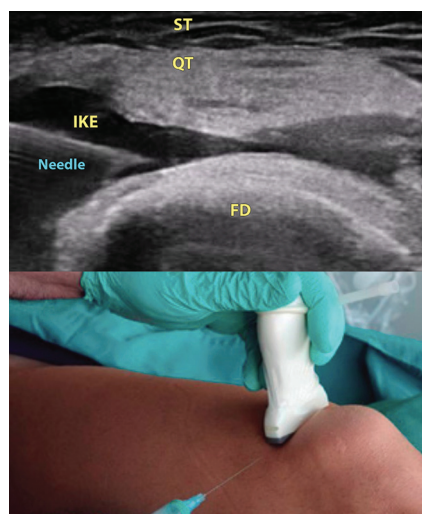
Pain in the medial aspect of the knee may be due to pathologies of the medial meniscus, tendinitis, and bursitis of the anserinus insertion, medial plica syndrome, or other less frequent





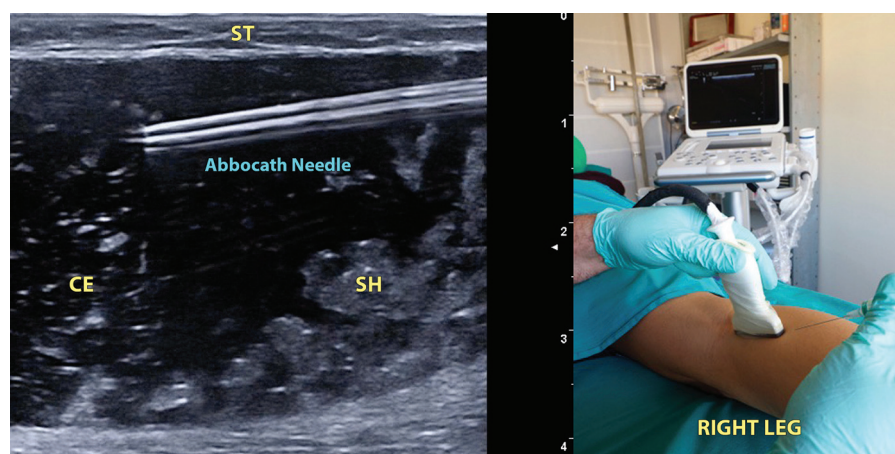
**Figure 13.** Ultrasonographic image for blocking or radiofrequency of the lower articular branches of the femoral nerve. Transducer in a 20° oblique position, which identifies the most cranial area of the femoral head. ILP, iliopsoas muscle; FN, femoral nerve; FA, femoral artery; HJC, hip joint capsule; RFT, rectus femoris muscle; Stars, points where we will find the superior articular terminal branches of the femoral nerve.

causes, such as saphenous entrapment neuropathy<sup>47</sup> or bursitis and calcifications of the medial collateral ligament.<sup>48</sup> On the lateral aspect, in addition to meniscal and ligamentous pathologies, iliotibial band tendinopathy can be found in its insertion, frequent in sports. Treatment of these processes may include eco-directed procedures for aspiration of collections of parameniscal cysts or bursitis, and percutaneous injection of corticosteroids (Figure 16).



**Figure 14.** US-guided procedure in knee joint. Femoropatellar lateral access. ST, subcutaneous tissue; QT, quadriceps tendon; IKE, intraarticular knee effusion; FD, femoral dyapaphsis.

One of the most frequent processes potentially treatable by US-guided puncture is anserine bursitis. Bursitis or tendonitis of the anserinus insertion produces pain of a gradual course on the inner side of the knee, due to a mechanical inflammation of the bursa present at the insertion of the tendons of the sartorius, internal rectus, and semitendinosus muscles. It has been linked to genu valgus, obesity, osteoarthritis, rheumatoid arthritis, and diabetes mellitus. In a prospective study, the incidence of US bursitis in patients with osteoarthritis was 20%, being more common in women and in older age.<sup>49</sup>



**Figure 15.** US-guided procedure in Baker's cyst. ST, subcutaneous tissue; CE, cyst effusion; SH, synovial hypertrophy.

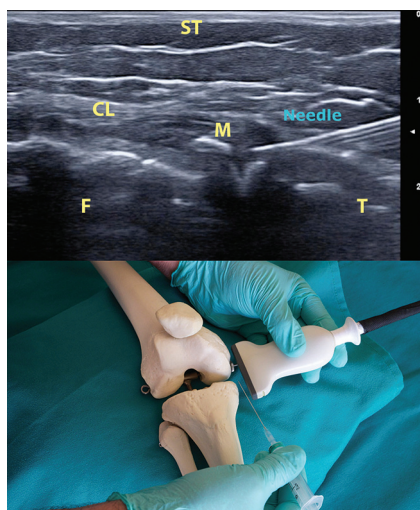
In order to perform the procedure, it is recommended to position the patient in the supine position, with the hip in external rotation and the knee slightly flexed to identify the tendon insertions, as they pass over the medial collateral ligament. This ligament, in its distal insertion, is deeply located to the tendons. The bursa anserina, when viewed, appears deep to the tendons and superficial to the medial collateral ligament. Transducer angulation, so that the tendons appear anisotropic, can facilitate differentiation with the medial collateral ligament.<sup>50</sup>

Efficacy with regard to blind infiltration, in a recent study and in line with previous studies, observed greater precision of US-guided injection, and with better clinical results, although only evaluated in the short term (4 weeks).<sup>51</sup>

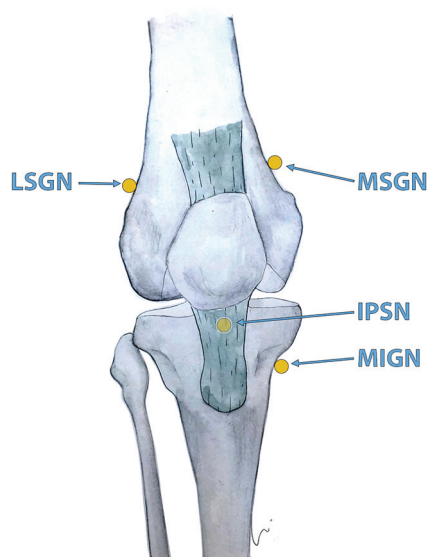
### Genicular and saphenous nerves blockade

The neuroanatomy of the knee is complex, from its capsule and ligaments to its bone structures. Up to 13 sensory (or mixed) endings of different nerves emerging from the lumbosacral plexus have been described, all of which are susceptible to being treated with interventional techniques ranging from simple infiltration to radio frequency lesioning (ablation). The multiple anatomical variabilities, both in the proximal contributions to these nerve endings and the area they innervate in a specific individual, make the design of really precise studies complex and would explain why the results are highly variable.<sup>52-54</sup> In a day-to-day practice, the most frequent targets are the genicular nerves: superior lateral (SLGN), superior medial (SMGN), and inferior medial (IMGN) in its distal route over the periosteum. The infrapatellar branch of the saphenous nerve is also frequently blocked, especially in patients with cutaneous allodynia on the inside of the knee (Figure 17). Radio



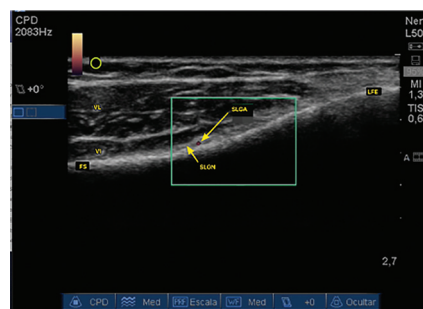


**Figure 16.** US-guided procedure in medial interline of the knee. ST, subcutaneous tissue; CL, collateral ligament; M, meniscus; F, femur; T, tibia.

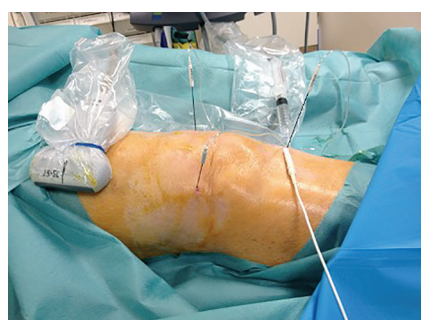

**Figure 17.** Anatomical localization of the puncture points used to blockade the genicular and infrapatellar branch of the saphenous (IPSN) nerves. MSGN, medial superior genicular nerve; MIGN, medial inferior genicular nerve; LSGN, lateral superior genicular nerve. The original artwork was created by Tanit Gómez and published with her permission.

frequency techniques are indicated when the result obtained with joint infiltration techniques is insufficient, and after having performed a diagnostic nerve block which has shown that the patient's nociception comes from these nerve structures. Complications, though rare, include bleeding from injury to the genicular arteries, as well as the hypothetical possibility of contributing to the development of Charcot arthropathy due to denervation in extensive and multiple injuries.



**Figure 18.** Ultrasonographic image of the superior lateral genicular nerve. VL, vastus lateralis; VM, vastus medialis; SLGN, superior lateral genicular nerve; FS, femoral shaft; SLGA, superior lateral genicular artery; LFC, lateral femoral condyle.



**Figure 19.** Final position of the radio frequency cannulae for the three genicular nerves described.

Radio frequency ablation of genicular nerves with US is based on locating the genicular nerves at the level of the femoral midline at the junction of the shaft with the medial (MSGN) and lateral epicondyle (LSGN) and at the level of the tibial midline at the junction from the shaft to the medial tibial condyle we will find the IMGN.<sup>52,55</sup> On many occasions, we will be able to find the genicular arteries in a location immediately proximal to the joint, which will help us to locate the nerve and will prevent hemorrhagic complications if we avoid them (Figures 18 and 19). Explaining the radio frequency lesioning techniques is going beyond the objective of this work, but, basically, it is a neurodestructive technique by means of heat (80°C), using needles with an active tip of 5-10 mm after checking, by means of a sensory stimulation with an electric current at 50 Hz, the distribution of pain in the usual area(s). A 2 Hz motor stimulation is also used prior to injury to rule out that the nerve to be injured has a motor component.

## Conclusion

For the past 20 years, we have witnessed the evolution of the musculoskeletal system interventions via US. As mentioned at the begin-

ning of this article, our purpose is to give just a glimpse of the possibilities that these techniques offer for the therapeutic objectives that are treatable with US-guided puncture. However, this process does not stop here. In the future, we will continue to witness a technological evolution that will improve further the utility of the US devices, allowing the creation and development of new procedures and techniques that will continue to get us closer to patient care excellency.

Allow us to conclude with a sentence from Eugene McNally<sup>56</sup> "Whether you are looking for new skill or refine older ones, I envy some of the joy you will feel applying what you will learn [...]"

**Peer-review:** Externally peer-reviewed.

**Author Contributions:** Concept - E.G.C., V.M.R., A.P.F., M.P.B., M.S.L.; Design - E.G.C., V.M.R., A.P.F., M.P.B., M.S.L.; Supervision - E.G.C.; Literature Search - E.G.C., V.M.R., A.P.F., M.P.B., M.S.L.; Writing Manuscript - E.G.C., V.M.R., A.P.F., M.P.B., M.S.L.; Critical Review - E.G.C., V.M.R., A.P.F., M.P.B., M.S.L.

**Acknowledgments:** The authors would like to thank Dr. Jaume Cardus for providing the model pictures, Tanit Gómez for the anatomical artwork, and Marc Gómez for the editing support.

**Conflict of Interest:** The authors have no conflicts of interest to declare.

**Financial Disclosure:** The authors declared that this study has received no financial support.

## References

- Hollander JL, Brown EM Jr, Jessar RA, Brown CY. Comparative effects of compound F (17-hy-droxcorticosterone) and cortisone injected locally into the rheumatoid arthritis joint. *Ann Rheum Dis.* 1951;10:473-476.
- Bianchi S, Zamorani P. US-guided interventional procedures. In Bianchi S, Martinoli C (eds.): *Ultrasound of the Musculoskeletal System*. Berlin: Springer, 2007: 891-917.
- Bruyn GA, Iagnocco A, Naredo E, et al. OMERACT ultrasound working group. OMERACT definitions for ultrasonographic pathologies and elementary lesions of rheumatic disorders 15 years On. *J Rheumatol.* 2019;46:1388-1393. [\[CrossRef\]](#)
- Gilliland CA, Salazar LD, Borchers JR. Ultrasound versus anatomic guidance for intra-articular and periarticular injection: A systematic review. *Phys Sportsmed.* 2011;39:121-131. [\[CrossRef\]](#)
- Park KD, Kim TK, Lee J, Lee WY, Ahn JK, Park Y. Palpation versus ultrasound-guided acromioclavicular joint intra-articular corticosteroid injections: A retrospective comparative clinical study. *Pain Phys.* 2015;18(4):333-341. [\[Cross-Ref\]](#)

6. Kane D, Koski J. Musculoskeletal interventional procedures: With or without imaging guidance? *Best Pract Res Clin Rheumatol*. 2016;30(4):736-750. [\[CrossRef\]](#)
7. Cazenave T, Pineda C, Reginato AM, Gutierrez M. Ultrasound-guided procedures in rheumatology: What is the evidence? *J Clin Rheumatol*. 2015;21(4):201-210. [\[CrossRef\]](#)
8. Morillas-Sendin P, Ortega-Romero A, del-Olmo C. Basic considerations before injections and scanning techniques. *Tech Reg Anesth Pain Manag*. 2013;17(3):53-63.
9. Ortega-Romero A. Use of ultrasound for interventions in patients with chronic pain. *Tech Reg Anesth Pain Manag*. 2013;17(3):51-52. [\[CrossRef\]](#)
10. Peng P. *Ultrasound for Interventional Pain Management*. Berlin: Springer, 2020. DOI: 10.1007/978-3-030-18371-4. [\[CrossRef\]](#)
11. Pourcho AM, Colio SW, Hall MM. Ultrasound-guided interventional procedures about the shoulder: Anatomy, indications, and techniques. *Phys Med Rehabil Clin N Am*. 2016;27:555-572. [\[CrossRef\]](#)
12. Messina C, Banfi G, Orlandi D, et al. Ultrasound-guided interventional procedures around the shoulder. *Br J Radiol*. 2016;89:20150372.
13. Park KD, Nam HS, Lee JK, Kim YJ, Park Y. Treatment effects of ultrasound-guided capsular distension with hyaluronic acid in adhesive capsulitis of the shoulder. *Arch Phys Med Rehabil*. 2013;94:264-270. [\[CrossRef\]](#)
14. Eustace JA, Brophy DP, Gibney RP, Bresnihan B, Fitzgerald O. Comparison of the accuracy of steroid placement with clinical outcome in patients with shoulder symptoms. *Ann Rheum Dis*. 1997;56:59-63. [\[CrossRef\]](#)
15. Juel NG, Oland G, Kvalheim S, Løve T, Ekeberg OM. Adhesive capsulitis: One sonographic-guided injection of 20 mg triamcinolone into the rotator interval. *Rheumatol Int*. 2013;33:1547-1553. [\[CrossRef\]](#)
16. Pourcho AM, Sellon JL, Smith J. Sonographically guided sternoclavicular joint injection: Description of technique and validation. *J Ultrasound Med*. 2015;34:325-331. [\[CrossRef\]](#)
17. Van Holsbeeck M, Strouse PJ. Sonography of the shoulder: Evaluation of the subacromial-subdeltoid bursa. *Am J Roentgenol*. 1993;160:561-564. [\[CrossRef\]](#)
18. Arroll B, Goodyear-Smith F. Corticosteroid injections for painful shoulder: A meta-analysis. *Br J Gen Pract*. 2005;55:224-228.
19. Naredo E, Cabero F, Beneyto P, et al. A randomized comparative study of short term response to blind injection versus sonographic-guided injection of local corticosteroids in patients with painful shoulder. *J Rheumatol*. 2004;31:308-314.
20. Nho SJ, Strauss EJ, Lenart BA, et al. Long head of the biceps tendinopathy: Diagnosis and management. *J Am Acad Orthopaedic Surg*. 2010;18:645-656.
21. Hashiuchi T, Sakurai G, Morimoto M, Komei T, Takakura Y, Tanaka Y. Accuracy of the biceps tendon sheath injection: Ultrasound-guided or unguided injection? A randomized controlled trial. *J Shoulder Elb Surg*. 2011;20:1069-1073. [\[CrossRef\]](#)
22. Scarpone M, et al. Effectiveness of platelet-rich plasma injection for rotator cuff tendinopathy: A prospective open-label study. *Glob Adv Health Med*. 2013;2:26-31. [\[CrossRef\]](#)
23. Serafini G, et al. Rotator cuff calcific tendonitis: Short-term and 10-year outcomes after two-needle US-guided percutaneous treatment—Nonrandomized controlled trial. *Radiology*. 2009;252:157-164. [\[CrossRef\]](#)
24. Farin PU, Jaroma H, Soimakallio S. Rotator cuff calcifications: Treatment with US-guided technique. *Radiology*. 1995;195:841-843. [\[CrossRef\]](#)
25. Tagliafico A, et al. Ultrasound-guided interventional procedures around the shoulder. *Radiol Med*. 2014;119:318-326. [\[CrossRef\]](#)
26. Aina R, Cardinal E, Bureau NJ, et al. Calcific shoulder tendinitis: Treatment with modified US-guided fine-needle technique. *Radiology*. 2001;221:455-461. [\[CrossRef\]](#)
27. Tran J, Peng PWH, Agur AMR. Anatomical study of the innervation of glenohumeral and acromioclavicular joint capsules: Implications for image-guided intervention. *Regional Anesth Pain Med*. 2019;44:452-458. [\[CrossRef\]](#)
28. Eckmann MS, et al. Terminal sensory articular nerve radiofrequency ablation for the treatment of chronic intractable shoulder pain: A novel technique and case series. *Pain Med*. 2020;21:868-871. [\[CrossRef\]](#)
29. Ergonen T, Beyaz SG. Effects of ultrasound-guided suprascapular nerve pulsed radiofrequency on chronic shoulder pain. *Med Ultrason*. 2018;20:461-466. [\[CrossRef\]](#)
30. Esparza-Miñana JM, Mazzinari G. Adaptation of an ultrasound-guided technique for pulsed radiofrequency on axillary and suprascapular nerves in the treatment of shoulder pain. *Pain Med*. 2019;20:1547-1550. [\[CrossRef\]](#)
31. Sakellariou G, Conaghan PG, Zhang W, et al. EULAR recommendations for the use of imaging in the clinical management of peripheral joint osteo-arthritis. *Ann Rheum Dis*. 2017;76(9):1484-1494. [\[CrossRef\]](#)
32. Möller I, Bong D. Ultrasound-guided pain interventions in the hip region. *Tech Reg Anesth Pain Manag*. 2013;17(3):140-149. [\[CrossRef\]](#)
33. Balog TP, Rhodehouse BB, Turner EK, et al. Accuracy of ultrasound-guided intra-articular hip injections performed in the orthopedic clinic. *Orthopedics*. 2017;40(2):96-100. [\[CrossRef\]](#)
34. Hoeber S, Aly AR, Ashworth N, Rajasekaran S. Ultrasound-guided hip joint injections are more accurate than landmark-guided injections: A systematic review and meta-analysis. *Br J Sports Med*. 2016;50(7):392-396. [\[CrossRef\]](#)
35. Segal NA, Felson DT, Torner JC, et al. Greater trochanteric pain syndrome: Epidemiology and associated factors. *Arch Phys Med Rehabil*. 2007;88(8):988-992. [\[CrossRef\]](#)
36. McEvoy JR, Lee KS, Blankenbaker DG, del Rio AM, Keene JS. Ultrasound-guided corticosteroid injections for treatment of greater trochanteric pain syndrome: Greater trochanter bursa versus subgluteus medius bursa. *Am J Roentgenol*. 2013;201:W313-W317. [\[CrossRef\]](#)
37. Bhatia A, Hoydonckx Y, Peng P, Cohen SP. Radiofrequency procedures to relieve chronic hip pain. *Tech Reg Anesth Pain Manag*. 2018;43:72-83. [\[CrossRef\]](#)
38. Short AJ, et al. Anatomic study of innervation of the anterior hip capsule. *Tech Reg Anesth Pain Manag*. 2018;43:186-192.
39. Vlad V, Iagnocco A. Ultrasound of the knee in rheumatology. *Med Ultrason*. 2012;14(4):318-325.
40. Balint PV, Kane D, Hunter J, McInnes IB, Max F, Roger SD. Ultrasound guided versus conventional joint and soft tissue fluid aspiration in rheumatology practice: A pilot study. *J Rheumatol*. 2002;29:2209-2213.
41. Berkoff DJ, Miller LE, Block JE. Clinical utility of ultrasound guidance for intra-articular knee injections: A review. *Clin Interv Aging*. 2012;7:89-95.
42. Wu T, Dong Y, Song HX, Fu Y, Li JH. Ultrasound-guided versus landmark in knee arthrocentesis: A systematic review. *Semin Arthritis Rheum*. 2016;45(5):627-632.
43. Sibbitt WL Jr, Band PA, Kettwich LG, et al. A randomized controlled trial evaluating the cost-effectiveness of sonographic guidance for intra-articular injection of the osteoarthritic knee. *J Clin Rheumatol*. 2011;17(8):409-415. [\[CrossRef\]](#)
44. Park Y, Lee SC, Nam HS, Lee J, Nam SH. Comparison of sonographically guided intra-articular injections at 3 different sites of the knee. *J Ultrasound Med*. 2011;30(12):1669-1676. [\[CrossRef\]](#)
45. Helbich TH, Breitenseher M, Trattning S, et al. Sonomorphologic variants of popliteal cysts. *J Clin Ultrasound*. 1998;26:171-176. [\[CrossRef\]](#)
46. Smith MK, Lesniak B, Baraga MG, Kaplan L, Jose J. Treatment of popliteal (baker) cysts with ultrasound-guided aspiration, fenestration, and injection: Long-term follow-up. *Sports Health*. 2015;7(5):409-414. [\[CrossRef\]](#)
47. Morganti CM, McFarland EG, Cosgarea AJ. Saphenous neuritis: A poorly understood cause of medial knee pain. *J Am Acad Orthop Surg*. 2002;10(2):130-137. [\[CrossRef\]](#)
48. Galletti L, Ricci V, Andreoli E, Galletti S. Treatment of a calcific bursitis of the medial collateral ligament: A rare cause of painful knee. *J Ultrasound*. 2019;22(4):471-476. [\[CrossRef\]](#)
49. Uysal F, Akbal A, Gökmen F, Adam G, Reşorlu M. Prevalence of pes anserine bursitis in symptomatic osteoarthritis patients: An ultrasonographic prospective study. *Clin Rheumatol*. 2015;34:529-533. [\[CrossRef\]](#)
50. Lueders DR, Smith J, Sellon JL. Ultrasound-guided knee procedures. *Phys Med Rehabil Clin N Am*. 2016;27:631-648. [\[CrossRef\]](#)
51. Lee JH, Lee JU, Yoo SW. Accuracy and efficacy of ultrasound-guided pes anserinus bursa injection. *J Clin Ultrasound*. 2018;47:77-82.
52. Roberts SL, Stout A, Dreyfuss P. Review of knee joint innervation: Implications for diagnostic blocks and radiofrequency ablation. *Pain Med Malden Mass*. 2020;21:922-938. [\[CrossRef\]](#)
53. Tran J, et al. Anatomical study of the innervation of anterior knee joint capsule: Implication for image-guided intervention. *Tech Reg Anesth Pain Med*. 2018;43:407-414. [\[CrossRef\]](#)
54. Tabasco MMM, Amatria GR, Márquez NR, Capel YJ, Bernal DS. Valoración de la efectividad y



seguridad de dos técnicas de radiofrecuencia Para el tratamiento de la gonalgia secundaria a gonartrosis. Estudio prospectivo randomizado doble ciego. *Revista Española Anestesiología Reanimación*. 2019;66:362-369.

55. Kim D-H, et al. A prospective randomized comparison of the efficacy of ultrasound- vs fluoroscopy-guided genicular nerve block for chronic knee osteoarthritis. *Pain Physician*. 2019;22:139-146.

56. Guerini H, Drapé J-L. Preface Eugene McNally in *Infiltrations échoguidées en pathologie musculo squelettique*. 2nd Edition, Elsevier Masson 2019. ISBN: 978-2-294-75998-7.