

## Single Case Report

# Can the knight capture the queen? The role of supramarginal gyrus in chess rule-retrieval as evidenced by a novel combined awake brain mapping and fMRI protocol

Victor Cepero-Escribano <sup>a,b,c</sup>, Xim Cerda-Company <sup>a,b,c,d,\*\*</sup>,  
 Patricia León-Cabrera <sup>e</sup>, Guillem Olivé <sup>a,b</sup>, David Cucurell <sup>a,b</sup>,  
 Anna Gasa-Roqué <sup>b,f,k</sup>, Andreu Gabarrós <sup>h,m</sup>, Pablo Naval-Baudin <sup>g,i,j</sup>,  
 Àngels Camins <sup>g,i,j</sup>, Immaculada Rico <sup>f</sup>, Alejandro Fernández-Coello <sup>h,m</sup>,  
 Joanna Sierpowska <sup>a,j,k</sup> and Antoni Rodríguez-Fornells <sup>a,b,k,l,\*</sup>

<sup>a</sup> Department of Cognition, Development, and Educational Psychology, Faculty of Psychology, University of Barcelona, Barcelona, Spain

<sup>b</sup> Cognition & Brain Plasticity Unit, Bellvitge Biomedical Research Institute (IDIBELL), Spain

<sup>c</sup> Computer Vision Centre (CVC), Universitat Autònoma de Barcelona, Bellaterra, Spain

<sup>d</sup> Computer Science Department, Universitat Autònoma de Barcelona, Bellaterra, Spain

<sup>e</sup> Department of Basic Sciences, Area of Psychology, Universitat Internacional de Catalunya (UIC), Sant Cugat del Vallès, Barcelona, Spain

<sup>f</sup> Hospital Universitari de Bellvitge (HUB), Neurology Section, Campus Bellvitge, University of Barcelona e IDIBELL, L'Hospitalet de Llobregat, Barcelona, Spain

<sup>g</sup> Institut de Diagnòstic per la Imatge, Centre Bellvitge, Hospital Universitari de Bellvitge, L'Hospitalet de Llobregat, Barcelona, Spain

<sup>h</sup> Hospital Universitari de Bellvitge (HUB), Neurosurgery Section, Campus Bellvitge, University of Barcelona e IDIBELL, L'Hospitalet de Llobregat, Barcelona, Spain

<sup>i</sup> Department of Radiology, Hospital Universitari de Bellvitge, Bellvitge, Translational Imaging Biomarkers Group, Bellvitge Biomedical Research Institute (IDIBELL), L'Hospitalet de Llobregat, Spain

<sup>j</sup> Bellvitge Biomedical Research Institute (IDIBELL), L'Hospitalet de Llobregat, Barcelona, Spain

<sup>k</sup> Institute of Neurosciences (UBNeuro), University of Barcelona, Barcelona, Spain

<sup>l</sup> Catalan Institution for Research and Advanced Studies (ICREA), Barcelona, Spain

<sup>m</sup> Department of Pathology and Experimental Therapeutics, Faculty of Medicine and Health Sciences, Campus Bellvitge, University of Barcelona, Spain

## ARTICLE INFO

## Article history:

Received 13 December 2023

Reviewed 24 January 2024

## ABSTRACT

Brain tumours represent a burden for society, not only due to the risks they entail but also because of the possibility of losing relevant cognitive functions for the patient's life after their resection. In the present study, we report how we monitored chess performance

\* Corresponding author. Department of Cognition, Development and Educational Psychology, University of Barcelona, Campus Bellvitge, Feixa Llarga, s/n, 08907, L'Hospitalet de Llobregat, Spain.

\*\* Corresponding author. Computer Vision Center, Edificio O, Campus UAB, 08193 Cerdanyola del Vallès, Barcelona, Spain.

E-mail addresses: [xcerda@cvc.uab.es](mailto:xcerda@cvc.uab.es) (X. Cerda-Company), [antoni.rodriguez@icrea.cat](mailto:antoni.rodriguez@icrea.cat) (A. Rodríguez-Fornells).

<https://doi.org/10.1016/j.cortex.2024.05.022>

0010-9452/© 2024 The Author(s). Published by Elsevier Ltd. This is an open access article under the CC BY-NC license (<http://creativecommons.org/licenses/by-nc/4.0/>).

Revised 22 March 2024  
 Accepted 15 May 2024  
 Action editor Paolo Bartolomeo  
 Published online 9 July 2024

#### Keywords:

Chess  
 Brain tumour  
 Electrical stimulation mapping  
 fMRI  
 Rule-retrieval  
 Left supramarginal gyrus

through a multimodal Electrical Stimulation Mapping (ESM) – functional Magnetic Resonance Imaging (fMRI) combined protocol. The ESM was performed under a left parietal lobe tumour resection surgery on a patient that expressed the desire to preserve his chess playing ability post-operative. We designed an ad-hoc protocol to evaluate processes involved in chess performance that could be potentially affected by the tumour location: (i) visual search, (ii) rule-retrieval, and (iii) anticipation of checkmate. The fMRI study reported functional regions for chess performance, some of them proximal to the lesion in the left parietal lobe. The most relevant result was a positive eloquent point encountered in the vicinity of the left supramarginal gyrus while performing the rule-retrieval task in the ESM. This functional region was convergent with the activations observed in the pre-operative fMRI study for this condition. The behavioural assessment comparison revealed post-operative an increase in reaction time in some tasks but correctness in performance was maintained. Finally, the patient maintained the ability to play chess after the surgery. Our results provide a plausible protocol for future interventions and suggest a role of the left supramarginal gyrus in chess cognitive operations for the case presented.

© 2024 The Author(s). Published by Elsevier Ltd. This is an open access article under the CC BY-NC license (<http://creativecommons.org/licenses/by-nc/4.0/>).

## 1. Introduction

Malignant brain tumours pose a significant burden on society. Complications like seizures, hypercoagulable states, as well as mood and cognitive disorders arise frequently and threaten quality adjusted life years (QALY; Kirkdale et al., 2010). While antitumoral treatments and supportive therapies can relieve some of this burden, patients often report side effects in the form of cognitive deficits (Nicol et al., 2019; Phillips et al., 2018; Schiff et al., 2015). Neuropsychologists aim to minimise cognitive decline through personalised assessments by paying attention to potentially impaired functions affected by the tumour location (Gasa-Roqué et al., 2023; Rofes et al., 2017; Satoer et al., 2014). Still, there is a growing need to retain cognitive functions related to patients' professions or hobbies to decrease disease burden.

In the aim of minimising cognitive deficits, electrical stimulation mapping (ESM) is a standard procedure to identify functional brain regions and maximise brain tumour resection. Concretely, it is widely applied to monitor and map language abilities (Duffau, 2015; Ojemann et al., 2008; Ojemann & Mateer, 1979; Penfield & Roberts, 1959; Vakani & Nair, 2019). In the present work we assess a patient diagnosed with a tumour in the left superior parietal lobe (SPL), who expressed a specific request: to preserve a relevant aspect of his identity—his ability to play chess.

Chess players show differences in brain volumes and activity depending on their expertise (Amidzic et al., 2001; Duan et al., 2012; Duan, Liao, et al., 2012; Gobet & Simon, 1996; Hänggi et al., 2014; Krawczyk et al., 2011). Thus, personalised ESM tasks are needed, to account for these individual differences. These tasks, previously tested on functional magnetic resonance imaging (fMRI), allowed us to evaluate multiple components involved in chess simultaneously (Nichelli et al., 1994; Gobet & Simon, 1996; Bratko et al., 2016).

The present study describes a single case of patient AB, who has 25 years of chess experience, and was diagnosed with a Glioblastoma in the left SPL. Notably, this region is crucial for

many processes during chess performance (Johns, 2014; Dehaene et al., 2003; Campitelli et al., 2005; Malouin et al., 2003). Interestingly, three chess-based tasks could be adapted from Nichelli et al. (1994) for an intraoperative setup. Specifically, during the ESM procedure, the patient was instructed to carry out three tasks. The first one, (i) *visual search*, required determining the presence of a given chessman in a chessboard. The second, (ii) *rule-retrieval*, asked whether a movement of a certain piece was legal or not. Finally, the third task, (iii) required the prediction of *checkmate* in a given chess game scenario, by deciding if the player could checkmate in one or two movements. Before surgery, these tasks were also adapted to a fMRI paradigm to identify the brain regions recruited during their performance, and to match them with the exposed area during the ESM.

## 2. Methods

### 2.1. Clinical information

The patient AB was admitted to the Neurosurgery Department of the University Hospital of Bellvitge after a headache with no cognitive impairment. The Unit of Pathological Anatomy diagnosed a highly suggestive hyper-uptake high grade glial neofoma in the left parietal area identified as a Glioblastoma IDH-wildtype (Grade 4 WHO 2021) (Louis et al., 2021). The patient was 45 years old, right-handed, male and Spanish-Catalan-English multilingual. He worked as a professional computer programmer and played chess for the last 25 years, with an ELO score of 1950 (a skill rating score based on previously played games). The patient expressed his concern for the preservation of chess playing abilities and was highly cooperative during the experiments.

Due to the location of the tumour, the patient was selected for the awake mapping multimodal protocol which assessed cognition, language and chess related functions. To this end, the protocol included a neuropsychological assessment, fMRI scan and ESM. AB met the criteria for the electrical stimulation

mapping as described in Section S1.4 (Sierpowska et al., 2018). The study protocol was accepted by the Ethical Committee of the University Hospital of Bellvitge (ref PR075/19) in accordance with the principles of the Declaration of Helsinki and the patient signed the informed consent for the participation in the study.

The conditions of our ethics approval do not permit public archiving of anonymised study data. Readers seeking access to the data should contact the lead author (AR-F). Access will be unconditionally granted to named individuals in accordance with ethical procedures governing the reuse of sensitive data. Scripts for stimuli presentation and data analysis are available at OSF (<https://osf.io/dw4xv/>). We report how we determined our sample size, all data exclusions, all inclusion/exclusion criteria, whether inclusion/exclusion criteria were established prior to data analysis, all manipulations, and all measures in the study. No part of the study procedures or analysis plans was pre-registered prior to the research being conducted.

## 2.2. Neuropsychological assessment

A baseline neuropsychological assessment protocol was administered pre-operative (25 days before), post-operative (one week after surgery) and follow-up session (four months after surgery). For more details on the neuropsychological assessment, see Sierpowska et al. (2018, 2022); and Section S1.1, and Table S1.

## 2.3. Behavioural chess evaluation

The patient performed the chess-based behavioural experiments twice (Fig. 1A): one week before the surgery (pre-operative session) and four months after the surgery (follow-up session). All sessions were performed under the supervision of a neuropsychologist from the University Hospital of Bellvitge. The same setup was used in both cases, maintaining task order. Instructions were given both orally and in written form. AB reported a full understanding of the tasks before performing them (for setup and analysis details see Section S1.2).

In the *black and white discrimination* task, the patient was asked if a chessman of a given colour was present in the chessboard with a 2-alternative forced choice (2AFC; yes/no) response. In the second task, *spatial discrimination*, a chessboard configuration with a red cross was presented. Using a 4AFC configuration, the participant was instructed to indicate which chessman was the closest to the red cross. In the *rule retrieval* task, the participant was asked to determine whether a movement in a reduced chessboard (4×4 board) was legal or not using a 2AFC (yes/no) response. The movement was illustrated by the starting position, coloured in green, and the ending position in red. The *checkmate* task assessed the patient's ability to simulate the outputs of his plays. A chessboard was presented, and the participant was supposed to determine if a certain player could checkmate in one or two movements with a 2AFC (yes/no) response. Finally, the *openings* task consisted of name retrieval of different chess openings. Similarly to spatial discrimination task, a chessboard scenario was presented with a 4AFC response.

The proportion of correct responses between sessions (pre-operative vs follow-up) was compared with a Fischer's exact

test, as the dependent variable was binary (correct/incorrect). Furthermore, a paired t-test was used to evaluate differences between pre-operative and follow-up reaction times (RT). The effect of session (pre-operative and follow-up), task and its interactions on performance were evaluated with a linear model and an analysis of variance on R version 4.2.2 (2022-10-31 ucrt) (RStudio).

## 2.4. fMRI chess evaluation

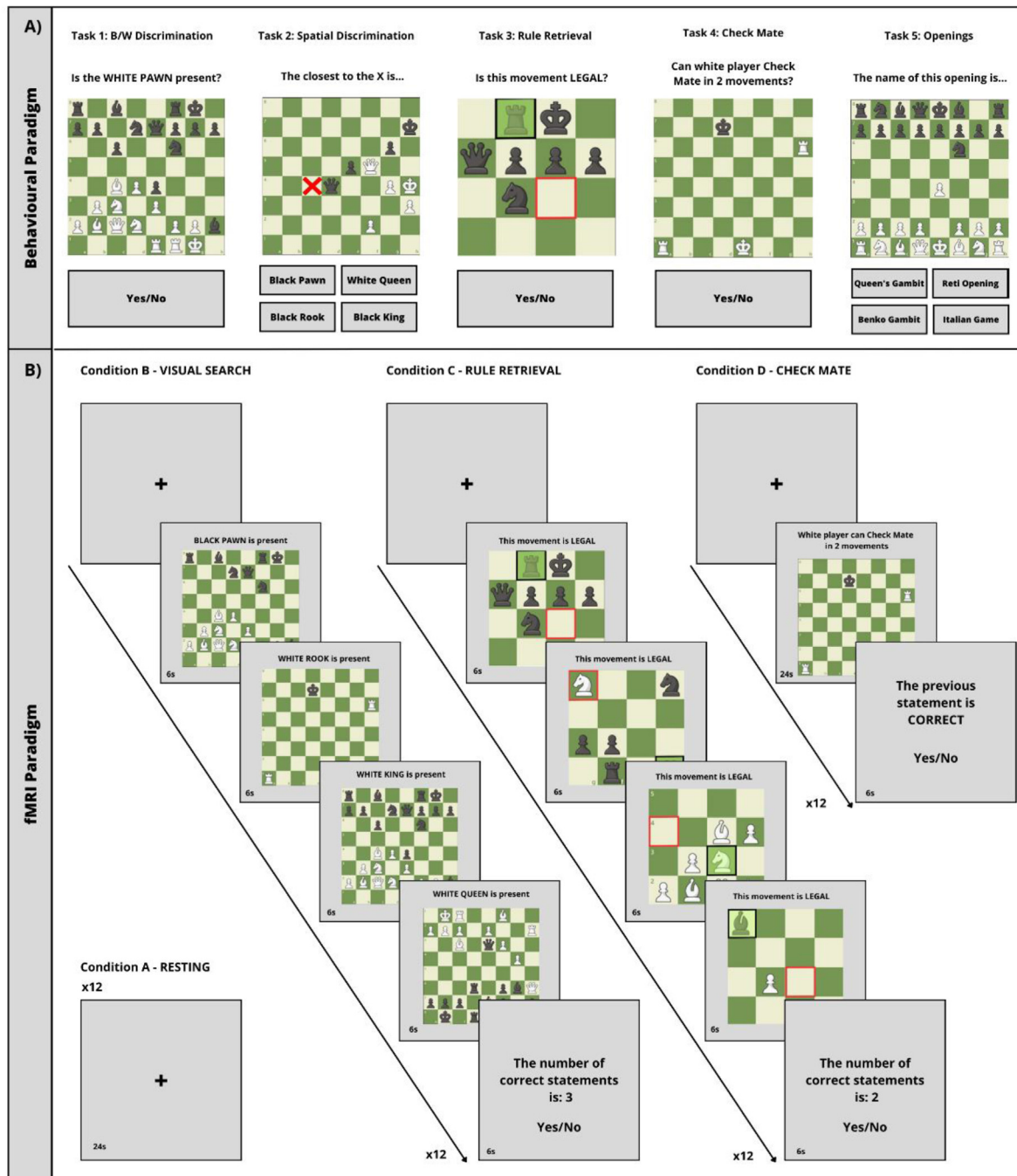
AB performed the fMRI evaluation protocol one week before surgery. T1-weighted images were acquired using chess tasks to measure BOLD signal changes (see Section S1.3).

The paradigm employed a block design with four conditions (Fig. 1B). In the *resting condition*, a fixation cross was presented on the screen for 24 sec. The *visual search condition* assessed the patient's object identification and discrimination abilities through the presentation of consecutive chess boards. Statements about the presence of a chessman were presented, and the participant counted the correct ones and responded (2-AFC, yes/no) to the accuracy of the presented number. Using the same procedure, in the *rule-retrieval condition*, the patient assessed the legality of chess movements. Lastly, the *checkmate condition* presented a single chessboard with a statement about a player's possibility to checkmate. The patient answered about its correctness using a 2-AFC (yes/no) response.

To identify the brain regions involved in chess cognitive processes, we conducted a whole brain analysis (see pre-processing details in Section S1.3.2). As described by Nichelli et al. (1994), the tasks followed a hierarchical structure in which a cognitive operation was added to the previous task. For example, both *rule-retrieval* and *checkmate* conditions required the *visual search* function, and the *checkmate* condition required the *rule-retrieval* function as well. Although all possible contrasts were computed, we included the four contrasts following this hierarchical structure (i.e., all *chess > resting*, *rule retrieval* and *checkmate > visual search*, *rule retrieval > visual search*, and *checkmate > rule retrieval*).

## 2.5. Electrical stimulation mapping (ESM)

AB underwent an awake brain surgery for tumour removal performed by the senior neurosurgeons A.G. and A.F.C. from the Department of Neurosurgery of the University Hospital of Bellvitge (see Section S1.4 for details). A left parietal craniotomy was performed, and the ESM was carried out using an ISIS Xpert 32 channels system (Inomed Medizintechnik GmbH) under asleep-awake-asleep surgery, following the methodology previously described by Ojemann and Mateer (1979) and Vakani and Nair (2019). Before the resection, the primary motor and sensory cortices were mapped (see Section S1.4). Subsequently, the patient was assessed with a comprehensive language battery and the cognitive chess tasks, screening for the intraoperative electrical stimulations in the awake brain surgery. The identified brain regions were reported by the neurosurgeons and then positioned on a brain template (Fig. 2A) to locate each ESM tag with its corresponding brain area for further visual analysis (for methods see Sierpowska et al., 2018, 2022). Subcortical mapping was performed on language, using the object naming task in



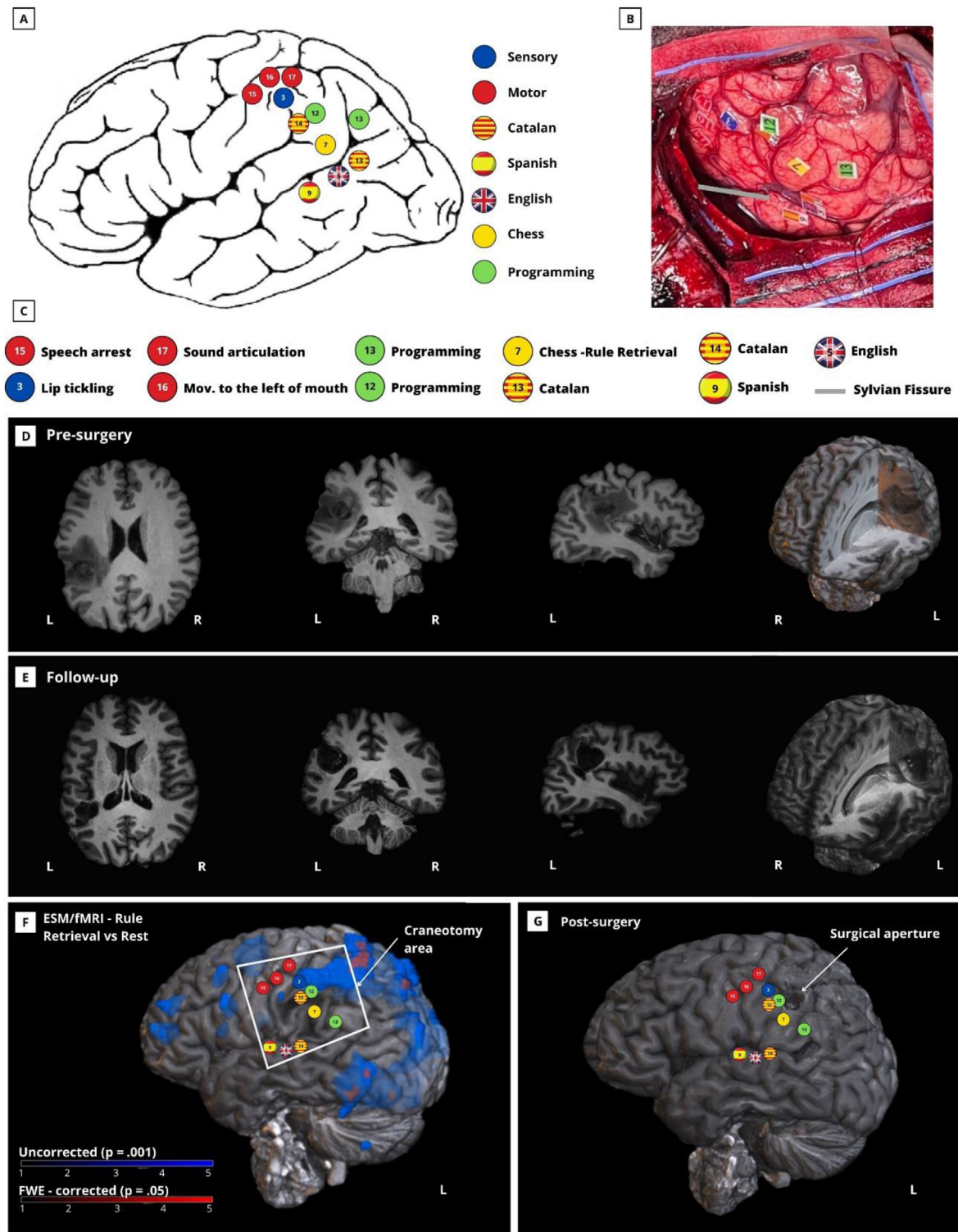
**Fig. 1 – A) Behavioural paradigms.** Task 1: Black and white discrimination, number of stimuli ( $n = 48$ ); task 2: Spatial discrimination ( $n = 16$ ); task 3: Rule-retrieval ( $n = 48$ ); task 4: Check mate ( $n = 20$ ); task 5: Openings ( $n = 16$ ). Tasks 1, 3 and 4 were also used during the ESM, although some trials were excluded from the procedure to guarantee the patient's ability to correctly solve the tasks. **B) fMRI block paradigm.** Condition A: resting, Condition B: Visual Search, Condition C: Rule-retrieval, Condition D: Checkmate.

Catalan due to the proximity of the eloquent point to the surgical aperture.

The behavioural tasks which had 2-AFC, and their RTs were below 7 sec, were selected as suitable for the ESM protocol. Therefore, black and white discrimination, rule-retrieval and check-mate were selected to be performed during the ESM (Fig. 1A). To ensure that elicited errors were caused by the ESM and not by patient difficulties, incorrect trials during both pre-operative

and training (in the operating room) were removed from the protocol. Each trial started with a spacebar press (done by researchers), after which a fixation cross and a stimulus were presented, respectively. The spacebar press was necessary to initiate each trial and to control the experimental flow. Visual stimuli were presented together with a tone to synchronize the stimulus presentation with the stimulation performed by the neurosurgeon. After the stimulus presentation, the patient had





**Fig. 2 – ESM results.** A) Brain template with functional tags identified during the ESM. B) ESM tags on the patient's brain. The Sylvian fissure has been indicated with a grey line. C) Legend of the tags. \*Programming task (green tags) is not included in this manuscript. D) Anatomical view of the lesion before the surgery. E) Anatomical view of the resection area in the follow up MR (3 months after surgery). F) 3D ESM-fMRI superposition with craniotomy area. G) Follow-up MR showing surgical aperture and ESM points.

a response window of either 5 (*black and white discrimination*) or 7 sec (*rule-retrieval and checkmate*). The response feedback (correct/incorrect/no response) was presented on a second monitor directly to the neurosurgeon.

### 3. Results

#### 3.1. Neuropsychological assessment

The patient was highly collaborative and showed a good understanding of the instructions for the neuropsychological assessment. At the pre-operative session (25 days before surgery), AB presented a minor impairment only in the long-term recall of the RAVLT, with an improvement in the recognition part. Additionally, the patient had mild difficulties (non-impaired scores) in the backward digits test and the TMT (part B). His scores for all other cognitive and language tasks were within the normal range (see [Section S3](#) for DTI reconstruction). A severe language impairment, including repetition, verbal comprehension, naming, verbal fluency, semantic knowledge, verbal memory and praxis was found during the post-operative assessment (one week after surgery). Not all tasks could be administered because the patient showed severe language and motor difficulties caused by an ongoing hemorrhagic complication. The patient showed a decline in the following tasks during the follow-up evaluation (four months after surgery): forward and backward digits, TMT B, and Token Test. Mild difficulties were observed in other tests, but his performance remained within the normal range for most measures. A comparison between the pre-, post-operative, and follow-up results can be found in [Table S1](#).

#### 3.2. Behavioural results

The behavioural performance was tested one week before and four months after the surgery. Due to the acute state of the patient, chess tasks could not be assessed post-operatively. No significant differences were found between the proportion of correct responses (pre – follow-up results: *black and white discrimination*: 48/48 – 47/48, *spatial discrimination*: 16/16 – 16/16, *rule-retrieval*: 43/48 – 45/48, *checkmate*: 16/20 – 17/20, *openings*: 16/16 – 16/16; Fisher's exact test: odds ratio = 1.2938,  $p = .7981$ ). An analysis of variance was performed using a linear model of RT as a function of session (pre or follow-up) and task, indicating the main effects of both session ( $F = 9.39$ ,  $df = 1$ ,  $p = .0024$ ), and task ( $F = 25.33$ ,  $df = 4$ ,  $p = 2.20 \times 10^{-16}$ ), and a trend in their interaction ( $F = 2.21$ ,  $df = 4$ ,  $p = .0680$ ). Although being a trend, an increased mean RT was observed (pre-operative RT = 2.85 sec, follow-up RT = 3.42 sec,  $t = -2.64$ ,  $p = .0089$ ), being especially significant in *spatial discrimination* [ $t(15) = -5.81$ ,  $p = 3.43 \times 10^{-5}$ ] and *openings* [ $t(15) = -2.50$ ,  $p = .0245$ ]. The effect was insignificant for the remaining tasks [*black and white discrimination*:  $t(47) = -1.42$ ,  $p = .1614$ ; *rule-retrieval*:  $t(85.57) = -.42$ ,  $p = .6725$ ; *checkmate*:  $t(19) = -1.08$ ,  $p = .2952$ ]. See [Fig. S1](#).

#### 3.3. fMRI results

Several brain regions were identified during the fMRI scan near the tumour location (see details in [Table S2](#)). The chess vs

resting condition ([Fig. 3A](#)) showed clusters of activation, for example, in the superior parietal lobes and precentral gyri. The *checkmate & rule-retrieval vs visual search* ([Fig. 3B](#)) revealed activation clusters in the left superior parietal lobe, the left precentral gyrus and the left supramarginal gyrus (SMG). Lastly, for the *rule-retrieval vs visual search* ([Fig. 3C](#)) significant activation clusters were found in both superior parietal lobes, SMG and the left post central gyrus.

#### 3.4. ESM results

The ESM was performed over all exposed cortical areas, and only functional points were labelled in [Fig. 2B](#), i.e., regions with no tags were identified as non-functional. Functionally, the ESM over the motor cortex (red tags in [Fig. 2A](#) and [B](#)) revealed 3 relevant points at the caudal part of motor circumvolution, in which the stimulation altered language production. These tags were related with different motor alterations, such as speech arrest (tag 15), both a right lateral movement of the mouth and speech arrest (tag 16), and sound articulation (tag 17). The ESM also revealed one somatosensory point, which produced tickling on the lips (blue tag in [Fig. 2A](#) and [B](#)).

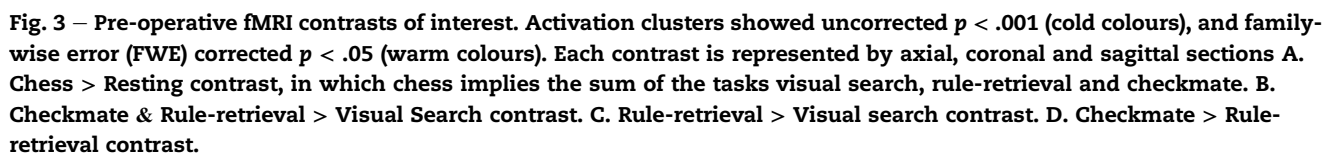
Regarding the Catalan, Spanish and English (indicated by flags in [Fig. 2A](#) and [B](#)) language naming tasks, two relevant points were detected within the angular gyrus (Catalan and English), one at the temporal auditory area (Spanish), and one at the vicinity of the left SMG (Catalan). Concurrently, one functional point was found during the *rule-retrieval* task (yellow tag in [Fig. 2A](#) and [B](#)) in the left SMG.

A macroscopic complete resection of the tumour involving the left parietal region was performed after obtaining no positive functional point at this level cortically ([Fig. 2E](#) and [G](#)). The closest positive eloquent point to the surgical aperture was for Catalan language naming task. Thus, Subcortical mapping was performed in Catalan naming, but no eloquent points were found.

### 4. Discussion

In the present study, we developed a multimodal fMRI-ESM protocol to maximally preserve chess playing ability in a patient diagnosed with a left parietal area brain tumour. The fMRI study identified functional regions proximal to the lesion. The ESM confirmed the role of the left supramarginal gyrus in chess performance, specifically in the rule-retrieval task. The patient preserved his chess performance after the surgery, which was evidenced through our experimental tasks and the self-reported maintenance of his professional chess ELO score (1950). Finally, the follow-up neuropsychological assessment revealed a mild impairment in attention, working memory, mental flexibility and verbal comprehension. The observed deficit in verbal comprehension, however, was most likely influenced by the executive load of the task.

To our knowledge, no previous studies have pointed to the left SMG as an area involved in chess performance previously. The left SMG has been linked to several functions, including language ([Bookheimer, 2002](#); [Davis et al, 2018](#); [Stoeckel et al, 2009](#)), memory ([Henson et al., 1999](#); [Dobbins et al, 2002](#); [Davidson et al., 2008](#); [Simons et al., 2008, 2010](#)), and



regarding rules, the left SMG has been associated with rule storage, switching and learning (Alahmadi, 2023; Mansouri et al., 2020; Reverberi et al., 2012). From another perspective, the left SMG has also been linked with serial coding of events, visuospatial processing and, even closely, with simulating the trajectory of a stimuli (Assmus et al., 2003; Cristoforetti et al.,



2022; Guidali et al., 2019; Papagno et al., 2017). Although our study could not determine which of the above-mentioned processes was altered during the ESM, our results indicate that, for our patient, the left SMG plays a key role in chess rule retrieval, suggesting that further research is required.

Although slight impairments in the neuropsychological assessment (mainly in executive functions), our behavioural results indicate that chess performance, as well as other domains involved in chess such as memory and visuospatial/visuoconstructive abilities, were preserved after surgery. Importantly, a significant increase in the RT in two out of five behavioural tasks was observed, suggesting that this increment only occurred in the 4AFC tasks. Possibly, the slight neuropsychological impairment in executive functions could be reflected in the processing of the possible answers.

Despite certain limitations, the current multimodal protocol facilitated identification and preservation of the functional brain structures involved in chess performance during the surgery, providing a useful experimental setup for future interventions. In terms of limitations, the generalizability is compromised by two factors. First, results from a case study should be interpreted with caution since the obtained data are based on a single subject. Second, chess players brain's architecture and activity patterns strongly depend on expertise (Amidzic et al., 2001; Hänggi et al., 2014), therefore, the findings might not be equally applicable to other chess players.

The neuroimaging design introduces further limitations. For instance, fMRI does not directly measure neuronal activity, rather it captures physiological changes associated to neuronal activity. Therefore, large sulci or fissures can lead to a partial volume effect (Wüstenberg et al., 2003), and pathological tissues may provoke modifications in neurovascular coupling, especially in the vicinity of gliomas and meningiomas (Krings et al., 2001). Furthermore, it is important to consider that the ESM, despite being the intraoperatively gold standard in tumour resections, is limited by the intraoperative setting such as time constraints and anatomical restrictions (Ritaccio, Brunner, & Schalk, 2018). Thus, not every single function can be tested without compromising the patient's safety.

Finally, the experimental design poses additional constraints. For example, the fMRI tasks included a working memory component, and the patient needed to read some instructions during the scan, recruiting language processing regions (Murphy et al., 2019). Thus, regions that were unrelated to the main task showed activation clusters, potentially biasing the interpretation of the results. We believe that future studies could benefit from adding an assessment of additional tasks for executive functions. Many of these processes are inherent in chess problem-solving tasks, but time constraints in the ESM do not allow us to tackle every single cognitive function. Also, we did not control for learning effects despite the presentation of the same stimuli during the pre-, intra-operative, and follow-up sessions. Lastly, the experimental design grounds the cognitive subtraction on the assumption of pure insertion. To circumvent this issue and analyse the interaction effects among cognitive operations, a task implying rule-retrieval but not visual search would be required. Probably, the application of a factorial experimental design would benefit future studies (Friston, Price, et al., 1996).

## 5. Conclusion

In conclusion, we developed a novel ESM-fMRI protocol to preserve chess performance in a patient undergoing a tumour resection surgery in the left parietal area. The multimodal fMRI-ESM protocol targeted the proximal regions to the lesion. Aside from the preservation of cognitive functions, we found a positive eloquent area in the left SMG revealed by the ESM during the rule-retrieval task. This finding allowed the preservation of chess performance after surgery, fulfilling the patient's wish and successfully preserving his quality of life.

## Funding

This work was supported by the Investigo program - Funded by the European Union, Next Generation EU [Ref: BDNS664047]. The Cognition and Brain Plasticity Group is funded by Generalitat de Catalunya 2021SGR01099.

## CRediT authorship contribution statement

**Victor Cepero-Escribano:** Writing – original draft, Visualization, Software, Methodology, Investigation, Formal analysis, Data curation, Conceptualization. **Xim Cerda-Company:** Writing – review & editing, Validation, Software, Methodology, Investigation, Conceptualization. **Patricia León-Cabrera:** Software, Resources, Formal analysis. **Guillem Olivé:** Visualization, Software, Resources, Formal analysis. **David Cucurell:** Software, Resources, Methodology, Investigation. **Anna Gasaróque:** Writing – review & editing, Resources, Project administration, Investigation, Formal analysis, Data curation. **Andreu Gabarrós:** Project administration, Methodology, Investigation, Conceptualization. **Pablo Naval-Baudin:** Resources, Methodology. **Àngels Camins:** Resources, Methodology. **Immaculada Rico:** Resources, Methodology, Investigation. **Alejandro Fernández-Coello:** Methodology, Investigation. **Joanna Sierpowska:** Writing – review & editing, Resources, Methodology. **Antoni Rodríguez-Fornells:** Writing – review & editing, Validation, Supervision, Resources, Project administration, Conceptualization.

## Declaration of competing interest

None.

## Acknowledgements

The authors want to acknowledge patient AB for his cooperation.

## Supplementary data

Supplementary data to this article can be found online at <https://doi.org/10.1016/j.cortex.2024.05.022>.



## REFERENCES

- Alahmadi, A. A. S. (2023). Functional connectivity of sub-cortical brain regions: Disparities and similarities. *NeuroReport*, 34(4), 214–219. <https://doi.org/10.1097/WNR.0000000000001881>
- Amidzic, O., Riehle, H., Fehr, T., Wienbruch, C., & Elbert, T. (2001). Pattern of focal gamma-bursts in chess players. *Nature*, 412(6847), 603. <https://www.semanticscholar.org/paper/d0a9f134aa18902e16dd5a71985c49e5d924d798>
- Assmus, A., Marshall, J. C., Ritzl, A., Noth, J., Zilles, K., & Fink, G. R. (2003). Left inferior parietal cortex integrates time and space during collision judgments. *NeuroImage*, 20(Suppl. 1), S82–S88. <https://doi.org/10.1016/J.NEUROIMAGE.2003.09.025>
- Berryhill, M. E., Phuong, L., Picasso, L., Cabeza, R., & Olson, I. R. (2007). Parietal lobe and episodic memory: Bilateral damage causes impaired free recall of autobiographical memory. *Journal of Neuroscience*, 27(52), 14415–14423. <https://doi.org/10.1523/JNEUROSCI.4163-07.2007>
- Bookheimer, S. (2002). Functional MRI of language: New approaches to understanding the cortical organization of semantic processing. *Annual Review of Neuroscience*, 25, 151–188. <https://doi.org/10.1146/ANNUREV.NEURO.25.112701.142946>
- Bratko, I., Hristova, D., & Guid, M. (2016). Search versus knowledge in human problem solving: A case study in chess. In L. Magnani, & C. Casadio (Eds.), *Model-Based Reasoning in Science and Technology* (pp. 569–583). Springer International Publishing.
- Campitelli, G., Gobet, F., & Parker, A. (2005). *Structure and stimulus familiarity: A study of memory in chess-players with functional magnetic resonance imaging. The Spanish*.
- Cristoforetti, G., Majerus, S., Sahan, M. I., van Dijk, J. P., & Fias, W. (2022). Neural patterns in parietal cortex and hippocampus distinguish retrieval of start versus end positions in working memory. *Journal of Cognitive Neuroscience*, 34(7), 1230–1245. [https://doi.org/10.1162/JOCN\\_A\\_01860](https://doi.org/10.1162/JOCN_A_01860)
- Critchley, M. (1953). The parietal lobes. In *The parietal lobes*. Williams and Wilkins.
- Davidson, P. S. R., Anaki, D., Ciaramelli, E., Cohn, M., Kim, A. S. N., Murphy, K. J., ... Levine, B. (2008). Does lateral parietal cortex support episodic memory?: Evidence from focal lesion patients. *Neuropsychologia*, 46(7), 1743–1755. <https://doi.org/10.1016/J.NEUROPSYCHOLOGIA.2008.01.011>
- Davis, S. W., Wing, E. A., & Cabeza, R. (2018). Contributions of the ventral parietal cortex to declarative memory. *Handbook of Clinical Neurology*, 151, 525–553. <https://doi.org/10.1016/B978-0-444-63622-5.00027-9>
- Dehaene, S., Piazza, M., Pinel, P., & Cohen, L. (2003). Three parietal circuits for number processing. *Cognitive Neuropsychology*, 20(3), 487–506. <https://doi.org/10.1080/02643290244000239>
- Dobbins, I. G., Foley, H., Schacter, D. L., & Wagner, A. D. (2002). Executive control during episodic retrieval: Multiple prefrontal processes subserve source memory. *Neuron*, 35(5), 989–996. [https://doi.org/10.1016/S0896-6273\(02\)00858-9](https://doi.org/10.1016/S0896-6273(02)00858-9)
- Duan, X., He, S., Liao, W., Liang, D., Qiu, L., Wei, L., Li, Y., Liu, C., Gong, Q., & Chen, H. (2012). Reduced caudate volume and enhanced striatal-DMN integration in chess experts. *NeuroImage*, 60(2), 1280–1286. <https://doi.org/10.1016/J.NEUROIMAGE.2012.01.047>
- Duan, X., Liao, W., Liang, D., Qiu, L., Gao, Q., Liu, C., ... Chen, H. (2012). Large-scale brain networks in board game experts: insights from a domain-related task and task-free resting state. *PLoS One*, 7(3), Article e32532. <https://doi.org/10.1371/journal.pone.0032532>
- Duffau, H. (2015). Stimulation mapping of white matter tracts to study brain functional connectivity. *Nature Reviews Neurology*, 11(5), 255–265. <https://doi.org/10.1038/nrneurol.2015.51>
- Friston, K. J., Price, C. J., Fletcher, P., Moore, C., Frackowiak, R. S. J., & Dolan, R. J. (1996). The trouble with cognitive subtraction. *NeuroImage*, 4(2), 97–104. <https://doi.org/10.1006/NIMG.1996.0033>
- Gasa-Roqué, A., Rofes, A., Simó, M., Juncadella, M., Rico Pons, I., Camins, A., Gabarrós, A., Rodríguez-Fornells, A., & Sierpowska, J. (2023). Understanding language and cognition after brain surgery - Tumour grade, fine-grained assessment tools and, most of all, individualized approach. *Journal of Neuropsychology*. <https://doi.org/10.1111/JNP.12343>
- Gobet, F., & Simon, H. A. (1996). Recall of random and distorted chess positions: Implications for the theory of expertise. *Memory & Cognition*, 24(4), 493–503. <https://doi.org/10.3758/BF03200937>
- Guidali, G., Pisoni, A., Bolognini, N., & Papagno, C. (2019). Keeping order in the brain: The supramarginal gyrus and serial order in short-term memory. *Cortex; a Journal Devoted to the Study of the Nervous System and Behavior*, 119, 89–99. <https://doi.org/10.1016/J.CORTEX.2019.04.009>
- Hänggi, J., Brüttsch, K., Siegel, A. M., & Jäncke, L. (2014). The architecture of the chess players' brain. *Neuropsychologia*, 62(1), 152–162. <https://doi.org/10.1016/j.neuropsychologia.2014.07.019>
- Henson, R. N. A., Rugg, M. D., Shallice, T., Josephs, O., & Dolan, R. J. (1999). Recollection and familiarity in recognition memory: An event-related functional magnetic resonance imaging study. *The Journal of Neuroscience: The Official Journal of the Society for Neuroscience*, 19(10), 3962–3972. <https://doi.org/10.1523/JNEUROSCI.19-10-03962.1999>
- Husain, M., & Nachev, P. (2007). Space and the parietal cortex. *Trends in Cognitive Sciences*, 11(1), 30–36. <https://doi.org/10.1016/J.TICS.2006.10.011>
- Johns, P. (2014). Functional neuroanatomy. *Clinical Neuroscience*, 27–47. <https://doi.org/10.1016/B978-0-443-10321-6.00003-5>
- Kirkdale, R., Krell, J., O'Hanlon Brown, C., Tuthill, M., & Waxman, J. (2010). The cost of a QALY. *QJM: Monthly Journal of the Association of Physicians*, 103(9), 715–720. <https://doi.org/10.1093/QJMED/HCQ081>
- Krawczyk, D. C., Boggan, A. L., McClelland, M. M., & Bartlett, J. C. (2011). The neural organization of perception in chess experts. *Neuroscience Letters*, 499(2), 64–69. <https://doi.org/10.1016/j.neulet.2011.05.033>
- Krings, T., Schreckenberger, M., Rohde, V., Foltys, H., Spetzger, U., Sabri, O., Reinges, M. H. T., Kemeny, S., Meyer, P. T., Möller-Hartmann, W., Korinth, M., Gilsbach, J. M., Buell, U., & Thron, A. (2001). Metabolic and electrophysiological validation of functional MRI. *Journal of Neurology, Neurosurgery & Psychiatry*, 71(6), 762–771. <https://doi.org/10.1136/JNPN.71.6.762>
- Louis, D. N., Perry, A., Wesseling, P., Brat, D. J., Cree, I. A., Figarella-Branger, D., Hawkins, C., Ng, H. K., Pfister, S. M., Reifenger, G., Soffietti, R., Von Deimling, A., & Ellison, D. W. (2021). The 2021 WHO Classification of Tumors of the Central Nervous System: A summary. *Neuro-Oncology*, 23(8), 1231–1251. <https://doi.org/10.1093/NEUONC/NOAB106>
- Malcolm, G. L., & Barton, J. J. S. (2007). "Sequence agnosia" in Balint's syndrome: Defects in visuotemporal processing after bilateral parietal damage. *Journal of Cognitive Neuroscience*, 19(1), 102–108. <https://doi.org/10.1162/JOCN.2007.19.1.102>
- Malouin, F., Richards, C. L., Jackson, P. L., Dumas, F., & Doyon, J. (2003). Brain activations during motor imagery of locomotor-related tasks: a PET study. *Human Brain Mapping*, 19(1), 47–62. <https://doi.org/10.1002/HBM.10103>
- Mansouri, F. A., Freedman, D. J., & Buckley, M. J. (2020). Emergence of abstract rules in the primate brain. *Nature Reviews Neuroscience*, 21(11), 595–610. <https://doi.org/10.1038/s41583-020-0364-5>
- Mesulam, M. M. (1999). Spatial attention and neglect: Parietal, frontal and cingulate contributions to the mental

- representation and attentional targeting of salient extrapersonal events. *Philosophical Transactions of the Royal Society of London. Series B: Biological Sciences*, 354(1387), 1325–1346. <https://doi.org/10.1098/RSTB.1999.0482>
- Murphy, K. A., Jogia, J., & Talcott, J. B. (2019). On the neural basis of word reading: A meta-analysis of fMRI evidence using activation likelihood estimation. *Journal of Neurolinguistics*, 49, 71–83. <https://doi.org/10.1016/J.JNEUROLING.2018.08.005>
- Nichelli, P., Grafman, J., Pietrini, P., Alway, D., Carton, J. C., & Miletich, R. (1994). Brain activity in chess playing. *Nature*, 369, 191. <https://doi.org/10.1038/369191A0>
- Nicol, C., Ownsworth, T., Cubis, L., Nguyen, W., Foote, M., & Pinkham, M. B. (2019). Subjective cognitive functioning and associations with psychological distress in adult brain tumour survivors. *Journal of Cancer Survivorship: Research and Practice*, 13(5), 653–662. <https://doi.org/10.1007/S11764-019-00784-8>
- Ojemann, G., & Mateer, C. (1979). Human language cortex: Localization of memory, syntax, and sequential motor-phoneme identification systems. *Science (New York, N.Y.)*, 205(4413), 1401–1403. <https://doi.org/10.1126/SCIENCE.472757>
- Ojemann, G., Ojemann, J., Lettich, E., & Berger, M. (2008). Cortical language localization in left, dominant hemisphere. An electrical stimulation mapping investigation in 117 patients. 1989. *Journal of Neurosurgery*, 108(2), 411–421. <https://doi.org/10.3171/JNS/2008/108/2/0411>
- Papagno, C., Comi, A., Riva, M., Bizzi, A., Vernice, M., Casarotti, A., Fava, E., & Bello, L. (2017). Mapping the brain network of the phonological loop. *Human Brain Mapping*, 38(6), 3011–3024. <https://doi.org/10.1002/HBM.23569>
- Penfield, W., & Roberts, L. (1959). *Speech and brain mechanisms*. In *Speech and brain mechanisms*. Princeton University Press.
- Phillips, K. A., Fadul, C. E., & Schiff, D. (2018). Neurologic and Medical Management of Brain Tumors. *Neurologic Clinics*, 36(3), 449–466. <https://doi.org/10.1016/j.ncl.2018.04.004>
- Reverberi, C., Gorgen, K., & Haynes, J. D. (2012). Compositionality of rule representations in human prefrontal cortex. *Cerebral Cortex*, 22(6), 1237–1246. <https://doi.org/10.1093/CERCOR/BHR200>
- Ritaccio, A. L., Brunner, P., & Schalk, G. (2018). ELECTRICAL STIMULATION MAPPING of the Brain: Basic Principles and Emerging Alternatives. *Journal of Clinical Neurophysiology: Official Publication of the American Electroencephalographic Society*, 35(2), 86. <https://doi.org/10.1097/WNP.0000000000000440>
- Rofes, A., Spena, G., Talacchi, A., Santini, B., Miozzo, A., & Miceli, G. (2017). Mapping nouns and finite verbs in left hemisphere tumors: A direct electrical stimulation study. *Neurocase*, 23(2), 105–113. <https://doi.org/10.1080/13554794.2017.1307418>
- Satoer, D., Visch-Brink, E., Smits, M., Kloet, A., Looman, C., Dirven, C., & Vincent, A. (2014). Long-term evaluation of cognition after glioma surgery in eloquent areas. *Journal of Neuro-Oncology*, 116(1), 153–160. <https://doi.org/10.1007/S11060-013-1275-3>
- Schiff, D., Lee, E. Q., Nayak, L., Norden, A. D., Reardon, D. A., & Wen, P. Y. (2015). Medical management of brain tumors and the sequelae of treatment. *Neuro-Oncology*, 17(4), 488–504. <https://doi.org/10.1093/NEUONC/NOU304>
- Sierpowska, J., Fernandez-Coello, A., Gomez-Andres, A., Camins, A., Castañer, S., Juncadella, M., ... Rodríguez-Fornells, A. (2018). Involvement of the middle frontal gyrus in language switching as revealed by electrical stimulation mapping and functional magnetic resonance imaging in bilingual brain tumor patients. *Cortex*, 99, 78–92. <https://doi.org/10.1016/J.CORTEX.2017.10.017>
- Sierpowska, J., Rofes, A., Dahlslätt, K., Mandonnet, E., Ter Laan, M., Polczyńska, M., ... Piai, V. (2022). The Aftercare Survey: Assessment and intervention practices after brain tumor surgery in Europe. *Neuro-Oncology Practice*, 9(4), 328–337. <https://doi.org/10.1093/NOP/NPAC029>
- Simons, J. S., Peers, P. V., Hwang, D. Y., Ally, B. A., Fletcher, P. C., & Budson, A. E. (2008). Is the parietal lobe necessary for recollection in humans? *Neuropsychologia*, 46(4), 1185–1191. <https://doi.org/10.1016/J.NEUROPSYCHOLOGIA.2007.07.024>
- Simons, J. S., Peers, P. V., Mazuz, Y. S., Berryhill, M. E., & Olson, I. R. (2010). Dissociation between memory accuracy and memory confidence following bilateral parietal lesions. *Cerebral Cortex*, 20(2), 479–485. <https://doi.org/10.1093/CERCOR/BHP116>
- Stoeckel, C., Gough, P. M., Watkins, K. E., & Devlin, J. T. (2009). Supramarginal gyrus involvement in visual word recognition. *Cortex*, 45(9), 1091–1096. <https://doi.org/10.1016/J.CORTEX.2008.12.004>
- Vakani, R., & Nair, D. R. (2019). Electrooculography and functional mapping. *Handbook of Clinical Neurology*, 160, 313–327. <https://doi.org/10.1016/B978-0-444-64032-1.00020-5>
- Wüstenberg, T., Jordan, K., Giesel, F. L., & Villringer, A. (2003). Physiologische und technische Grenzen der funktionellen Magnetresonanztomographie und die damit verbundenen Konsequenzen für die klinische Anwendung. *Der Radiologe*, 43(7), 552–557. <https://doi.org/10.1007/s00117-003-0917-4>