

SHORT COMMUNICATION

SWINE AS AN EXPERIMENTAL MODEL IN DENTISTRY: A PROPOSAL OF SURGICAL APPROACH

López J ¹, Chimenos E ¹, Muñoz J ¹, Castañeda P ¹, Gimeno A ², Fuentes P ², and Manzanares C ³

1 Section of Oral Medicine. Faculty of Dentistry, University of Barcelona.; 2 Animal facilities Service. Campus of Bellvitge, University of Barcelona; 3 Section of Anatomy Faculty of Dentistry, University of Barcelona.

Abstract

Swine is widely used as an experimental model in several areas of medicine based on its anatomical and physiological similarities to humans. In this report, we describe an external surgical approach on the mandible of the swine as a suitable experimental model in dentistry. Several biomaterials were implanted by using this technique in order to evaluate the degree of bone regeneration as well as the suitable sites to accomplish perforation.

Key words Swine; animal model; surgical technique: experimental dentistry

Introduction

Swine is frequently used as an animal model in experimental studies, including heart implants (1,2) and abdominal surgery (3,4) among other fields (5). Similarly, it also constitutes a suitable experimental model in dentistry, particularly in implantological and restorative surgery (6-8), but also in biomaterials (9-11), periodontal regeneration (12) and restorative dentistry (13).

The extent of anatomical and physiological similarities between pigs and humans make swine convenient for modeling human interventions (5,14). In addition, the *mini pig* has specific features that enhance its applicability for investigation when compared to the fattening breeds: it is easier to handle in the operating room and during the postoperative period, it has a lower fat index and it has been well characterized. This facilitates data validation and reproducibility (15-17). Additional benefits are: raising pigs is relatively easy; and their organs are similar in size and physiology to humans. In this report, we have used a hybrid commercial

pig model. Animals were of standard size, very docile and their handling was relatively easy. Finally, its similarity to humans from a physiopathological point of view provided additional support for its use as an experimental model (18-20).

The objectives of this study were the evaluation of the usefulness of the pig as an experimental model in a surgical technique to implant bone regeneration material, as well as a description of an approaching protocol to access the mandible of the animal.

Material and Methods

The experimental and animal care details of this study were reviewed and approved by the CEEA (Ethical Committee of animal experimentation) of the Universitat de Barcelona (Spain). Nine three-month old male hybrid animals were used to perform this study. Their weight ranged 20-25 kg. The experimental procedure is outlined below: the animals underwent experimental surgery (see below). After the surgery, the animals were transferred to the animal facilities at the Bellvitge Campus and maintained under standard conditions (feeding, light/dark cycles, etc.) for two months. During this period, postoperative checks and follow-up care were performed. Two months later the animals were sacrificed with an overdose of anesthesia, and experimental data collected.

Surgery: The surgical procedures were done in the operating room. Ten perforations of 4.2 mm diameter and 8 mm depth were performed in all the animals (drill SDQ4[®], Triron Biomedical, Karlsruhe, Germany) in a randomly chosen

hemimandible using an external approach technique. The different trephinations were filled with the materials included in the study, leaving two of them unfilled as controls. The experimental materials included: 1) Platelet-rich plasma from the blood of the own animal, at a concentration of < 500.000 platelets/ml; 2) PRP with a concentration of > 500.000 platelets/ml; 3) Bone marrow; 4) Tricalcium- β -Phosphate. After the surgery, the suture was performed in layers, using double zero silk and a cylindrical needle. Intramuscular Terramicine 100[®] (25mg/kg) (Pfizer) was injected as prophylactic treatment.

Results and Discussion

All the animals used in the study received the analgesic and antibiotic protocols established by the rules and regulations of the animal services in which the animals were maintained. All of them ate normally between 1 and 3 hours after surgery and gained weight adequately. One of them died a few hours later as a result of postoperative complications. Another presented a small abscess, which was debrided (Fig. 1).

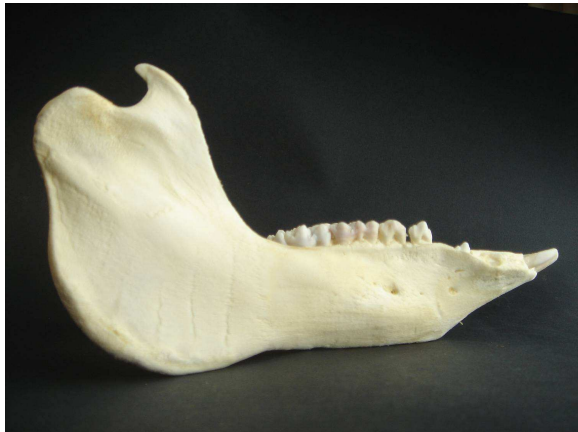

Figure 1. Lateral view of the mandible of a five-month old pig

None of them exhibited cheloids, hypertrophic scars or dehiscences related to the wound. **Anatomical considerations:** The mandible was chosen as the most accessible and easy to use bone for the implantation of exogenous materials for their study. Due to the anatomical differences between swine and human mandible, some difficulties arose: the mandible body of the pig is elongated compared to humans (Fig. 1). This means a larger working surface, but also presents unique features that must be taken into consideration, such as the existence of two anatomical orifices ("mentonian") in the anterior half part of the mandible, separated between 2 and 3 cm depending on the age of the animal. On the other hand, part of the bone thickness is taken

up by the dental germs in an age-dependent fashion, which results in reduced available space for material implantation. The coincidence of these anatomical structures with the extension of the working area limits the interpretation of the results. For this reason, young animals (approximately 3 months old) are recommended for experimental studies: at this age, they present a more distended space between the dental germs and the inferior rim of the mandible, as well as a longer distance between the anatomical orifices (Fig. 2). Depending on the number of orifices to implant

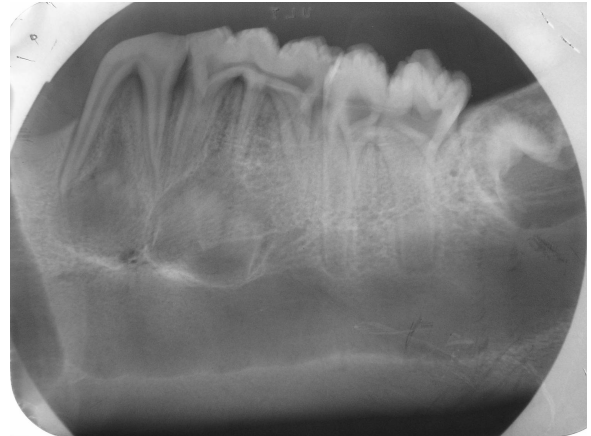

Figure 2. Radiography of the mandible of a five-month old pig.

the materials, it may be better to use the space between the most anterior fibers of the masseter muscle and the most posterior fibers of the anatomic orifices.

Surgical technique: The specific approaching technique employed in this study was chosen in accordance with that described by Fuerst *et al.* (19) to limit post-surgery complications. Using this technique, a perpendicular line passing through the pupilar middle line to the base of the mandible was drawn after anesthetizing the animal. Perpendicular to this line, another one is drawn just below the commissural of the lower lip. Then, the incision can be performed. This procedure, performed by peeling off by layers or planes, preserves the anterior rim of the masseter, avoiding lesions and improving postoperative edema, facilitating feeding a few hours later (Fig. 3).

We performed 10 trephinations in each animal. To systematize this process and the subsequent filling of the trephinations, we prepared identical templates made of self-polymerizable resin (Trim[®]) (Fig. 4).

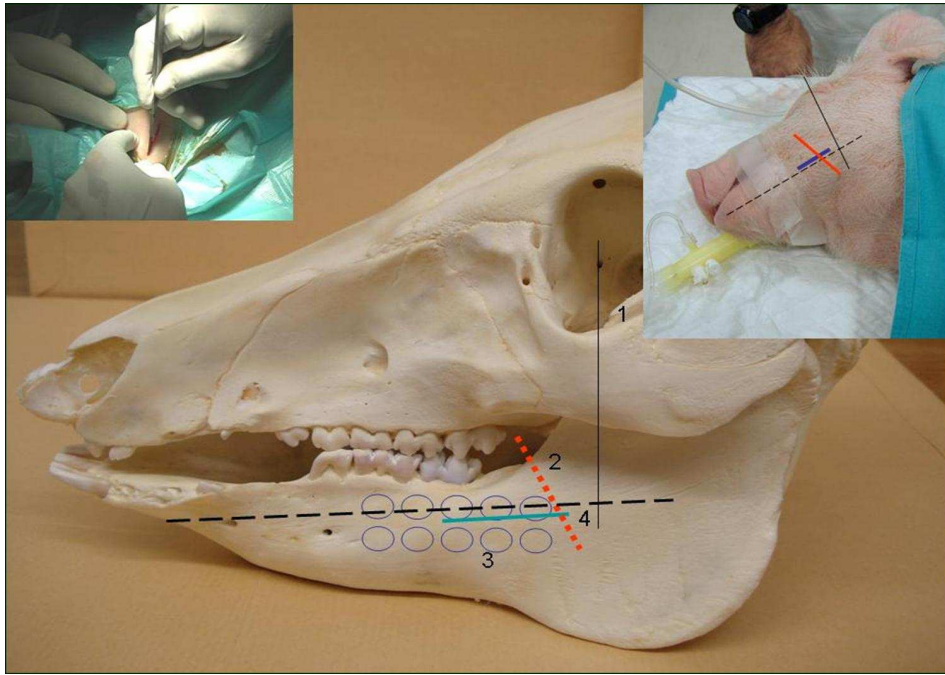


Figure 3: 1: Pupilar middle line; 2: anterior insertion of the masseter muscle; 3: theoretical perforations to be performed in the study; 4: approaching incision. This incision allows peeling off the masseter without damaging it, therefore improving post-surgery. Insert, a simulation of the head of the animal and the incision on the animal number 2 of the study is showcased.

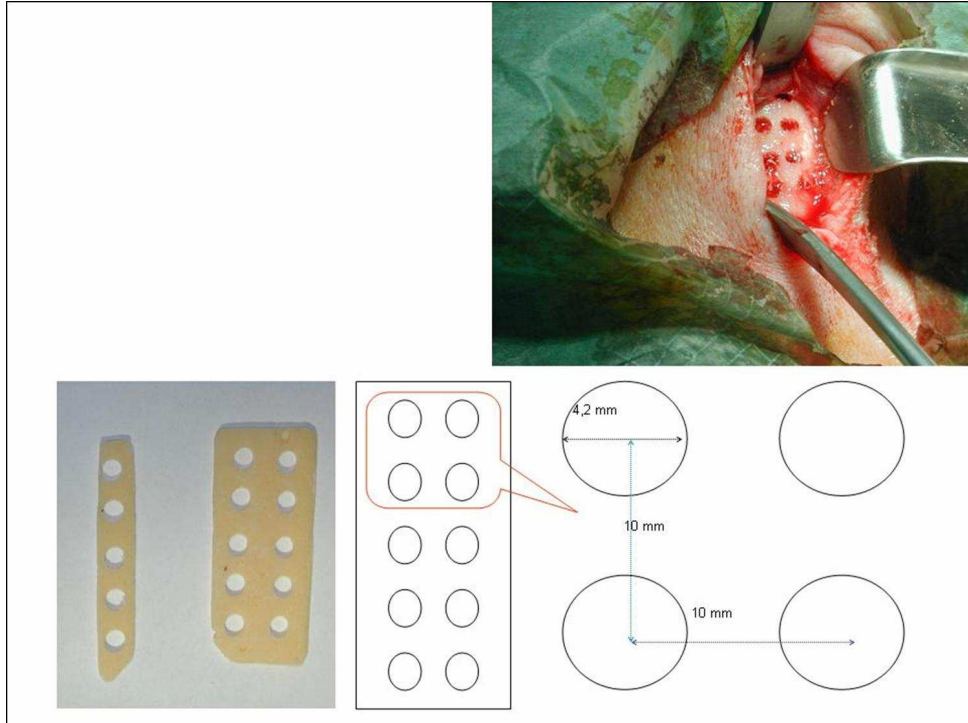


Figure 4. Some aspects of the pattern used to do the trephinations. They are made of autopolymerizable resin (Trim®) which allows the systematization of bone defects. Insert, imaging of one of the perforations.

PRP was routinely obtained by femoral bleeding, and no incidents were reported (Fig. 5). Bone marrow was collected through sternum trephination (Fig. 6). Some complications appeared in pig number 4, being necessary to

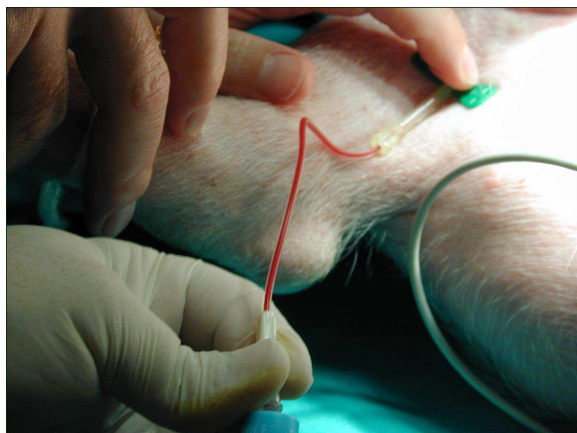

Figure 5. PRP, obtained via the femoral artery (located previously by the attending veterinarian), is used and collected in 5 ml citrate tubes (4 tubes/ animal).

make three punctures. However, the animal did not show additional post-surgery complications. In conclusion the hybrid pig constitutes a convenient experimental model in dentistry, with very few limitations for the applications herein assayed. Moreover, the external surgical approach technique turned out to be useful to do perforations in the mandible in order to place the regeneration material.

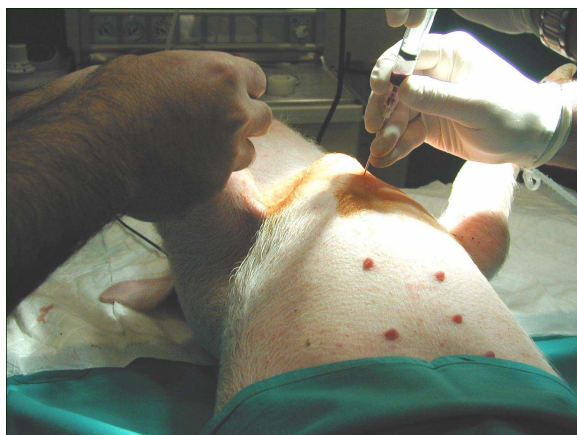

Figure 6. Bone marrow is obtained by sternum puncture, which is a less traumatic procedure than puncture of the crista iliaca. 3 to 5 ml of bone marrow are obtained per puncture. Only one of the experimental subjects presented some difficulty for collection of the bone marrow; 3 punctures were required in this case.

References

1.- **Oi K, Davies WR, Tazelaar HD, Bailey KR, Federspiel MJ, Russell SJ, McGregor CG.** Ex vivo hypothermic recirculatory adenoviral gene

transfer to the transplanted pig heart. *J Gene Med* 2006; 8:795-803.

2.- **Adams DH, Chen RH, Kadner A.** Cardiac xenotransplantation: clinical experience and future direction. *Ann Thorac Surg* 2000; 70:320-6.

3.- **Soper NJ, Barteau JA, Clayman RV, Becich MJ.** Safety and efficacy of laparoscopic cholecystectomy using monopolar electrocautery in the porcine model. *Surg Laparosc Endosc* 1991; 1:17-22.

4.- **Santa-Cruz RW, Auge BK, Lallas CD, Preminger GM, Polascik TJ.** Use of bipolar laparoscopic forceps to occlude and transect the retroperitoneal vasculature: a porcine model. *J Endourol* 2003; 17:181-5.

5.- **Almond GW.** Research application using pigs. *Vet Clin North Am Food Animal Practice* 1996; 12:707-16.

6.- **Natiella JR.** The use of animals models in research on dental implants. *Int J Oral implantol* 1988; 5:61-4.

7.- **Ersoy AE, Ellialti DB, Dogan N.** Implant-supported prosthetic applications upon development of children and adolescents: a pilot study in pigs. *Implant Dent* 2006; 15:412-9.

8.- **Zimmerman CE, Thurmüller P, Troulis MJ, Perrot DH, Rahn B, Kaban LB.** Histology of the porcine mandibular distraction wound. *Int J Oral Maxillofac Surg* 2005; 34:411-19.

9.- **Craig RG, Kamer AR, Kallur SP, Inoue M, Tarnow DP.** Effects of periodontal cell grafts and enamel matrix proteins on the implant-connective tissue interface: a pilot study in the minipig. *J Oral Implantol* 2006; 32:228-36.

10.- **Clokie CM, Bell RC.** Recombinant human transforming growth factor beta-1 and its effects on osseointegration. *J Craniofac Surg* 2003; 14:268-77.

11.- **Klongnoi B, Rupprecht S, Kessler P, Zimmermann R, Thorwarth M, Pongsiri S, Neukam FW, Wiltfang J, Schlegel KA.** Lack of beneficial effects of platelet-rich plasma on sinus augmentation using a fluorohydroxyapatite or autogenous bone: an explorative study. *J Clin Periodontol* 2006; 33:500-9.

12.- **Nikolopoulos S, Peteinaki E, Castanas E.** Immunologic effects of emdogain in humans: one-year results. *Int J Periodontics Restorative Dent* 2002; 22:269-77.

13.- **Bivin WS, Mc Clure RC.** Deciduous tooth chronology in the mandible of the domestic pig. *J Dent Res* 1976; 55:591-7.

14.-**San Román F, Calvo I, Pérez C, Castejón A, Vera V, Thums U.** *Rev Esp Odontoestomatológica de Implantes* 2003; 11:14-22.

15.- **Weaver ME, Sorenson FM, JumpEB.** The miniature pig as an experimental animal in dental research. *Arch Oral Biol* 1962; 7:17-23.

16.- **Vodicka P, Smetana K Jr, Dvorankova B, Emerick T, Xu YZ, Ourednik J, Ourednik V, Motlik J.** The miniature pig as an animal model in biomedical research. *Ann N Y Acad Sci* 2005; 1049: 161-71.

17.- **Tanaka H, Kobayashi E.** Education and research using experimental pigs in a medical school. *J Artif Organs* 2006; 9:136-43.

18.- **San Roman F, Thams U, Binder Do Prado A, Collados J, San Roman F.** Estudio de la influencia del CALBENIUM en la regeneración ósea en el cerdo. Estudio

Experimental. *Rev Esp Odontoestomatologia de Implantes* 2001; 9:29-37.

19.- **Fuerst G, Gruber R, Tangl S, Zechner W, Haas R, Mailath G, Sanroman F, Watzek G.** Sinus grafting with autogenous platelet-rich plasma and bovine hydroxyapatite. A histomorphometric study in minipigs. *Clin Oral Implants Res.* 2003; 14:500-8.

20.- **Olsen ML, Aaboe M, Hioting-Hansen E, Hansen AK.** Problems related to an intraoral approach for experimental surgery on minipigs. *Clin. Oral Impl. Res.* 2004; 15:333-8.

Corresponding author:

Dr. José López López
Departament d'Odontoestomatologia
Pavelló de Govern, 2a planta
Despatx 2.29
Av. Feixa Llarga, s/n
08907 L'Hospitalet de Llobregat
Tel. +34.93 402 42 69 / +34 93 402 42 70
Fax +34 93 403 55 58
Email: 18575jll@comb.es