

SUPERNUMERARY MOLARS. A REVIEW OF 53 CASES

V. MENARDÍA-PEJUAN, L. BERINI-AYTÉS, C. GAY-ESCODA*

Department of Oral and Maxillofacial Surgery, Faculty of Dentistry, University of Barcelona, Barcelona, Spain.

* *Member of GIRSO*

KEY WORDS: supernumerary molars, epidemiology, 4th molars.

MOTS CLES: molaires surnuméraires, épidémiologie, 4eme molaires

ABSTRACT

Supernumerary molars are not uncommon and may be found nearly anywhere in the dental alveolar arches. A series of 36 patients that presented with 53 supernumerary molars are reviewed. They occurred more frequently in the maxilla (86.8%), had little or no clinical significance, tended to be impacted, and were not associated with the impaction of the third molar. Four cases of maxillary fifth molars are described.

RESUME

Les molaires surnuméraires ne sont pas rares et peuvent se trouver presque partout sur les arcades alvéolo-dentaires. Les cas de 36 patients avec 53 molaires surnuméraires sont illustrés et discutés. Ces molaires ont été localisées essentiellement sur le maxillaire (86,8%), avec signification clinique faible ou nulle, et tendent à l'inclusion mais ne sont pas associées à la troisième molaire incluse. En outre, 4 cas de 5^e (cinquièmes) molaires maxillaire sont décrits.

INTRODUCTION

Supernumerary teeth are defined as an increase in the normal number of teeth irrespectively of their location and morphologic characteristics (1-3) and excluding the persistence of a deciduous tooth (2). The incidence of supernumerary teeth in the general population varies in different studies, ranging from 0.3% to 3.8% (4-12). They appear more frequently in the permanent than in the deciduous dentition (1-3,8,10,12-14), in males more frequently than in females (2,5,8,10,12,13,15-17) and in the maxilla more frequently than in the mandible (1-4,10,12-14,16-18) with the exception of premolar supernumerary teeth (1,2).

Supernumerary molars are the second most common numerical dental anomaly after the mesiodens (3,4,10,13,14,16,18,19). Bolk (20) classified supernumerary molars as paramolars which are rudimentary teeth located distally to the first molar but outside of the dental arcade, either buccally or lingually, and distomolars which are found distally to the third molar and generally in line with the dental arch.

Paramolars can be fused to one of the normal molars, a condition named 'paramolar tubercles' (2).

The etiology of supernumerary teeth has not been clearly elucidated. Some studies suggest they could be originated in a hyperactivity of the embryonic epithelial cells but there is no agreement in the origin of those cells or the stage of the embryological formation when this supposedly occurs (1,3,16,18,21,22-24). Other authors have proposed that a supernumerary tooth may be the reappearance of an ancestral dental formula (25). Inheritance is also a determinant factor. Although supernumerary teeth may occur isolated in one generation they have a tendency to be inherited (26-30). Stafne (26), in a study of 200 supernumerary teeth found that 90% of them were inheritance-related cases. This is also supported by a higher incidence of supernumerary teeth in patients with craniofacial congenital anomalies, such as cleidocranial dysplasia, cleft lip and palate, Fabry's disease, and Gardner's syndrome (31-36).

In most cases, supernumerary teeth are incidentally diagnosed in asymptomatic patients in the course of an oral radiological examination (10,18,21). This

radiological finding is relevant in order to plan an adequate treatment and to prevent future complications derived from the persistence of this abnormality (17).

We describe the clinical and radiological characteristics of 36 patients in whom a total of 53 supernumerary molars were diagnosed and extracted.

PATIENTS AND METHODS

Between January 1996 and December 1999, a total of 36 patients that presented with 53 supernumerary molars were treated at the Department of Oral and Maxillofacial Surgery of the Faculty of Dentistry, in Barcelona.

In most cases, supernumerary teeth were diagnosed by a radiological study indicated for other reasons since almost all patients were asymptomatic. Treatment consisted of surgical extraction of the supernumerary teeth under local anesthesia associated with removal of the third molar when it was present.

In all cases the following data were recorded: age, gender, clinical presentation, number of supernumerary teeth, site, impaction, relation to the third molar, and presence of fifth molars.

RESULTS

There were 20 men and 16 women aged between 15 and 59 years (mean 28 years) who presented with one (n=24), two (n=8), three (n=3) or four (n=1) supernumerary molars. Bilateral presentations were registered in 11 patients. A fifth molar was found in three patients (in the maxilla in all cases). Forty-nine patients were not associated with symptoms. For the remaining four patients presenting complaints were as follows: odontogenous follicular cysts (confirmed by histopathologic examination). In two patients, odontogenous sinusitis in one, and pain in the retromolar region in one.

Of the 53 supernumerary molars extracted, 46 were found in the upper jaw (right maxilla 27, left maxilla 19) and 7 in the mandible. Intraosseous or submucosal impaction was documented in 50 cases (Figures 1 to 5). According to the criteria of Bolk (20), all supernumerary molars found were distomolars. In 32 cases, supernumerary molars were associated with an erupted third molar (Figure 6).

There were no complications either intraoperatively or postoperatively in relation to supernumerary molar surgical extractions.

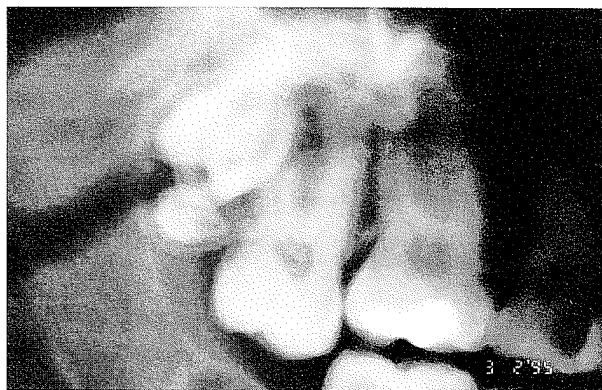

Fig. 1: Maxillary right fourth molar with an impacted third molar.

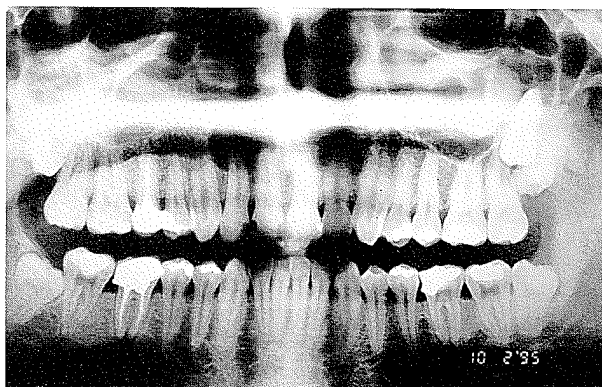


Fig. 2: Bilateral maxillary fourth molars with impacted associated third molars.

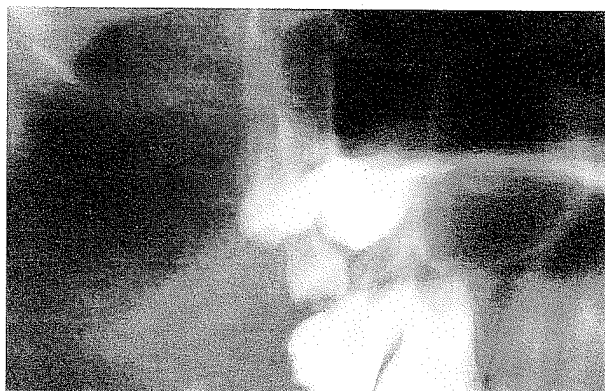

Fig. 3: Impacted third, fourth and fifth maxillary right molars.

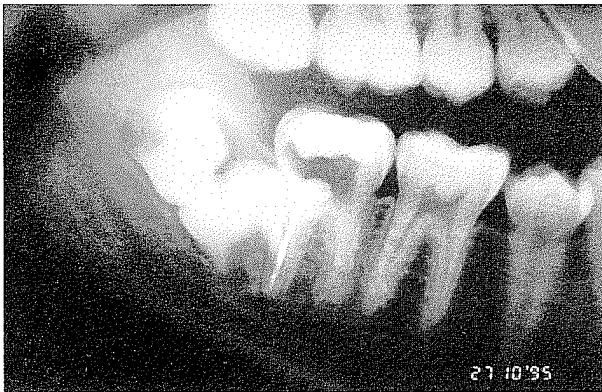


Fig. 4: Mandibular right third and fourth impacted molars.

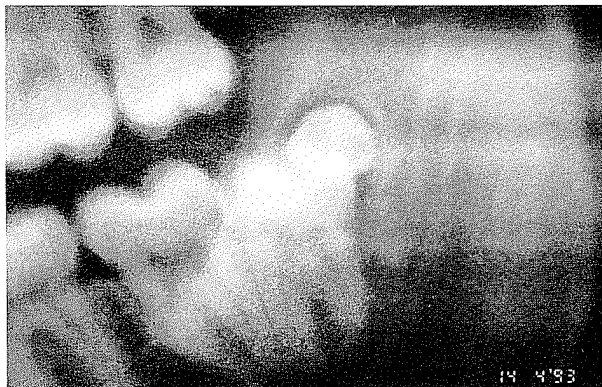


Fig. 5: Mandibular left third and fourth impacted molars.

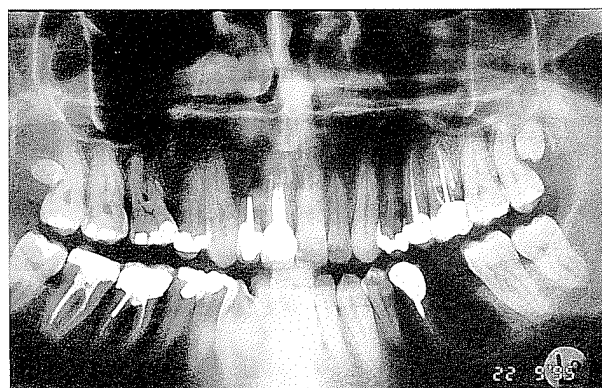


Fig. 6: Bilateral maxillary fourth molars with erupted associated third molars.

DISCUSSION

Supernumerary molars are considered the second most frequent anomaly of teeth number, only after supernumerary central maxillary incisors or mesiodens. We have reviewed 53 supernumerary molars in 36 patients over a 3-year period.

In other series reported in the literature, only 1 to 3% of patients with supernumerary molars presented with three or more supernumerary molars (5,11), which was found in four (11%) of our patients. On the other hand, our incidence of supernumerary molars in the mandible (13%) is higher than figures previously reported (0.9% to 2%) (10). Three patients (8.3%) presented with four supernumerary fifth molars, No reference to this findings has been documented in other series published in the literature.

In agreement with the study of Grimanis et al. (10) and Fleury et al. (21) we also found no significant difference in gender distribution. However, some authors (29,37) reported a higher incidence of supernumerary molars in males, as high as a twofold difference (6,18).

Supernumerary molars are more frequently found in the maxilla, approximately 90% of the cases reported in the literature (16,18,21), and 86,8% in our series. They were found to be impacted in 95% of our cases which is coincidental with the report by Martinez Gonzalez et al. (18). Although in the literature only 70% of the cases reviewed are distal to the third molar (18,27) in our series all cases were found in this location.

In our series, only 40% of the third molars were found to be impacted which is a much lower incidence that what has been previously described (5,7-12). In two cases the supernumerary molars were fused to the third molar.

Diagnosis and location studies of the supernumerary molars can be achieved with panoramic radiographs, periapical films, oblique lateral projections and occlusal films (10,14,16,17,38,39).

Although supernumerary molars are generally asymptomatic in our series four cases presented with symptoms associated with their presence. Pericoronal inflammation and abscesses have already been described (21,40). Several authors have reported cases of supernumerary molars associated with a follicular cyst (16,18,41). Other clinical signs and symptoms that have been reported in relation to supernumerary molars include alterations in the eruption or impactation of adjacent permanent teeth (1,10,16,42,43), malposition of the supernumerary molars or adjacent teeth causing malocclusion (14,44), root resorption (1,10) of permanent teeth and fusion to the third molar (45,46).

Surgical extraction is the treatment of choice (3,6,17).

Only in selected cases where the adjacent teeth have not concluded the apex formation will surgery be delayed (10,16). Care should be taken during the surgical extraction to avoid the displacement of the supernumerary molar to adjacent spaces, such as the infratemporal space in maxillary cases or the lingual space in mandibular cases (42). This could also occur during surgical extraction of an impacted third molar if the supernumerary molar is not properly diagnosed or localized.

REFERENCES

1. **Nadal-Valldaura A.** Estudio de los dientes supernumerarios. *Revista Española de Estomatología* 1967;15:27-46.
2. **Nadal-Valldaura A.** Patología dentaria. *Rondas Ed. Barcelona.* 1987.
3. **Gay Escoda C., Berini L.** Cirugía Bucal. *Madrid, Ed. Ergon,* 1999.
4. **Cabrini R.L.** Anatomía patológica Bucal. *Mundi Ed. Buenos Aires.* 1980.
5. **Lisa L.Y.** Unusual supernumerary teeth. *Angle Orthodontist,* 1990;60:289-92.
6. **Tarello F., Barbero P., Riccomagno G., Mulic P.** Anomalie dentali. Eziopatogenesi e aspetti clinici dell'iperodontia. *Minerva Stomatologica.* 1986;35:277-80.
7. **Molleda Medrano N.** Algunos casos de dientes supernumerarios. *Revista Española de Estomatología* 1956;4:243-8.
8. **Stafne EC.** Supernumerary teeth. *Dent Cosmos* 1932;74:653-9.
9. **Sakari J.** A panoramatomographic study of the teeth and jaws of Finnish university students. *Community Dent Oral Epidemiol* 1993; 21:36-9.
10. **Grimanis G.A., Kyriakides A.T., Spyropoulos N.D.** A survey on supernumerary molars. *Quintessence Int* 1991;22:989-95.
11. **Schulze C.** Incidence of supernumerary teeth. *Dent Abstr* 1961;6:23.
12. **Bodin I., Julin P., Thomsson M.** Hyperodontia. Frequency and distribution of supernumerary teeth among 21609 patients. *Dentomaxillofac Radiol* 1978; 7:15-7.
13. **Archer W.H.** Oral and Maxillofacial Surgery. 5th. ed. WB Saunders. Philadelphia. 1975.
14. **Fleury J.E., Deboets D., Assaad C., Maffre N., Caillot M.** Dents surnuméraires. *Rev Stomatol Chir maxillofac.* 1984;85: 142-50.
15. **Shafer W.G., Hine M.K., Levy B.M.** A textbook of oral pathology. 4th Ed. WB Saunders. Philadelphia. 1983.
16. **Sanders B.** Cirugía Bucal y Maxilofacial Pediátrica. *Mundi Ed. Buenos Aires.* 1984.
17. **Maura I, Flores S.** Esquemas clínico-visuales en patología bucal. *Doyma Ed. Barcelona.* 1987.
18. **Martínez González J.M., Alobera Gracia M.A., Baca Pérez Bryan R., Trobo Muñiz P.** Patología y diagnóstico de los molares supernumerarios. *Avances en Odontoestomatología,* 1992, 8:661-6.
19. **Kaban L.B.** Pediatric oral and maxillofacial surgery. *Wb Saunders.* Philadelphia. 1990.
20. **Bolk L.** Supernumerary teeth in the molar region in man. *Dent Cosmos.* 1914;56:154-67.
21. **Fleury J.E., Deboets D., Assaad C., Maffre N.** Molaires surnuméraires. *Rev Stomatol Chir Maxillofac* 1984;85:136-41.
22. **Chate R.A.C.** Supernumerary molars. *Oral Surg.* 1978;45:857-9.
23. **Fisher S.E.** Maxillary sixth molars. *Br Dent J* 1982;152:356.
24. **Langebartel D.A.** The anatomical primer. Baltimore. University Park Press, 1977.

25. **Gottardi G.** Geminazione dentale. *La Stomatologia* 1927;25:455-59.
26. **Stafne E.C.** Supernumerary upper central incisors. *Dent Cosmos* 1931;73:976-80.
27. **Jensen B.L., Kreiborg S.** Development of the dentition in cleidocranial dysplasia. *J Oral Pathol Med* 1990;19:89-93.
28. **Sedano H.O., Gorlin R.J.** Familial occurrence of mesiodens. *Opt Acta* 1969;27:360-1.
29. **Nislander J.D., Sujaku C.** Congenital anomalies of teeth in Japanese children. *Am J Phys Anthop.* 1963;21:569-74.
30. **Bruning L.J., Dunlap L., Mergele M.E.** Report of supernumerary teeth in Huston, Texas, school children. *J Dent Child* 1957; 24:98-105.
31. **Alling Ch.C., Helfrich J.F., Alling R.D.** Impacted teeth. WB Saunders. Philadelphia. 1993.
32. **Chipps J.E.** Multiple supernumerary teeth in cleidocranial dysostosis. *Oral Surg* 1951;4:25-8.
33. **Kim Seow W.** Dental development and molar root length in children with cleidocranial dysplasia. *Pediatr Dent* 1995;17:101-5.
34. **Regattieri L.R., Parker J.L.** Supernumerary teeth associated with Fabry-Anderson's syndrome. *Oral Surg Oral Med Oral Pathol* 1973;35:432-3.
35. **Miyajima K., Natsume N., Kawai T., Iizuka T.** Oblique facial cleft, Cleft palate, and supernumerary teeth secondary to amniotic bands. *Cleft-Palate Craniofac J* 1994;31:483-6.
36. **Honda M.** Epidemiological investigation of patients with cleft lip and palate in connection between the cleft alveolus and teeth. *J Oral Maxillofac Surg* 1994;40:71-6.
37. **Sugimura M.** Mandibular distomolars. A review of the japanese literature and a report of three additional cases. *Oral Surg* 1975;40:341-5.
38. **Nazif M.M., Ruffalo R.C., Zullo T.** *J Am Dent Assoc* 1983;106:201-4.
39. **Alvarez I., Creath C.J.** Radiographic considerations for supernumerary tooth extraction: Report of case. *J Dent Child* 1995;62:141-4.
40. **Levy H.** Impacted second, third, fourth and fifth molars. *Oral Surg Oral Med Oral Pathol.* 1978;45:489.
41. **Linden W.D., Cleaton-Jones P, Lownie M.** Diseases and lesions associated with third molars. Review of 1001 cases. *Oral Surg Oral Med Oral Pathol Oral Radiol Endod* 1995;79:142-5.
42. **Laskin D., Laskin M.** Cirugía bucal y maxilofacial. Buenos Aires. *Panamericana*, 1987.
43. **Spengos M.N.** Third molar resorption with supernumerary molar. *Oral Surg Oral Med Oral Pathol.* 1972;33:670.
44. **Barnett M.L.** Supernumerary molars. *Oral Surg Oral Med Oral Pathol* 1972;33:486-7.
45. **Ren-Jye Ch., Jia-Fure Y.** Fusion of a third molar with an invaginated supernumerary molar?. *Oral Surg Oral Med Oral Pathol* 1990;70:526-7.
46. **Chen H.S., Huang Y.L.** Fusion of third and fourth mandibular molars? *Oral Surg Oral Med Oral Pathol* 1992; 73:767.

Corresponding Author:

Dr. Cosme Gay-Escoda,
 Professor of Oral and Maxillofacial Surgery,
 Faculty of Dentistry, University of Barcelona,
 Campus de Bellvitge,
 E-08907 L'Hospitalet de Llobregat,
 Barcelona, Spain
 telephone number 34-3-4024274
 facsimile 34-3-4024212
 E-mail: cgay@bell.ub.es