

## SUPERNUMERARY PREMOLARS. REPORT OF 10 CASES

VALMASEDA-CASTELLÓN E., BERINI-AYTÉS L., GAY-ESCODA\* C.

Dental Faculty of the University of Barcelona, Barcelona - Spain.

\* Member of GIRSO

KEY WORDS: *supernumerary premolar, hyperdontia.*

MOTS CLES: *prémolaire supernuméraire, hyperdontie*



### ABSTRACT

Supernumerary premolars are "extra" teeth morphologically belonging to the premolar group. Hyperdontia affecting premolars can be single (when only one supernumerary tooth is found), multiple (if several teeth are involved) or related to a syndrome such as cleidocranial dysplasia. Supernumerary premolars are the third most frequent group of supernumerary teeth, following mesiodens and fourth molars; the prevalence among the general population ranges from 0.09-0.64%.

The present study describes 10 cases of supernumerary premolars treated in our Service of Oral and Maxillofacial Surgery of the Dental Clinic of the University of Barcelona. A late onset was demonstrated in one case, contrasting the present pantomograph with another obtained 5 years before. In only one case did the presence of a supernumerary premolar alter normal tooth eruption. Two supernumerary premolars were affected by follicular cysts.

### RESUME

Les prémolaires supernuméraires son des dents "de plus" du group des prémolaires. L'Hyperdontie qui affecte les prémolaires peut être simple (quand on y trouve seulement une prémolaire supernuméraire), multiple (si on trouve plusieurs supernuméraires) ou associée a un syndrome, tel que la dysplasie ectodermique. Les prémolaires supernuméraires sont le troisième group le plus fréquent de dents supernuméraires, après les mesiodens et les quatrième molaires. La prévalence à la population générale est du 0.09-0.64 %.

Cet travail décrit 10 patients avec des prémolaires supernuméraires traitées au Département de Chirurgie Oral et Maxillo-facial de la Faculté d'Odontologie de l'Université de Barcelone. Dans un cas, la radiologie démontra un développement tardif de la prémolaire, si l'on comparait la radiologie avec une autre qui avait été faite 5 ans auparavant. Seulement dans un cas, la présence d'une prémolaire supernuméraire altéra l'éruption dentaire normale. Deux prémolaires supernuméraires avaient formé des kystes.

### INTRODUCTION

Supernumerary teeth are those which exceed the normal dental formula. They can appear in either temporary or permanent dentition, but are more frequent in the latter (Gay-Escoda C. 1995; Rodríguez-Armijo A. et al. 1996; González J. et al. 1996). In this context, it is important to define the presence of supernumerary teeth by an increase in the number of teeth pertaining to a given dental group, rather than in terms of an increase in the total dental formula, for although a specific dental group can be increased in number, the dental formula

can compensate in the form of agenesis of other groups - a situation that should not confuse the diagnosis (Gay-Escoda C. 1995; Rodríguez-Armijo A. et al. 1996; González J. et al. 1996; Nadal-Valldaura A. 1987). The incidence of supernumerary teeth in the general population ranges from 0.5-3% (Gay-Escoda C. 1995; Rodríguez-Armijo A. et al. 1996), and the condition predominates 2:1 in males over females (Gay-Escoda C. 1995; Rodríguez-Armijo A. et al. 1996; Trull et al. 1994). The most frequent supernumerary tooth is the mesiodens, which is found between the upper central incisors at the midline, and accounts for over 50% of all

supernumerary teeth (Gay-Escoda C. 1995; Rodríguez-Armijo A. et al. 1996; González J. et al. 1996; Nadal-Valldaura A. 1987; Trull J.M. et al. 1994; Contreras M.A. et al. 1995). The second most frequently involved teeth are the upper fourth molars or distomolars, the upper paramolars and the lower premolars (Gay-Escoda C. 1995).

The prevalence of supernumerary premolars in the general population ranges from 0.09-0.64% (Gay-Escoda C. 1995; Rubenstein L.K. et al. 1991; Stafne E.C. 1932), corresponding to 8-9.1% of all supernumerary teeth (Rubenstein L.K. et al. 1991). Unlike other supernumerary dental types, supernumerary premolars are much more frequent in the mandible than in the upper maxilla (Gay-Escoda C. 1995; Rodríguez-Armijo A. et al. 1996; Nadal-Valldaura A. 1987; Rubenstein L.K. et al. 1991; So L.L. 1990; Kocaredelli I. et al. 1994).

## CASE REPORTS

### Case 1

A healthy non symptomatic 17-year-old male had two supernumerary teeth detected in the area of teeth 3.6-3.7 and 4.6-4.7 after pantomography for evaluation of his third molars (Fig. 1). They were eumorphic in shape. His father had also undergone surgery for supernumerary teeth. Both supernumerary teeth were found to be close to the buccal cortical bone. The right supernumerary tooth exhibited a pericoronal radiotransparency, which was suspected to be a follicular cyst. This tooth and the cystic lesion attached to it were surgically removed under local anesthesia, using a Neumann buccal flap. The pathologist diagnosed a follicular cyst. The patient suffered mild hypoesthesia of the inferior dental nerve, which completely subsided in one month. At this time the left supernumerary premolar was also extracted, without postoperative complications.

### Case 2

A 17-year-old male with a history of Petit mal epilepsy until the age of 6 years (currently non symptomatic), and hepatitis B at age 10 years consulted because of two palpable bulges in the lingual cortical bone of the lower jaw. The patient was otherwise non symptomatic. In the panoramic radiograph, two supernumerary premolars were observed, one on each side (Fig. 2). The right tooth was in an unfavorable position, because of its proximity to the mental foramen. The patient was scheduled for follow-up every year. The

left supernumerary premolar was surgically extracted using a lingual approach and a flap without releasing incisions. Postoperative healing was uneventful.

### Case 3

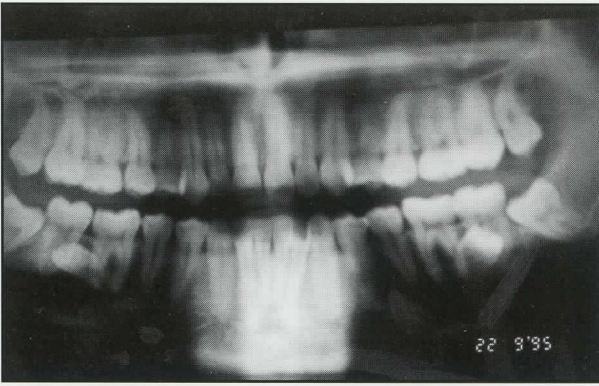
An 18-year-old male with a non contributory medical complaint of left mandibular discomfort and progressive and fast crowding of the lower anterior teeth. At examination, the four third molars were unerupted, and a bulge was palpated in the right mandibular lingual cortical between the cuspid and first premolar, without tenderness to palpation. Two panoramic radiographs had been made. The first was obtained at age 13 (Fig. 3a), while the second was recent (Fig. 3b). The latter showed the inclusion of all third molars, and the presence of a supernumerary premolar impacted between teeth 4.3 and 4.4. In comparison, the first panoramic radiograph showed no evidence of the supernumerary tooth - thus suggesting that it appeared later than the other premolars, which were already erupted at the time. Periapical and occlusal radiography showed the supernumerary tooth to be located on the lingual side. All third molars were extracted, though surgery of the supernumerary premolar was postponed because of its proximity to the mental nerve.

### Case 4

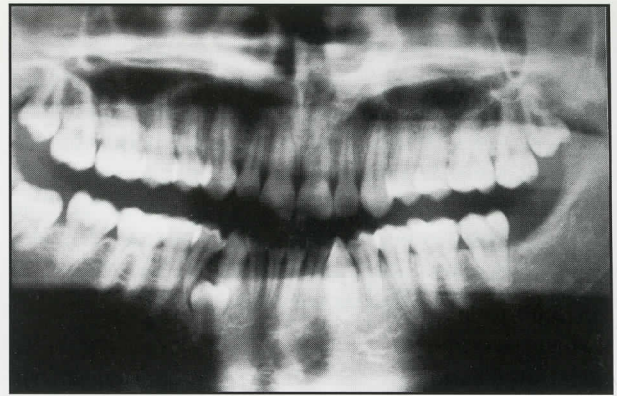
A 21-year-old male with bronchial asthma medically consulted because of a bulge in the lingual cortical bone of the left side of the mandible, between teeth 3.4 and 3.5. There was no tenderness to palpation. Pantomography revealed the presence of a supernumerary premolar between teeth 3.4 and 3.5 (Fig. 4), with upper third molars impaction. The premolar was associated to a radiotransparent lesion and was located very close to the mental foramen. The supernumerary tooth was surgically extracted using a lingual flap without releasing incisions. Postoperative healing was uneventful, and histological examination of the radiotransparent lesion classified it as a follicular cyst.

### Case 5

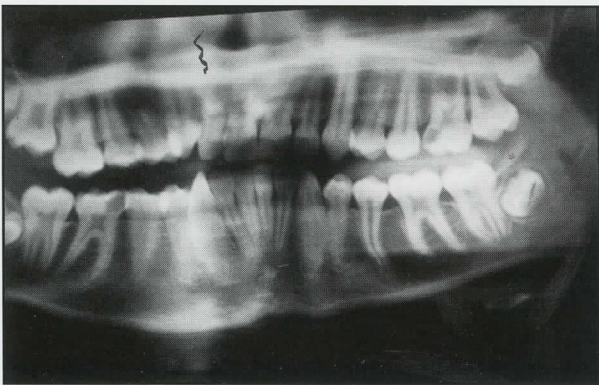
An non symptomatic 15-year-old male with a non contributory medical history consulted because teeth 4.3 and 4.4 had failed to erupt. Pantomography and an intraoral radiograph showed a supernumerary premolar in the right side of the mandible. This tooth had an incomplete root and it was considered responsible of the impaction of tooth 4.4. (Fig. 5). The supernumerary tooth was extracted under local anesthesia, and the postoperative course was uneventful.



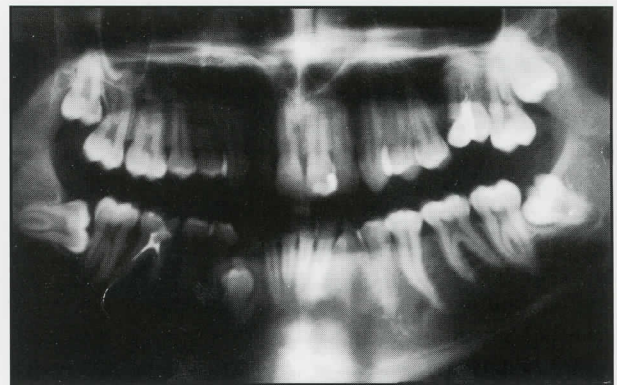
**Fig. 1:** Case no. 1. Panoramic radiograph showing two supernumerary premolars in the lower jaw, between the first and the second lower molars of both sides.



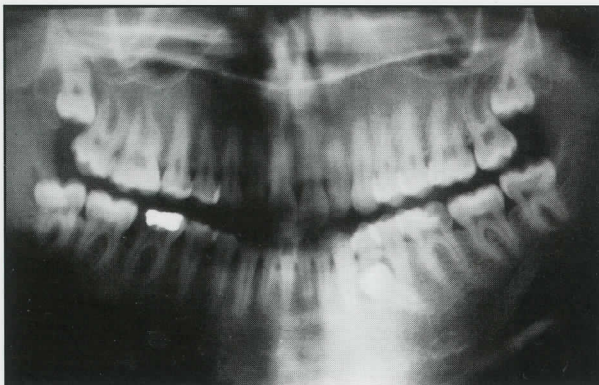
**Fig. 2:** Case no. 2. Panoramic radiograph showing the presence of two supernumerary premolars in the lower jaw, very close to the first lower premolar of both sides.



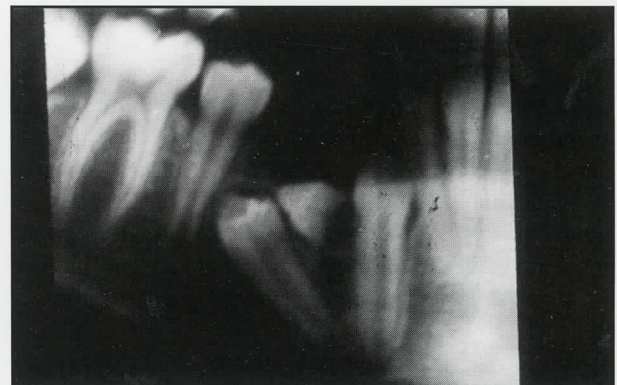**Fig. 3:** Case no. 3. (a) Panoramic radiograph of a 13-year-old patient showing no evidence of supernumerary premolars.



**Fig. 3:** Case no. 3. (b) Panoramic radiograph of the same patient obtained years later and showing an impacted premolar between teeth 4.3 and 4.4.



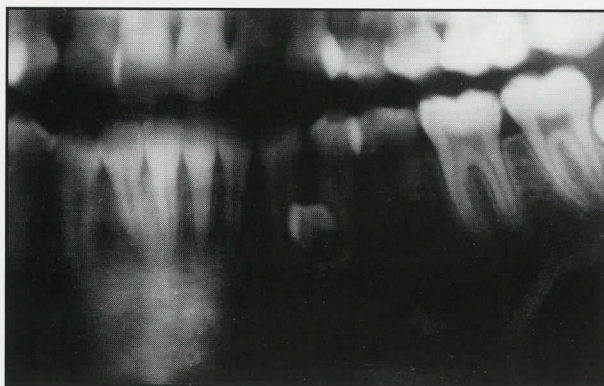
**Fig. 4:** Case no. 4. Panoramic radiograph disclosing a supernumerary premolar between the left lower premolars.



**Fig. 5:** Case no. 5. Part of a panoramic radiograph showing a supernumerary premolar interfering with the eruption of tooth 4.4.

### Case 6

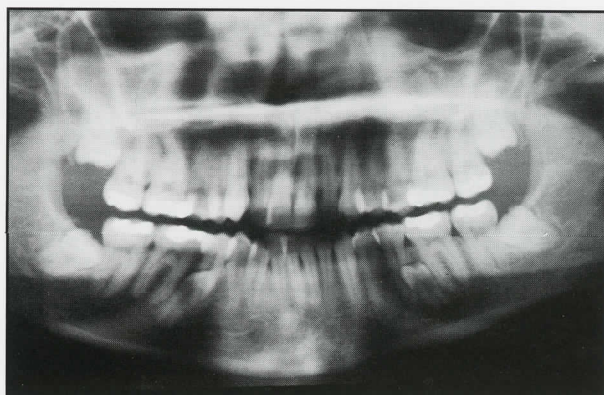An non symptomatic 18-year-old female with a non contributory medical history consulted because of third molars, which had not erupted. All other teeth were present. The panoramic radiograph disclosed a supernumerary premolar with incomplete root formation, between teeth 3.3 and 3.4 (Fig. 6). The supernumerary tooth was surgically extracted under local anesthesia using a buccal Neumann flap, and postoperative healing was uneventful.



**Fig. 6:** Case no. 6. Part of a panoramic radiograph disclosing an impacted supernumerary premolar close to tooth 3.4.

### Case 7

A 22-year-old male with a non contributory medical history was referred to our Service for evaluation of the third molars, which had not erupted. Pantomography showed the presence of all third molars and two supernumerary premolars between teeth 3.5 and 3.6, and 4.5 and 4.6 (Fig. 7). A very close relation was observed between the two supernumerary teeth, the apex of the second premolar and the mandibular canal. All third molars and both supernumerary premolars were extracted under general anesthesia. Postoperative healing was uneventful.



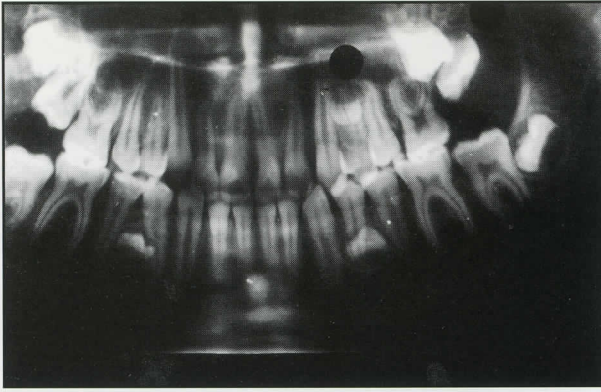
**Fig. 7:** Case no. 7. Panoramic radiograph showing 4 unerupted third molars and two supernumerary lower premolars, distal to teeth 3.5 and 4.5.

### Case 8

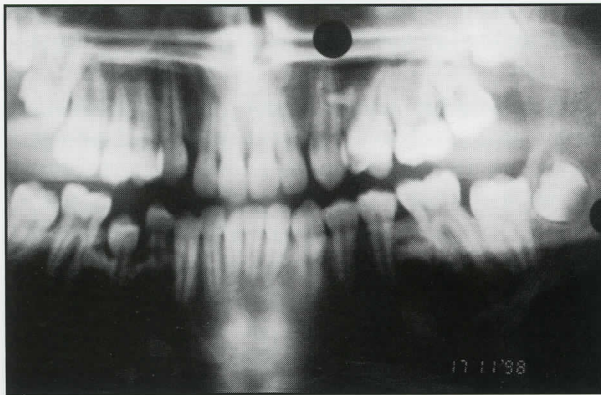
A 26-year-old non symptomatic male with a non contributory medical history consulted for evaluation of the third molars. A panoramic radiograph disclosed the presence of four unerupted third molars, a left fourth lower molar and two supernumerary premolars between teeth 3.5 and 3.6, and 4.5 and 4.6 (Fig. 8). All four third molars, the left fourth lower molar and supernumerary premolars were removed under general anesthesia, and postoperative healing was uneventful.



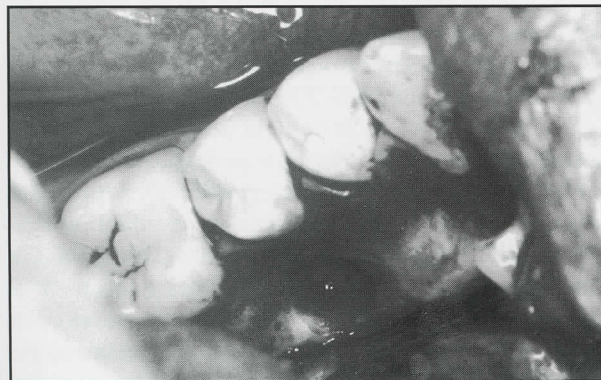**Fig. 8:** Case no. 8. Panoramic radiograph showing four unerupted third molars, a fourth lower molar and two supernumerary lower premolars, distal to teeth 3.5 and 4.5.



**Fig. 9:** Case no. 9. Panoramic radiograph showing the impacted tooth 2.7 and also supernumerary premolars next to tooth 2.4 and between teeth 3.4 and 3.5 and 4.3 and 4.5.



**Fig. 10:** Case no. 10. (a) Panoramic radiograph showing three supernumerary premolars between teeth 4.6 and 4.3, another one between teeth 3.6 and 3.5 and another one between teeth 2.4 and 2.3.



**Fig. 10:** Case no. 10. (b) Socket of the premolar between teeth 4.6 and 4.5 after the surgical extraction.

**Case 9**

A 15 year-old male with a non contributory medical history consulted because his permanent second molars had not erupted yet. The panoramic radiograph showed an impaction of the tooth 2.7. and the presence of two supernumerary premolars between teeth 3.4 and 3.5, and 4.4 and 4.5. An upper supernumerary premolar was located palatally to tooth number 2.4. All supernumerary premolars and the tooth 2.8 were removed under general anesthesia and healing was uneventful.

**Case 10**

A 13 year-old girl complained of crowding in the upper left premolar area. A panoramic radiograph (Figure 10b) disclosed 5 supernumerary premolars, one in the upper jaw and 4 in the lower jaw. All 4 premolars had a palatal position, as disclosed by intraoral radiographs. They were removed under general anesthesia. Figure 10b shows the lingual side of the right mandible after extraction of one of the supernumerary premolars.

**DISCUSSION**

Most multiple supernumerary teeth (69.5%) are located in the premolar area, compared with 8.4% of single supernumerary teeth (Melamed Y. et al. 1994). Of our 10 cases, only patient number 8 had supernumerary teeth in more than one dental series: a fourth molar and two supernumerary premolars between teeth 4.3 and 4.4. Five of the 10 cases had double or multiple supernumerary teeth, while the other 5 exhibited a single supernumerary premolar. In only one case (patient no. 1) were supernumerary premolars not located in the premolar area. All were located in the mandible, in agreement with most cases reported in the dental literature.

The prevalence of supernumerary premolars in the general population is 0.09-0.64% (Stafne E.C. 1932; Rubenstein L.K. et al. 1991; Gay-Escoda C. 1995) 1,7,8, which represents 8-9.1% of all supernumerary teeth 7. Unlike the rest, however, supernumerary premolars are much more frequent in the lower jaw (Nadal-Valldaura A. 1987; So L.L. 1990; Rubenstein L.K. et al. 1991; Kocaderelli I. et al. Gay-Escoda C. 1995; Rodríguez-

Armijo A. et al. 1996). Furthermore Asians and Africans appear to be more frequently affected than Caucasians (So L.L. 1990; Brown A. 1990).

It should always be taken into account that a given subject may develop multiple supernumerary teeth over time. Bryant (1990) reported a patient with a supplementary premolar, followed 30 months later by the presence in the contralateral side of another supernumerary premolar without former evidence of a corresponding dental follicle. In our present series of 10 cases, the comparison of a current panoramic radiograph with another obtained 5 years before in one patient (case no. 3) showed the current supernumerary premolar to be absent in the earlier X-ray image. In this sense, supernumerary premolars may in some cases go unnoticed on X-rays until the normal premolars have erupted.

In morphological terms, supernumerary teeth are usually eumorphic (Brown A. 1990; Pearson M.H. et al. 1990; King N.M. 1993; Breckon J.J. et al. 1993; Rodríguez-Armijo A. 1996), as in our series. A review of the literature showed no supernumerary teeth with conoid, tuberculoid or molariform shapes belonging to the premolar group.

Several theories attempt to explain the pathogenesis of these teeth in terms of the hyperactivity of embryonic epithelial cells, with division of the dental follicle. Some cases can be clearly associated to syndromes involving supernumerary teeth (cleidocranial dysplasia, Gardner's syndrome, etc.)

Supernumerary premolars are usually totally asymptomatic, and constitute chance findings during radiological examinations for other purposes (Rodríguez-Armijo A. et al. 1996). However, in certain cases they can cause local complications, such as cyst formation. Stafne (Stafne E.C. 1932) reported 6% of cases to be associated with follicular cysts, facial pain, rhizolysis, periodontal lesions or eruption delay of permanent teeth (Mitchell L. et al. 1992; González J. et al. 1996; Rodríguez-Armijo A. et al. 1996) - as in case number 5 of the present series.

The eruption of supernumerary premolars is rare (Gay-Escoda C. 1995; Rodríguez-Armijo A. et al. 1996), though Brown (Brown A. 1990) reports a case with 8 supernumerary eumorphic premolars erupted through the palatal and lingual mucosa. None of our 10 patients experienced pain.

As shown by Loh (Loh S. 1989), in some cases unerupted premolars can migrate distally through the mandible below the roots of the lower molars.

During orthodontic treatment, an X-ray is sometimes made to identify the cause of the lack of closure of gaps

between teeth, and supernumerary premolars may be identified at this point (Breckon J.J. et al. 1991) - for they can remain radiographically invisible until eruption of normal premolars (Rubenstein L.K. et al. 1991).

The diagnosis is based on the radiological findings (Rubenstein L.K. et al. 1991; Hattab F.N. et al. 1994) (pantomograph, periapical and occlusal X-rays), though supernumerary premolars can sometimes be palpated during intraoral examination. It should be taken into account that supernumerary premolars can go unnoticed on intraoral X-rays when located very close to the basal cortical bone of the mandible (Rubenstein L.K. et al. 1991). In three of our 10 patients, premolars were readily palpated on the lingual side of the mandible.

Supernumerary premolars are easily diagnosed, for the teeth involved are eumorphic. Were this not the case, a differential diagnosis would be required with other radiopaque lesions such as cementoblastoma, odontoma, osteoblastoma, calcified odontogenic tumor, residual focal osteitis and focal sclerosing osteomyelitis (Stafne E.C. 1932).

Premolars are perhaps among the supernumerary teeth most difficult to extract, due to the high density of the mandibular bone, the presence of the mental nerve on the vestibular side, and the difficulties involved in approaching from the lingual side (Gay-Escoda C. 1995). In this context, a buccal approach is preferred, using a Neumann full-thickness flap. Raising a lingual flap is inconvenient and risky, but often necessary if the supernumerary premolar is closer to the lingual cortical and a buccal approach puts other teeth or the dental nerve at risk.

When a buccal flap is used, the mental nerve must be identified where it crosses the mental foramen, to avoid postoperative sensory lesions. During osteotomy, special caution is required to avoid damaging the neighboring roots, and to preserve the contents of the mandibular canal. Extraction usually requires tooth section before extraction with elevators. The technique employed in the upper maxilla is similar.

Routine follow-up instead of extraction is also a possibility, though it requires periodic radiographic evaluation of the tooth, to detect possible cyst formation or root resorption. After formation of the third molars, supernumerary premolar extraction may be indicated; in this sense, care is required to ascertain that no other supernumerary premolars can arise following extraction of those that have been identified, as this would require repeat surgery.

## REFERENCES

- BRECKON J.J., JONES S.P.** - Late forming supernumeraries in the mandibular premolar region. *Br J Orthod* 20, 375, 1993.
- BRECKON J.J., JONES S.P.** - Late forming supernumeraries in the mandibular premolar region. *Br J Orthod* 18, 329-331, 1991.
- BROWN A.** - Supplemental and congenitally absent premolar teeth (Letter). *Br Dent J* 169, 150, 1990.
- BRYANT D.G.** - Supplemental and congenitally absent premolar teeth (Letter). *Br Dent J* 169, 190, 1990.
- CONTRERAS M., ALAEJOS E., BUENECHEA R., BERINI L., GAY-ESCODA C.** - Mesiodens molariformes: a propósito de un caso. *Anales de Odontología* 3, 103-105, 1995.
- GAY-ESCODA C.** - Temas de Cirugía Bucal. Volume II. 2nd Edition. Barcelona: Signo, 1995, 864-910.
- GONZÁLEZ J., VARELA M.P., RIVAS P., PAZ F., GONZÁLEZ M.C., PÉREZ M.** - Diente supernumerario con persistencia de central temporal y definitivo. *Rev Eur Odontología* 8, 93-96, 1996.
- HATTAB F.N., YASSIN O.M., RAMASHDEH M.A.** - Supernumerary teeth. Report of three cases and review of the literature. *J Dent Child* 61, 382-393, 1994.
- KING N.M.** - Multiple supernumerary premolars: their occurrence in three patients. *Aust Dent J* 38, 11-16, 1993.
- KOCADERELLI I., CIGER S., CAKIRER B.** - Late-forming supernumeraries in the premolar regions. *J Clin Orthod* 28, 143-144, 1994.
- LOH S.** - Migration of unerupted mandibular premolars. *Br Dent J* 164, 324-5, 1989.
- MELAMED Y., BARKAI G., FRYDMAN M.** - Multiple supernumerary teeth and Ehlers-Danlos syndrome: a case report. *J Oral Pathol Med* 23, 88-91, 1994.
- MITCHELL L., BENNETT T.G.** - Supernumerary teeth causing delayed eruption. A retrospective study. *Br J Orthod* 19, 41-46, 1992.
- NADAL-VALLDAURA A.** - Patología dentaria. Barcelona: Rondas, 1987; 60-63.
- PEARSON M.H., WILLIAMS M.D.** - Supplemental and congenitally absent premolar teeth. *Br Dent J* 169, 8, 1990.
- RODRÍGUEZ-ARMIJO A., ROMERO M.J., INFANTE P., RODRÍGUEZ-ARMIJO L., GALLARDO P.A.** - Premolares múltiples supernumerarios no sindrómicos: revisión de la literatura y presentación de un caso. *Archivos de Odontología* 12, 266-270, 1996.
- RUBENSTEIN L.K., LINDAUER S.J., ISAACSON R.J., GERMANE N.** - Development of supernumerary premolars in an orthodontic population. *Oral Surg Oral Med Oral Pathol* 71, 392-395, 1991.
- SO L.L.** - Unusual supernumerary teeth. *Angle Orthod* 60, 289-292, 1990.
- STAFNE E.C.** - Supernumerary teeth. *Dent Cosmos* 74, 653-659, 1932.
- TRULL J.M., BANCHILLERÍA E., VALLLLOSERÀ J., GAY-ESCODA C.** - Supernumerarios múltiples no sindrómicos: descripción de un caso. *Avances en Odontología* 10, 89-93, 1994.

**Corresponding Author:**

*Prof. Dr. Cosme Gay Escoda.*  
 Section of Oral and Maxillofacial Surgery  
 (Master of Oral Surgery and Implantology)  
 University of Barcelona Dental School  
 C/ Feixa Llarga s/n, Campus de Bellvitge  
 Pavelló Central, 2<sup>a</sup> planta  
 08907 - L'Hospitalet de Llobregat (Barcelona)  
 Spain  
 E-mail: [cgay@bell.ub.es](mailto:cgay@bell.ub.es)  
 Web page: [www.gayescoda.com](http://www.gayescoda.com).